



Original Full Paper

# Preliminary binary ethylenimine (BEI) inactivated bovine papillomavirus (BPV) vaccine trial against cutaneous warts in bull calves: a pathological assessment

Kanchan Pangty<sup>1</sup>, Shweta Singh<sup>2</sup>, Awadh B. Pandey<sup>3</sup>, Ramesh Somvanshi<sup>4</sup>

<sup>1</sup>M.V. Sc. scholar, Indian Veterinary Research Institute

<sup>2</sup>Research Associate, Indian Veterinary Research Institute

<sup>3</sup>Principal Scientist, CADRAD, Indian Veterinary Research Institute

<sup>4</sup>Professor and Head, Division of Pathology, Indian Veterinary Research Institute

Corresponding author: R. Somvanshi, Indian Veterinary Research Institute, Division of Pathology, Izatnagar, UP, 243 122 India E-mail: [somvanshi@ivri.up.nic.in](mailto:somvanshi@ivri.up.nic.in)

Submitted June 20<sup>th</sup> 2010, Accepted September 4<sup>th</sup> 2010

## Abstract

A preliminary prophylactic and therapeutic vaccine trial was successfully conducted in bull calves with binary ethylenimine (BEI) inactivated saponized crude cutaneous warts bovine papillomavirus 1 and 2 (CW BPV-1 & -2) vaccine. In Prophylactic Group of vaccinated animals no temperature, untoward reaction or nodule formation was seen at vaccine inoculation site. After challenge with BPV inoculum, cutaneous warts (CWs) failed to develop in this group indicating that vaccine was effective. In Therapeutic Group, before vaccination in two animals CWs were experimentally induced. In one animal, luxuriant cauliflower-like and in other linear slow growth was observed. After vaccination, CWs in both animals became dried and growth was arrested. It appeared that tumours were regressing which was confirmed by further clinical observations as very little tumour-scar was left at termination of experiment. Histopathologically, both cases were diagnosed as regressing occult/ early fibroblastic type papilloma. Mononuclear cellular infiltration/ aggregates around hair follicles and in tumour stroma were noted. As compared to first case (cauliflower-like/ fast growing) in second case (linear growth/ fast regressing), in addition to other findings mononuclear cellular inflammatory reaction were more pronounced. The clinical regression results are in accordance with histopathological findings of degree of infiltration of lymphocytes and this trial showed that both type use of BEI inactivated saponized crude CW BPV-1&-2 vaccine gave encouraging results with fast regression/ prevention of CWs.

**Key Words:** BEI, BPV vaccine, cutaneous warts, calves, histopathological assessment.

## Introduction

One of the major goals of papillomavirus research is the development of vaccines which should either prevent viral infection (*prophylactic vaccines*) or accelerate rejection of papillomas (*therapeutic vaccines*) thus leading to a decreased incidence of cutaneous warts (CWs) in which bovine papillomavirus (BPV) infection plays a pivotal role. Autogenous wart vaccines are known to give good results and cure clinical cases. Commercial wart vaccines have been tried with favorable results in cattle. It was reported that when commercial vaccine is used, the response to vaccine therapy is slow and not found to be uniform in all animals, but better response is obtained by the use

of autogenous wart vaccine (8). Noice and Eveleth, quoted by earlier worker (8) have also reported success with the use of a similar vaccine in cows. It has been reported that the efficacy of wart vaccine is uncertain when lesions are very extensive and the CW is of long duration. The growths, however showed a tendency to crack, and they become slightly grayish in colour after the fourth injection.

In India also successful trials of autogenous vaccine made on wart affected calves in the Sindhi breed herd stationed at the District Livestock Farm, Trichur was conducted (4). Vaccines from infective wart material in buffered glycerol with penicillin and streptomycin or in bovine serum and saline merthiolate were prepared (9). In 120 Friesian and 4 buffalo calves,

2 subcutaneous injection of either vaccine inoculated 17 days apart produced recovery rate of 84% but merthiolate gave better results.

Autogenous wart vaccine has been successfully used in sessile and pedunculated warts in cattle (1, 25). It activates the immune system of the body and prevents further occurrence of the malady. Herd specific inactivated vaccine was also used (13). Earlier workers triturated wart tissue with physiological saline and inactivated the virus with formaldehyde and added antibiotics-like crystalline penicillin and streptomycin. Vaccine was injected on neck at alternate site subcutaneously. Regression of warts was observed after 4-6 weeks and on 14-16 weeks only traces were there. Individual bovine specific and species specific autogenous vaccine was used and complete regression was observed after 2-4 months only in those from which vaccine prepared (15). This was due to presence of antigenic variants immunologically distinct from parent virus.

Formalin treated sterile homogenizatum made from tumours removed from skin of animals for the treatment and prevention of CWs (24). Comparative studies on efficacy of different vaccination method in treatment of CWs were also conducted (6). These were autogenous, species specific and herd specific vaccination method. Autogenous and herd specific vaccination showed earlier recovery. It was reported that autogenous vaccine treatment was more effective in case of young animals and those with pedunculated warts (18). Prophylactic vaccination of calves as early as 4-6 weeks might be necessary to prevent infection.

All above observations of different types of autogenous vaccines were based on clinical features only and even pathology of regressing warts were not assessed. The type of BPVs present in vaccine was also not known. The vaccine with adjuvant can provide better curative and preventive effects. Binary ethylenimine (BEI) is used as inactivant in vaccines and saponin as adjuvant with encouraging results (17).

Therefore, in present preliminary study, a BEI inactivated saponized BPV-1 & -2 vaccine trial in bull calves was conducted with objective to develop a safe vaccine against CWs for farm and field use in India and elsewhere.

## Materials and methods

### *Infection Inoculum*

Cutaneous warts were sampled from different organized dairy farms of UP and Uttarakhand. The samples were preserved in -20 °C for further use. Histopathologically, confirmed CWs (fibropapilloma) samples were cleaned, washed, minced with sharp scissors and thoroughly triturated in sterilized pestle and mortar. A 10% homogenized suspension was prepared using PBS (pH 7.2). The homogenized suspension was subjected to three cycles of freezing and thawing and centrifuged at 12,000 rpm for one

hour. The supernatant was then filtered through a 0.45 µm syringe filter. Antibiotics were added and stored at -20°C till further use.

### *PCR Tes*

BPV-1 & -2 was identified in CWs samples used for vaccine preparation by PCR as described earlier (16).

### *Experimental Infection*

Multiple infections were given by scarification after weekly intervals. First of all hairs were clipped with help of a scissors and approximately 8-10 cm area at neck was shaved. With help of a curved needle, scarification was done and then with a sterilized swab virus was applied at superficially wounded surface. In this way infection was repeated thrice at 3 days interval.

### *Vaccine Preparation*

CW vaccine was prepared by adding the BEI as inactivant in the 10% CW suspension. For this, CW suspension and BEI solutions were mixed in the ratio of 10:1 (10 CW: 1 BEI). The inactivation mixture was kept at 37°C for 36-48 hrs and then reaction was stopped by adding 1 M sodium thio sulphate.

### *Saponification of vaccine*

Saponin was prepared as a stock solution of 100mg/ml in PBS and sterilized by filtration. Stock solution was added to a final concentration of 1mg/ml of inactivated virus suspension and mixed well for 30 minutes. The crude vaccine was stored at 4°C until use.

### *BEI Inactivant*

2 M BEI was prepared by dissolving 2.049 g of BEI in 50 mL 0.2 N NaOH. After this, mixture was kept at 37° C. Initially the pH was 12-13 when it became 8, solution was stored at 4°C.

### *Design of experiment*

A total of 7 young cross bred bull calves were used in this study for testing crude and inactivated CW vaccine. Design of experiment is given in Table-1.

### *Vaccination*

Vaccine was given to each animal of Therapeutic and Prophylactic groups as per experimental plan (Table-1) by subcutaneous route on neck region/adjoining to infection/CW site. First dose was 2 mL and it was increased 1mL at subsequent intervals- day 3 (3mL), 5 (4mL), 7 (5mL) and 9 (6mL). Total dose of vaccine was 20 mL.

Table 1. Design of experiment of vaccination trial in bull calves.

Groups (Gr.)	No. of animals	Treatment/Vaccination	Remarks
Positive Control (PC Gr.)	2	Infection with CW crude extract	Multiple scarification
Therapeutic (T Gr.)	2	Vaccination after infection	Multiple subcutaneous injection
Prophylactic (P Gr.)	2	Vaccination before infection	Multiple subcutaneous injection
Control (C Gr.)	1	No treatment	-

#### Challenge

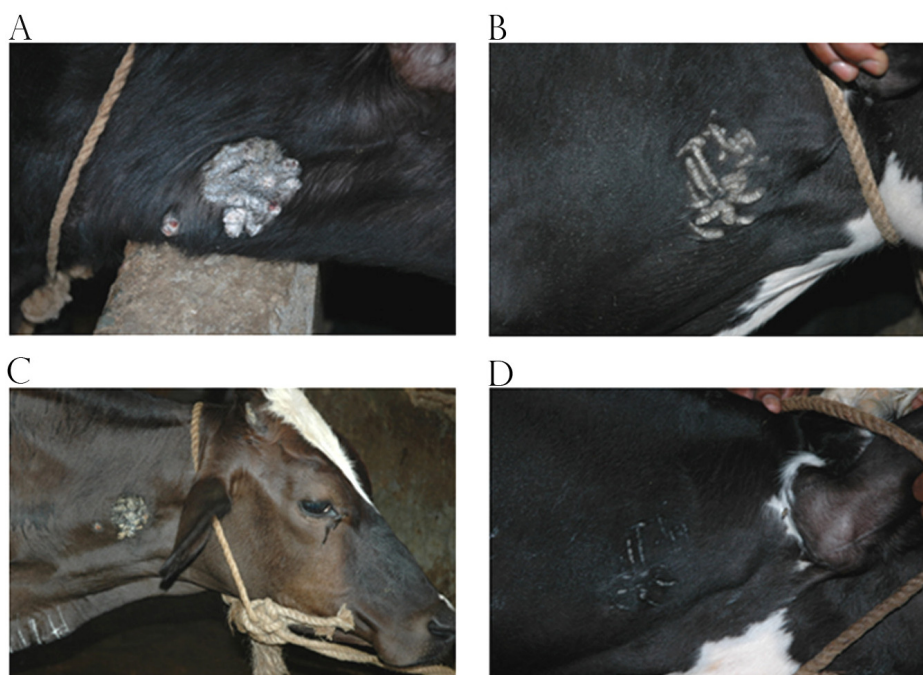
It was done by same method as above in Prophylactic group of animals.

**Pathological studies:** CWs were removed surgically under local anaesthesia by qualified veterinarians and biopsies were fixed in 10 % formalin for histopathological studies. After proper fixation, tumours were cut into small sections with thickness of 2-3 mm, processed in ascending grades of alcohol for dehydration and cleared in benzene. The paraffin embedded tissues were cut into 4-5 micron thick section and stained with H & E (7).

#### Results and discussion

Commercial CWs vaccines are available and if used, it may help in prevention of warts in cattle, if not previously infected. Autogenous vaccines are prepared from chemically treated warts taken from animals in a herd. In fact, the autogenous vaccine is more apt to have the strain or type of PV causing the

wart problem in a herd than some of the commercial vaccines. CWs are not uncommon in Indian cattle and buffaloes (10, 19, 20, 21, 23). No suitable commercial vaccine is available for field use. Preliminary prophylactic and therapeutic BEI inactivated saponized vaccine trial in bull calves was conducted with aim to develop a safe and long acting vaccine against CWs for farm and field use in cattle. Out of four animals infected with crude extract of CW, two animals developed CWs after 6 weeks post infection. In Prophylactic Gr. of vaccinated animals, no temperature, untoward reaction or nodule formation was seen at vaccine inoculation sites. After challenge with BPV inoculum, CWs failed to develop in this group. In Therapeutic Gr., after vaccination CWs in both animals dried and further growth was arrested. It appeared that tumours were regressing which was confirmed by further clinical observations as very little tumour scar was left at termination of experiment (Plate-1 A, B, C & D).

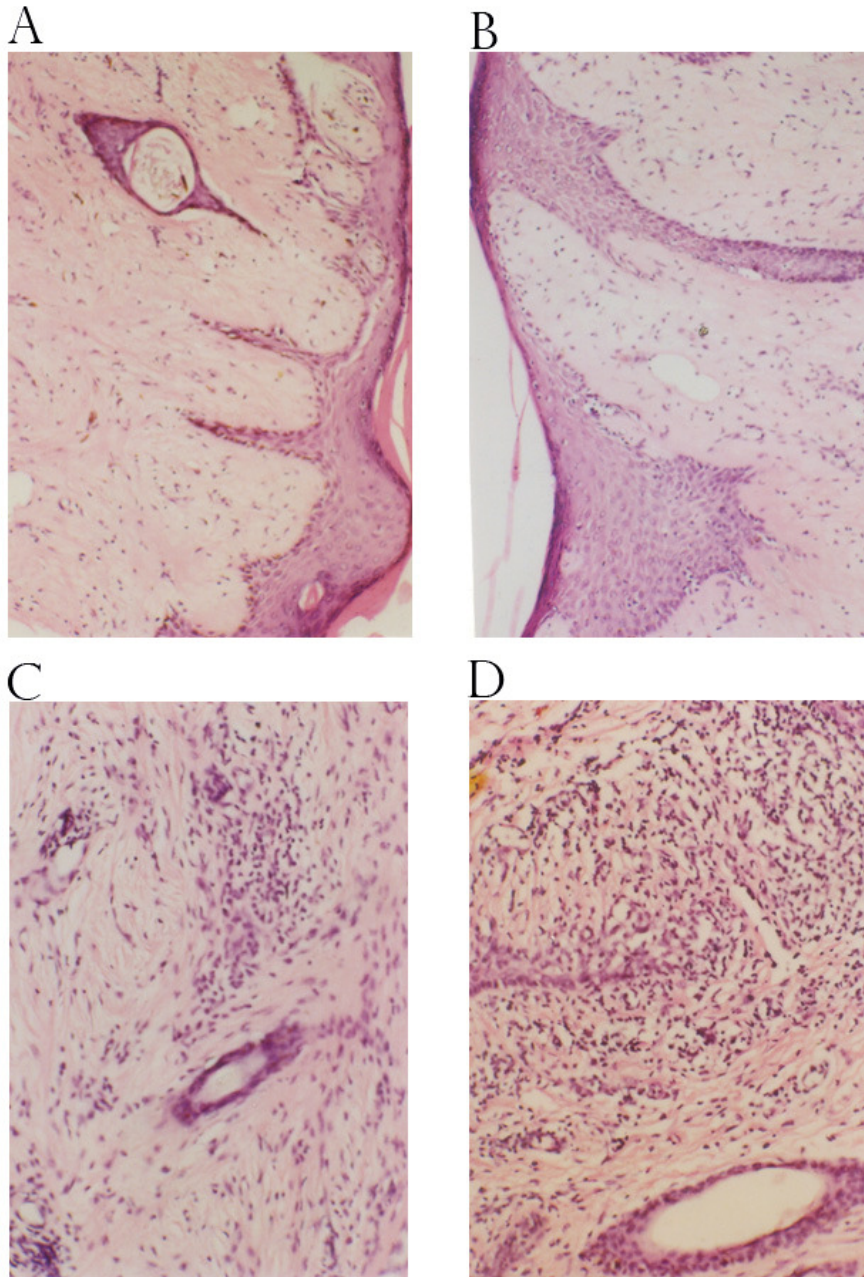


#### Plate-1

- Experimentally induced fast growing cauliflower-like light brownish growth in bull calf. Before therapeutic vaccination.
- Experimentally induced slow growing linear light brownish growth in bull calf. Before therapeutic vaccination.
- Experimentally induced slow regressing cauliflower-like growth in bull calf. Post therapeutic vaccination.
- Experimentally induced fast regressing linear growth in bull calf. Post therapeutic vaccination.

Histopathologically, in first case (cauliflower-like/ fast growing) after 30 days vaccination prominent skin adenaxae, thin epidermis, rete pegs and transparent tumour stroma with less collagen were changes noted. Mononuclear cellular infiltration / aggregates around hair follicles and in tumour stroma

were seen. In second case (linear growth / fast regressing), in addition to above the mononuclear cells inflammatory reactions were more pronounced causing rapid regression of tumour. (Plate-2 A, B, C & D). It appeared that regression of tumour was related with mononuclear cellular infiltration in tumour stroma.



**Plate-2**

- A. Thinning of epidermis, elongated rete pegs and transparent tumour stroma. Occult / early fibroblastic type papilloma (cauliflower-like). H&E X100.
- B. Thinning / focal hyperplasia of epidermis, elongated rete pegs and transparent tumour stroma. Occult / early fibroblastic type papilloma (linear). H&E X 100.
- C. Mild mononuclear cellular infiltration. Occult / early fibroblastic type papilloma (cauliflower-like). H&E X 150.
- D. Pronounced mononuclear cellular infiltration. Occult / early fibroblastic type papilloma (linear). H&E X 150.

The findings of experimentally induced CWs are in accordance with previous workers who tried autogenous vaccines. Trial of autogenous vaccine made on wart affected calves conducted revealed that the younger calf, which showed sign of improvement after the second injection, the growths became brittle and began to drop away. By the thirtieth day after the first injection all the growths had disappeared. These changes suggested favorable response to the vaccine therapy and further indicated that in case not far advanced, autogenous wart vaccine gives quick and complete cure (4). Autogenous vaccine treatment was reported to be more effective in case of young animals and those with pedunculated warts (18). Prophylactic vaccination of calves as early as 4-6 weeks might be necessary to prevent infection.

The earlier vaccines were without adjuvant and conventionally treated chemicals and observations were based only on clinical trials and were not supported by histopathological studies. In present study histopathologically, these tumours showed thin epidermis, rete pegs, transparent tumour stroma and marked infiltration of mononuclear cells and it was diagnosed as occult early fibroblastic papilloma. Due to short period available for tumour development and failure of collagen deposition, aforementioned changes were seen. In present study in spontaneous cases also such three cases of occult fibroblastic papilloma were diagnosed which may be reflecting similar phenomenon. However, in those cases collagen deposit was more and mononuclear cellular infiltration was not seen. In regressing cases of CWs, mononuclear cell infiltration was one of important finding (21, 22). Over all observations showed that both type use of vaccine gave encouraging results with fast regression/prevention of CWs.

CWs may regress spontaneously during any stage of development (5, 12). Multiple bovine warts usually regress in an individual animal simultaneously, but this occurs later than the development of resistance to re-infection with BPV (12). Regressing fibromas were found to be infiltrated with mononuclear leucocytes, mainly lymphocytes both in perivascular areas and as a diffuse scattering throughout the tumor. The intensity of infiltration was found proportional to the rate of fibroma regression (11). In animals with both fibromas and fibropapillomas, the fibroma will regress whereas the fibropapillomas will continue to grow and not regress until much later. This is correlated with a lack of leucocytes infiltration in the persisting fibropapillomas. The presence of precipitating antibodies does not protect against re-infection unless the warts have undergone resolution. However, a small percentage of animals whose fibromas have regressed were still susceptible to re-infection, but the resultant lesions undergo early regression. Treatment of CW with wart vaccines is difficult to evaluate since the disease is self limiting and of varying duration in animals. Earlier workers observed that infiltration of CD4 was more than CD8 in a regressing papilloma in cattle affected with warts (2). The vaccinated calves produce high titer of

antibodies directed to three immunodominant B-cell epitopes (3) and developed a strong cellular immune response to two T-cell epitopes (14).

It was reported that the Bontebok National Park, South Africa obtained a higher therapeutic rate on the treatment of equine sarcoids after using their autogenous vaccine than the Gariep Dam Nature Reserve which had several cases that did not respond to the vaccine (26). Using real-time PCR it was shown that the Bontebok National Park's vaccine contained both BPV-1 and -2 whereas the Gariep Dam Nature Reserve's vaccine had only BPV-1 DNA. It was speculated that the zebras which did not respond to vaccination might have been infected with BPV-2 and that the vaccine did not cross-protect between BPV-1 and -2. Therefore, authors (26) suggested that CW vaccine should contain both type of viruses. Since Indian cattle herds are known to contain mixed type of infection of BPV-1 and -2 (16) as such in present vaccine also both type of viruses were incorporated and encouraging results were obtained.

To sum up the findings of present studies, it may be stated that preliminary prophylactic and therapeutic studies in BEI inactivated saponized BPV - 1 & -2 vaccine in bull calves were successfully conducted. The clinical regression results are in accordance with histopathological findings of degree of infiltration of lymphocytes.

## References

1. BLOOD DC., RADOSTITS OM. *Veterinary Medicine*, Seventh Edition. London: ELBS and Bailliere Tindall, 1989.
2. CAMPO MS. Bovine papillomavirus: Old System New Lessons? In: *Papillomavirus Research: From Natural History to Vaccine and Beyond*. Chap 23. England: Caister Academic Press, 2006.
3. CHANDRACHUD LM., O'NEIL BW, JARRETT WHF, GRINDLAY GJ, MCGARVIE GM, CAMPO MS. Humoral immune response to the E7 protein of bovine papillomavirus type 4 and identification of B-cell epitopes. *Virology*, 1994, 200, 98-104.
4. CHANDRAN SR. Autogenous wart vaccine. *Indian Vet. J.*, 1961, 68, 152-5.
5. CHEVILLE NF., OLSON C. Epithelial and fibroblastic proliferation in bovine cutaneous papillomatosis. *Pathol. Vet.*, 1964, 1, 248-57.
6. CIMTAY I., KESKIN O, BABA ZF. Comparative studies on efficacy of different vaccination method in treatment of Bovine Papillomatosis. *Turk Vet. Hayvancilik Dergisi*, 2004, 27, 929-33.
7. CULLING CFA. Hand book of Histologic techniques. Second Ed., London: Butterworths & Co., 1995.
8. FOSS CD. 1959. Autogenous vaccine. *Vet. Med.*, 54, cited by Chandran, SR. (1961).
9. GHAFER S., ISMAIL A, SHEBL A. Bovine cutaneous papillomatosis: Vaccination trial and serological studies. *J. Egyptian Vet. Med. Assoc.*, 1979, 35, 27-41.

10. LEISHANGTHEM GD., SOMVANSHI R, TIWARI AK. Detection of bovine papillomaviruses in cutaneous warts/papillomas in cattle. *Indian J. Vet. Pathol.*, 2008, 32,15-20.
11. LIU-ZHIAGO, LIU Y, HONG Y, RAPP L, ANDROPHY E, CHEN JJ. Bovine Papilloma Virus type-1 E6-induced sensitization to apoptosis is distinct from its transforming activity. *Virology*, 2002, 295, 230-37.
12. LOE KP., OLO C. Histochemical study of experimentally produced bovine fibropapillomas. *J. Invest. Dermatol.*, 1969, 52,454-64.
13. MAKAY B., Results from use of a herd-specific inactivated vaccine against Bovine Papillomatosis. *Magyar Allatorvosk Lapja*. 1990, 44, 231-32.
14. MC GARVIE GM., GRINDLAY GJ, CHANDRACHUD LM, O'NEIL BW, JARRETT WFH, CAMPO MS. T-cell responses to BPV-4 E7 in vaccinated and non vaccinated cattle during the course of BPV-4 infection and identification of T-cell epitopes. *Virology*, 1995, 206, 504-10.
15. NDORATHI CM., MBUTHIA PG. Individual bovine specific and species specific autogenous vaccine. *Indian J. Anim. Sci.*, 1994, 64, 218-21.
16. PANGTY K. Molecular diagnosis of bovine papillomatosis/ enzootic bovine haematuria and assessment of BPV hamster tumour model for immunoprophylaxis / antitumour therapeutics. MVMSc Thesis, Vety. Pathology. Deemed University, IVRI, Izatnagar, UP, 2009.
17. RAMAKRISHNAN MA., PANDEY AB, SINGH K. P, SINGH R, NANDI S, MEHROTRA ML. Immune responses and protective efficacy of binary ethylenimine (BEI)-inactivated bluetongue virus vaccines in sheep. *Vet. Res. Commun.*, 2006, 30, 873-80.
18. SANTIN, API., BRIFO, LAB. Estudo da papillomatosis cutanea em bovinos Leiteiros. *A Horo Vet.*, 23, 2004, 29-33.
19. SINGH V. Etiopathological studies on Bovine Papillomatosis and Enzootic Bovine Haematuria with special reference to combined effects of BPV and fern in hamsters. MVMSc. Thesis, Vety. Pathology, Deemed University, IVRI, Izatnagar, UP. 2007.
20. SINGH V., SOMVANSHI R, TIWARI AK. Papillomatosis in Indian cattle: Occurrence and etiopathology. *Indian J. Vet. Pathol.* 2009, 33 52-7.
21. SOMVANSHI R., KOUL GL, BISWAS JC. Clinicopathological observations on bovine cutaneous papillomas. *Indian J. Anim. Sci.*, 1986, 56, 836-40.
22. SOMVANSHI R., SHARMA B, KOUL GL, BISWAS JC, YADAV MP. The delayed cutaneous hypersensitivity and humoral immune response in spontaneous bovine papillomas. *Indian Vet. Med. J.*, 1988, 12, 7-14.
23. SOMVANSHI R., SINGH V, HAJRA S. Bovine Papillomatosis with particular reference to Enzootic Bovine Haematuria. In: *Diagnosis and prophylaxis of economically important diseases of farm animals and poultry*. SOMVANSHI R, Ed. Izatnagar, UP: Pub. Division of Pathology, IVRI, 2009:198-230.
24. SUVEGES T, SCHMIDT J. Newer data on the occurrence in Hungary of losses caused by and ways of control of bovine papillomatosis. *Magyar Allatorvosok Labya*, 2003,125, 83-7.
25. THEILER GH, MADEWELL BR. *Veterinary Cancer Medicine*, Philadelphia: Lea and Febiger, 1979.
26. VAN DYK E, OOSTHUIZEN MC, BOSMAN AM, NEL, PJ, ZIMMERMAN, D VENTER EH. Detection of bovine papillomavirus DNA in sarcoid-affected and healthy free-roaming zebra (*Equus zebra*) populations in South Africa. *J. Virol. Meth.*, 2009, 158,141-151.