BJVP
Brazilian Journal of Veterinary Pathology
ISSN 1983-0246

Case report

Malignant insulinoma in a crab-eating fox (*Cerdocyon thous*)

Marcelo C. C. Malta[1], Marcela M. Luppi[1], Raquel G. Oliveira[2], Ingeborg M. Langohr[3], Roselene Ecco[2], and Renato L. Santos[2]*

[1]Fundação Zoo-Botânica de Belo Horizonte, Belo Horizonte, MG, Brazil.;
[2]Departamento de Clínica e Cirurgia Veterinárias, Escola de Veterinária, Universidade Federal de Minas Gerais, Belo Horizonte, MG, Brazil.; [3]Department of Comparative Pathobiology, Purdue University, West Lafayette, IN, USA.
***Corresponding author**: Departamento de Clínica e Cirurgia Veterinárias, Escola de Veterinária, Universidade Federal de Minas Gerais, Av. Antônio Carlos, 6627, 31270-901 Belo Horizonte, MG, Brazil. Phone: 55-31-3409-2239; fax: 55-31-3409-2230 (Email: rsantos@vet.ufmg.br).

Submitted December 13th 2007, Accepted March 3rd 2008

Abstract

This report describes a case of insulin-secreting pancreatic beta cell carcinoma in a crab-eating fox (*Cerdocyon thous*). The animal died approximately 60 days after the first clinical signs. At necropsy, a nodule (2 x 3 cm) was observed in the pancreas. Microscopic features were consistent with a pancreatic islet cell carcinoma. By immunohistochemistry, neoplastic cells were strongly positive for insulin and synaptophysin while negative for glucagon. These results supported the diagnosis of insulinoma, which to the best of our knowledge is the first documented case of this tumor in a crab-eating fox.

Keywords: *Cerdocyon thous*, crab-eating fox, insulinoma.

Insulinomas are insulin-secreting pancreatic adenomas or carcinomas derived from beta cells. These tumors are the most common tumors arising from the pancreatic islets (1). This neoplasia is often associated with hyperinsulinism and hypoglycemia, and a large proportion is malignant (7, 11).

Insulinomas occur most frequently in dogs (2, 5, 7, 11) and ferrets, less frequently in cattle, and rarely in cats (1, 12). Middle-aged or older, large-breed dogs have a higher risk of developing these tumors, while both sexes are equally affected (1, 7, 11). Younger dogs usually have a shorter survival time than older dogs, and the maximum survival period is approximately 3 years (2, 5), which is influenced by post surgical medical therapy (9). The occurrence of insulinoma in wild canids has been rarely documented with one single report of insulinoma in a red fox (Vulpes vulpes) arising from an ectopic pancreas (6).

This report describes a case of insulinoma in a female adult (more than 10 years of age) crab-eating fox (*Cerdocyon thous*) kept in captivity at the Fundação Zoo-Botânica (Belo Horizonte, MG, Brazil). In October of 2005, the animal had apathy, distended abdomen, and splenomegaly. A nodule of approximately 2 cm in diameter was detected in the gastric region by abdominal palpation. During the first clinical examination, CBC values were within normal range, blood glucose was 88 mg/dl, alkaline phosphatase was 111 U/L, and urinalysis revealed leucocytes and triple phosphate crystals. One month later the clinical condition worsened, with proteinuria, anemia, and leucopenia. The animal died approximately 60 days after the first clinical examination.

Grossly, the animal had poor body condition and pale mucous membranes. The most significant finding was a large predominantly tan nodule (2 x 1 cm) at the pancreas, which was solid and lobulated (Fig. 1). In addition, the animal had mild pulmonary edema, splenomegaly, enlargement of mesenteric lymph nodes, and petechial hemorrhages in the mucosa of the stomach and urinary bladder. Histologically, the pancreatic nodule consisted of a locally invasive, partially encapsulated and well demarcated epithelial neoplasm. The neoplastic cells were arranged in cords supported by delicate septa of fibrovascular stroma (Fig. 2). Occasional

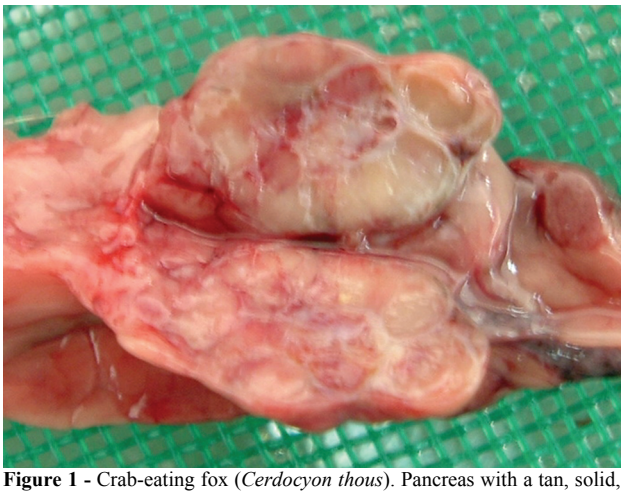

Figure 1 - Crab-eating fox (*Cerdocyon thous*). Pancreas with a tan, solid, and multilobulated nodule of approximately 1 x 2 cm.

islands of remaining exocrine pancreatic acini and ducts were observed between the neoplastic tissue. The neoplastic cells were predominantly polygonal, with mild pleomorphism and low mitotic index (less than one mitotic figure per high power field). There was invasion of lymphatic vessels by neoplastic cells in the pancreas, and most of the lymphoid tissue in the cortex and paracortex of the peri-pancreatic lymph node was replaced by neoplastic tissue with morphological features similar to that observed within the pancreatic nodule. The morphological diagnosis was pancreatic Islet cell carcinoma. Several other organs were examined, and a mild hepatic hemosiderosis, mild lymphocytic interstitial nephritis, pulmonary anthracosis, and splenic hemosiderosis associated with extramedullary hematopoiesis were observed. There were no lesions in the heart, small and large intestine, and uterus.

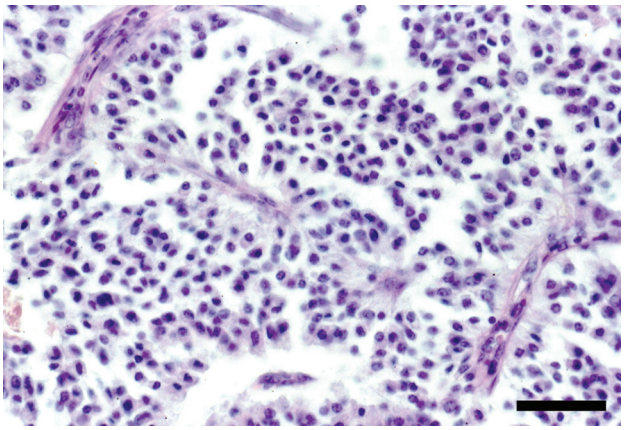

Figure 2 - Crab-eating fox (*Cerdocyon thous*). Pancreas with neoplastic cells arranged in cords supported by delicate fibrovascular stroma, with mild pleomorphism, and a neuroendocrine pattern consistent with a pancreatic islet cell tumor. HE. Bar = 50 µm.

Islet cell tumors are most commonly derived from insulin-secreting beta cells, although non-beta cell tumors may also occur. The later may result in secretion of gastrin, secretin, glucagon, somatostatin, or vasoactive intestinal peptide (1). Therefore, this neoplasia was further characterized by immunohistochemistry, which was done at the Animal Disease Diagnostic Laboratory (Purdue University, West Lafayette, IN). The panel used in this case is described in Table 1, and a commercially available streptavidin-peroxidase complex (LSAB kit, Dako USA) was employed as detection system. Neoplastic cells were strongly positive for the pan-endocrine marker synaptophysin and for insulin (Fig 3), but negative for glucagon. Therefore, a diagnosis of insulinoma was confirmed.

Antigen (clone)	Antibody	Dilution	Antigen retrieval	Source (code)
Insulin (Z006)	M, mouse	200	CT	Zymed (18-0066)
Glucagon	P, rabbit	200	CT	Dako (A0562)
Synaptophysin (SP11)	M, rabbit	160	NT	LabVision (RM-91111)

Table 1 - Antibodies and protocol used for immunohistochemistry.* M = monoclonal from mouse; P = polyclonal; CT = dekloaker citrate pH 6.0 buffer, 10 minutes; NT = no treatment; EDTA = dekloaker EDTA pH 9.0 buffer, 10 minutes; and PK = proteinase K.

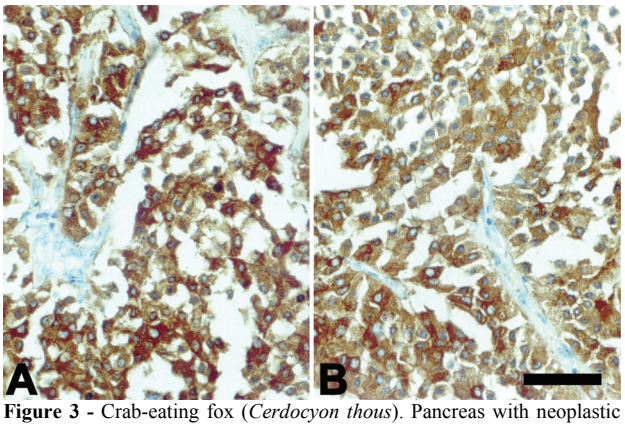

Figure 3 - Crab-eating fox (*Cerdocyon thous*). Pancreas with neoplastic cells that are strongly and diffusely positive for synaptophysin (A) and insulin (B). Streptavidin-biotin-peroxidase immunostaining. Bar = 50 µm.

As observed in the present case, insulinomas usually appear as a solitary nodule (84% solitary and 16 % multiple) (2), ranging from 1 to 3 cm in diameter (3). The frequency of malignant beta cell tumors tends to be higher than that of benign neoplasms, with metastasis occurring in approximately 50% of the cases (11). When present, metastases in dogs are most commonly found in regional lymph nodes and in the liver (2).

Due to the lack of appropriate reference values for crab-eating foxes, results of laboratory tests in this case were compared to reference values for the domestic dog.

Based on this, the glucose level measured during the first clinical exam was considered normal. This did not prompt the inclusion of insulinoma in the clinical differential diagnosis thus, insulin concentration was not determined. Hypoglycemia associated with hyperinsulinism is the most important parameter for the clinical diagnosis of insulinoma (5, 7). It is noteworthy that hyperglycemia by itself is not sufficient for a diagnosis of insulinoma since it may also be associated with several types of non pancreatic tumors (8). The insulin/glucose and glucose/insulin ratios have been used as a diagnostic tool in dogs suspected of having an insulinoma, with a good predictive accuracy for this kind of tumor (7). Clinically, episodes of hypoglycemia are more common in periods of fasting, stress or exercises, manifesting as muscular tremors, muscular weakness, ataxia, confusion, stupor, seizures, and coma (2, 3, 5), which are associated with hypoglycemic lesions in the brain (10). These clinical changes are highly responsive to glucose (5). The diagnosis is based on clinical sings and the levels of insulin and glucose (4). Importantly, other neoplastic diseases such as hepatocellular carcinoma, hepatic leiomyosarcoma and hemangiosarcoma, splenic hemangiosarcoma, diffuse metastatic melanoma, and salivary gland adenocarcinoma, may also result in hypoglycemia (8) so hyperinsulinism is the key finding to support a clinical diagnosis of insulinoma (7). Treatment consists of surgical excision of the neoplasm (2) when possible or medical therapy with diazoxide or corticosteroids to control hypoglycemia in dogs with widespread metastasis (7, 9). Pancreatitis has been described as a common post operative complication associated with this tumor (5).

To the best of our knowledge there is only one previous report of insulinoma in a wild canid affecting a red fox (*Vulpes vulpes*). This is the first documented case in a crab-eating fox (*Cerdocyon thous*). The scarcity of reports may suggest that the incidence of insulinomas in wild canids is lower than that observed in domestic dogs or it may be related to the reduced number of necropsies or biopsy specimens evaluated in wild species.

Acknowledgements

RLS is supported by CNPq (Conselho Nacional de Desenvolvimento Científico e Tecnológico, Brasília, Brazil).

References

1. CAPEN CC. (2002). Tumors of the endocrine glands. Meuten, DJ. Ed., Tumors in domestic animals, 4th ed, Ames: Iowa State Press: 607-96, 2002.
2. CAYWOOD DD., KLAUSNER JS., O`LEARY TP., WITHOROW SJ., RICHARDSON RC., HARVEY HJ., NORRIS AM., HENDERSON RA., JOHNSTON SD. Pancreatic insulin-secreting neoplasms: clinical, diagnostic, and prognostic features in 73 dogs. J. Am. Anim. Hosp. Assoc. 1988, 24, 577-84.
3. COX D. Pancreatic insulin-secreting neoplasm (insulinoma) in a West Highland white terrier. Can. Vet. J., 1999, 40, 343-5.
4. DUNN JK., HEATH MF., HERRTAGE ME., JACKSON KF., WALKER MJ. Diagnosis of insulinoma in the dog: a study of 11 cases. J. Small Anim. Pract., 1992, 33, 514-20.
5. DUNN JK., BOSTOCK DE., HERRTAGE ME., JACKSON KF., WALKER MJ. Insulin-secreting tumours of the canine pancreas: clinical and pathological features of 11 cases. J. Small Anim. Pract., 1993, 34, 325-31.
6. ELVESTAD K., HENRIQUES UV., KROUSTRUP JP. Insulin-producing islet cell tumor in an ectopic pancreas of a red fox (Vulpes vulpes). J. Wildl. Dis., 1984, 20, 70-2.
7. LEIFER CE., PETERSON ME., MATUS RE. Insulin-secreting tumor: diagnosis and medical and surgical management in 55 dogs. J. Am. Vet. Med. Assoc., 1986, 188, 60-4.
8. LEIFER CE., PETERSON ME., MATUS RE., PATNAIK AK. Hypoglycemia associated with nonislet cell tumor in 13 dogs. J. Am. Vet. Med. Assoc., 1985, 186, 53-5.
9. POLTON GA., WHITE RN., BREARLEY MJ., EASTWOOD JM. Improved survival in a retrospective cohort of 28 dogs with insulinoma. J. Small Anim. Pract., 2007, 48, 151-6.
10. SHIMADA A., MORITA T., IKEDA N., TORII S., HARUNA, A. (2000). Hypoglycaemic brain lesions in a dog with insulinoma. J. Comp. Pathol., 2000, 122, 67-71.
11. TRIFONIDOU MA., KIRPENSTEIJN J., BOBBEN JH. A retrospective evaluation of 51 dogs with insulinoma. Vet. Quarterly, 1998, 20, S114-S116.
12. WEISS CA., WILLIAMS BH., SCOTT, MV. Insulinoma in the ferret: clinical findings and treatment comparison of 66 cases. J. Am. Anim. Hosp. Assoc., 1998, 34, 471-5.