



Case Report

Rhinosporidiosis in a dog from Uruguay and review of the literature

Claudio Borteiro^{1,2*}, Javier Etcheverze³, Natalia de León³, Carina Nieto², Mailén Arleo⁴, Claudio Martínez Debat⁴, Francisco Kolenc¹, Martín Ubilla⁵, Jorge Freire⁶, Fernando Dutra⁷

¹Museo Nacional de Historia Natural, 25 de Mayo 582, Montevideo 11000, Uruguay.

²Clínica Veterinaria del Cerro, Camino Cibils 4303, Montevideo 12800, Uruguay.

³Veterinaria La Huella, José Pedro Ramírez 244, Rocha, Uruguay.

⁴Sección Bioquímica, Facultad de Ciencias, Iguá s/n, Montevideo, Uruguay.

⁵Departamento de Evolución de Cuencas, Facultad de Ciencias, Iguá s/n, Montevideo, Uruguay.

⁶Laboratorio Laclivet, Talchahuano 3333, Montevideo, Uruguay.

⁷División de Laboratorios Veterinarios 'Miguel C. Rubino', Avelino Miranda 2045, Treinta y Tres 33000, Uruguay.

*Corresponding author: E-mail: borteiro@gmail.com

Submitted Feb, 6nd 2018, Accepted June, 22nd 2018

Abstract

We report a case of nasal rhinosporidiosis in a dog native to Uruguay, being the sixth report of *Rhinosporidium seeberi* infection in this host from South America. Diagnosis was made by histopathology of biopsied tissue and specific PCR assay from nasal swab material. The patient was a 3-year-old male dog, of the Dogo Argentino breed, living in a rural area in southeastern Uruguay. An account of published cases in dogs worldwide is provided. As seen in other hosts, male dogs seem to present a predisposition for acquiring the disease.

Key words: canine, nasal granuloma, *Rhinosporidium seeberi*, Dermocystida.

Introduction

Rhinosporidiosis is a granulomatous disease caused by the fungus-like ichthyosporean parasite *Rhinosporidium seeberi* (Dermocystida, Ichthyosporidia), which is worldwide distributed in temperate and tropical regions (3). The infection it produces is usually non-lethal and affects mainly mucous membranes, mostly nares, and occurs more frequently in humans and livestock, and only rarely in domestic dogs, cats and birds (4, 16, 25, 30). The disease seems to be associated to the contact with running and stagnant ground waters, both in humans and animals (3). Polypoid granulomatous masses are typical gross lesions of rhinosporidiosis in mucous membranes, but they may resemble several other infective and non-infective diseases (3). The definitive diagnosis has been traditionally confirmed by histopathology, being characteristic the finding of several sporangia of around 300 µm, with

endospores at different degrees of development (15). No drugs have been proved to be broadly effective against *R. seeberi*, and surgical ablation of the granulomas is the treatment of choice (3).

The first diagnosis of nasal rhinosporidiosis in dogs was made in Argentina, South America (19). The disease was later reported from North America (27), and more recently the first cases from Europe were communicated by Caniatti et al. (4). These last authors also provided an account of other nine published reports of rhinosporidiosis in dogs, which include an additional one from Argentina, one from Canada, and seven more from USA. In this work we report a new case of infection by *R. seeberi* in a dog from South America, the first diagnosed in Uruguay, along with an update of the available information in these hosts.

Case report

A 3-year-old dog, male, Dogo Argentino breed, was presented to the authors (JE, NL) in a private clinic in June 2017, with a seven-month history of sneezing. A noticeable reddish, non-bleeding mass protruded from the left nose. The lesion did not seem to be painful but occluded the nasal passage. Sneezing was present, along with scarce nasal discharge and almost no bleeding. At clinical examination, the patient looked otherwise healthy. The dog always lived in a rural area from southeastern Uruguay, in the outskirts of the city of Rocha, Departamento de Rocha, and was frequently used for hunting wild boars in wetlands. The owners allowed partial surgical removal of the granuloma, using electro scalpel, but without opening the anterior nares for further excision of affected tissue. The obtained biopsy was processed for routine histopathological examination, embedded in paraffin, sectioned at 5 µm, and stained with haematoxylin and eosin (H&E). The histopathological analysis revealed severe hyperplastic and lymphoplasmocytic rhinitis, with the presence of multiple fungal-like sporangia characteristic of *R. seeberi* (Fig. 1). The dog returned for clinical examination two months later, and the lesion recurred; sneezing was frequent, but no bleeding or signs of exercise intolerance were observed. At this time, swabbing of the nasal passage mucosa was made with a polyvinyl tipped swab (Puritan®), from the external opening of the nare up to the visible portion of the lesion. The DNA from the swab was extracted using a commercial kit (QIAGEN®) to attempt amplification of the 18S gene with Ichthyosporean specific primers following Feldman et al. (8). Amplicons were sequenced in both senses at Macrogen Inc. (Seoul), and a 1206 pb fragment was obtained. We searched for similar sequences in the GenBank database (BLAST/Nucleotide BLAST/Standard Nucleotide BLAST/megablast), and found 100% identity with a previously published sequences of *R. seeberi* obtained from mammal hosts (10, 26). Recurrence was observed, and a partial removal of the granuloma was made when sneezing got worse, about four months after the first surgery (Fig. 2), and also eight months later in May 2018. During this 2-year follow-up period, the patient was in good condition, and with no other clinical signs of disease.

Discussion

Rhinosporidiosis in dogs seems to be an uncommon disease of the upper respiratory tract, as only 33 cases have been published worldwide, including the present one (Table 1). In all of these cases the disease affected one nasal cavity, and the most remarkable symptoms were nasal discharge (almost invariably), usually sneezing, and less frequently snoring. The nasal discharge could be mucoid, but it is most commonly mucopurulent or haemorrhagic. Sneezing varied from

intermittent episodes to paroxysmal crisis, sometimes being more severe during exercise. It is worth noticing that previously known cases of rhinosporidiosis in dogs from South America were diagnosed in endemic areas of northeastern Argentina (19), Colombia (18) and coastal Brazil (2). However, no cases of dog infection have been reported from hyperendemic areas of Sri Lanka and India, from where most human cases are known and nasal rhinosporidiosis is common in livestock (28). These differences may be related to the life cycle of *R. seeberi* host-specific strains (26), or yet unidentified environmental constraints for parasite-host interactions.

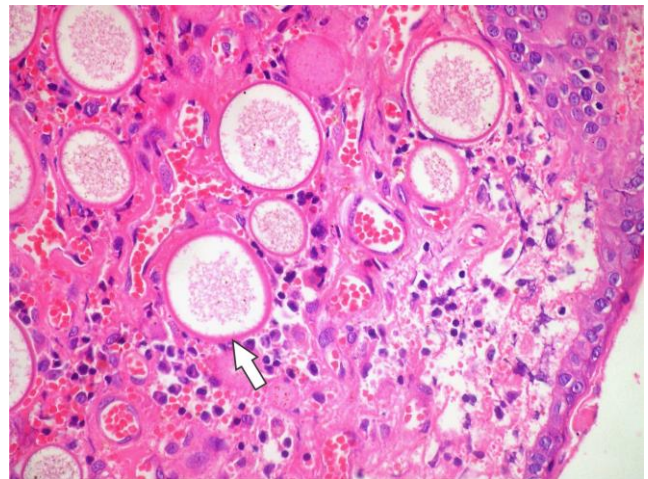


Figure 1. Rhinosporidial granuloma in the nasal mucosa of a dog (H&E, 400X). Sporangia of *Rhinosporidium seeberi* at different maturation stages can be seen (arrow), surrounded by numerous macrophages and newly formed blood vessels.

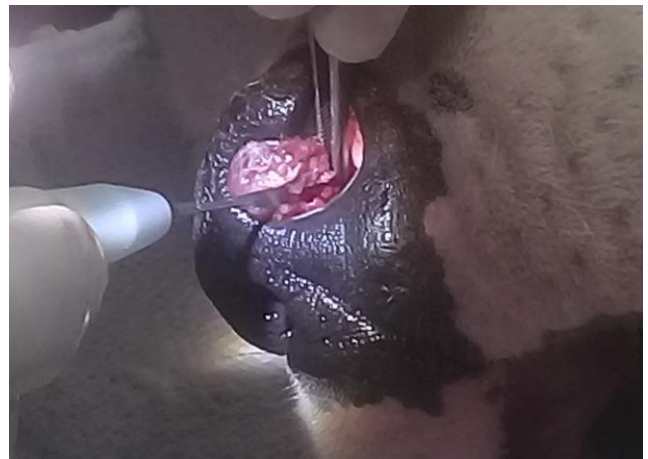

Figure 2. Recurrent rhinosporidiosis in the left nose of a dog, palliative surgical removal four months after first surgery.

Canine clinical rhinosporidiosis seems to be sex biased, as there are 20 known cases in male dogs and only 9 in females. A comparable situation was seen in human case series studies, which suggest males are more likely to

be affected than females, as the occupational exposure of men to infective forms in soil and water is an important predisposing factor (3). A skewed sex ratio in dogs may also indicate that some yet unknown sex related factors may be involved. However, available sample size is still small for this assumption, and sex predisposition in dogs needs further study. The prognosis of rhinosporidiosis in dogs is benign, but recurrence after surgery is quite

common. Medical treatment in dogs includes the use of dapsone (1), cefpodoxime proxetil (11) and ketoconazole (20), combined with surgery. However, they correspond to a few clinical trials with no long-term follow-up to allow conclusions. Apart from dogs, cats are the only domestic carnivores occasionally reported as hosts of *R. seeberi* (22, 30). Rarity of the disease in the domestic cat is probably due to their avoidance of ground water bodies.

Table 1. Published reports of dog rhinosporidiosis in chronological order. Abbreviations: F, female, LNC, left nasal cavity; M, male; ND, nasal discharge; NR, not recorded, RNC, right nasal cavity; SF, sterilized female; SM, sterilized male; UI, unilateral infection.

Country (locality/region)	Cases	Host, sex, age, location, symptoms, habitat	Disease duration, therapy and follow-up	Reference
Argentina (Resistencia)	1	Mongrel, M, 8 yr., RNC, sneezing & ND, semi-rural	8 mo., NR, NR	19
USA (Louisiana)	1	Walker hound, M, old, UI, snoring & ND, NR	NR	27
USA (Texas)	4	NR	NR, surgery, no recurrence	12
Argentina (La Plata)	1	Mongrel, M, 8 yr., RNC, sneezing & ND, NR	4 mo., surgery, recurred in 1 yr., reoperated 2 yr. later with no recurrence in 1 yr.	5
USA (Oklahoma)	1	Coonhound, F, 4 yr., RNC, sneezing, NR	6-8 mo., surgery, recurred in 5 mo.	23
USA (Mississippi)	2	Labrador retriever, M, 2 yr., LNC, sneezing & ND, NR; Golden retriever, SF, 6 yr., LNC, upper stertors, NR. Both exercised outdoors.	2 mo., surgery, recurred in 2 mo. Dapsone for 4 mo., no clinical signs for 7 mo.; 2 weeks, no recurrence in 9 mo.	1
USA (Alabama, North Carolina)	6	Rhodesian ridgeback, M, 2 yr., UI, sneezing, NR; Mongrel, M, 5 yr., UI, sneezing, NR; Walker hound, M, 4 yr., UI, sneezing & ND, NR; English setter, F, 2 yr., UI, NR; Siberian husky, M, 2 yr., UI, NR; Siberian husky, M, 3 yr., UI, sneezing & ND, NR. Four had contact with ground water.	NR, Surgery, NR	7
USA (Mississippi)	1	Doberman, M, 6 yr., LNC, sneezing & ND, NR	14 mo., 4 surgeries every approximately 4 mo.	9
Canada (Ontario)	1	Doberman, SF, 1.5 yr., LNC, sneezing & ND, NR	>1 mo., NR	13
USA (Arkansas)	1	Collie, NR, 1 yr., RNC, sneezing, farm	NR, no treatment	14
Colombia (Manizales; Bogotá)	2	German shepherd, F, NR, RNC, NR; Irish Setter, M, NR, RNC, NR	NR	18
USA (Tennessee)	2	German shepherd, F, 7 yr., LNC, sneezing & ND, NR; Labrador retriever, M, 3 yr., LNC, sneezing & ND, NR	NR, no treatment, symptoms for 2 yr.; 3 weeks, NR	31
Italy	4	English setter, M, 13 yr., RNC; Deutsche brake, M, 11 yr., RNC; Setter, F, 7 yr., LNC; Brie shepherd, F, 2 yr., LNC. All with sneezing & ND, and exposed to rice fields.	4 mo., NR, NR, 2 mo., surgery, no recurrence in 2 yr.	4
USA (Oklahoma)	1	Labrador retriever, M, 8 yr., LNC, sneezing & ND, NR	2 mo., surgery, no recurrence in 1 yr.	20
UK (Meyserside)	1	Shih-tzu, M, 14 mo., LNC, sneezing, semirural	Recent, surgery, recurred in 2 mo., ketoconazole	21
USA (Minneapolis; Wisconsin)	2	Labrador retriever, M, 4 yr., LNC, sneezing & ND, lived near lakes and ponds; Doberman, SM, 7 yr., LNC, sneezing & ND, lived in marshy area	5-6 weeks, cefpodoxime proxetil, surgery, no recurrence for 21 mo.; 4.5 mo., surgery, no recurrence in 14 mo.	11
Brazil (Espírito Santo)	1	Mongrel, M, 3 yr., RNC, sneezing & ND, rural area, bath in river	5 mo., surgery, NR	24
Uruguay (Rocha)	1	Dogo Argentino, M, 3 yr., LNC, sneezing & ND, farm, bath in ponds	7 mo., surgery (palliative)	Present work

The diagnosis of rhinosporidiosis has been usually based on histopathology of biopsied material. However, other techniques may be accurate indicators of the presence of *R. seeberi* and may aid the clinician, like smears of polypoid masses (20). Besides, specific PCR from nasal swabs as in our study case (eventually along with sequencing) would also allow the confirmation of rhinosporidial disease, being minimally invasive.

The present report is one of the few known native cases of rhinosporidiosis in Uruguay, as local information available to us concerning this disease corresponds mostly to old diagnoses, made on two human patients (6, 17), four horses (32), and one bovine (29). The incidence of the disease is probably underscored in the country, as it seems to be endemic in many neighboring areas of eastern Argentina and southern Brazil.

Acknowledgements

We acknowledge the family Fontes Acuña from Rocha and their dog “Tequila”, for their kind collaboration with our study. Alejandra Lasso and Rosina Vilaró (Biblioteca, Facultad de Veterinaria, Montevideo) helped with the bibliographic search. The authors acknowledge ANI/SNI, Uruguay.

References

1. Allison N, Willard MD, Betnick-Smith J, Davis K. Nasal rhinosporidiosis in two dogs. *J Am Vet Med Assoc.* 1986;188(8):869-71.
2. Almeida FA, Feitoza LM, Pinho JD, de Mello GCF, Lages JS, Silva FF, da Silva RR, Silva GEB. Rhinosporidiosis: the largest case series in Brazil. *Rev Soc Bras Med Trop.* 2016;49(4):473-76.
3. Arseculeratne SN, Mendoza L. *Rhinosporidium seeberi*. In: Borrielo SP, Murray PR, Funke G, editors. *Topley and Wilson's Microbiology and Microbial Infections.* 10th Edition. London: Hodder Arnold; 2007.
4. Caniatti M, Roccabianca P, Scanziani E, Finazzi M, Mortellaro CM, Romussi S, Mandelliet G. Nasal rhinosporidiosis in dogs: four cases from Europe and a review of the literature. *Vet Rec.* 1998;1428(13):334-8.
5. Castellano MC, Idiart JR, Martin AA. Rhinosporidiosis in a dog. *Vet Med (Small Anim Clin).* 1984;79:45-6.
6. Domínguez CM, Selinke H. Plasmocitoma de O'Kinelay y Seeber de las fosas nasales. *An Fac Med (Montevideo).* 1948;33:1200-7.
7. Easley JR, Meuten DJ, Levy MG, Dykstra MJ, Breitschwerdt EB, Holzinger EA, Cattley RC. Nasal rhinosporidiosis in the dog. *Vet Pathol.* 1986;23(1):50-6.
8. Feldman SH, Wimsatt JH, Green DE. Phylogenetic classification of the frog pathogen *Amphibiothecum (Dermosporidium) penneri* based on small ribosomal subunit sequencing. *J Wildl Dis.* 2005;41(4):701-6.
9. Fox SM. Surgical extirpation for rhinosporidiosis in a dog. *Comp Cont Ed Pract Vet.* 1986;8(3):152-6.
10. Fredricks DN, Jolley JA, Lepp PW, Kosek JC, Relman DA. *Rhinosporidium seeberi*: a human pathogen from a novel group of aquatic protistan parasites. *Emerg Infect Dis.* 2000;6(3):273-82.
11. Hill SA, Sharket LC, Hardy RM, Wilke VL, Smith MA, Anderson GM. Nasal rhinosporidiosis in two dogs native to the upper Mississippi River Valley region. *J Am Anim Hosp Assoc.* 2010;46(2):127-31.
12. Hobson HP, Simpson RB, Bridges CH. Rhinosporidiosis in the canine. *Texas Vet Med J.* 1977;39:14-9.
13. Hoff B, Hall DA. Rhinosporidiosis in a dog. *Can Vet J.* 1986;27(6):231-2.
14. Jimenez JF, Cornelius JB, Gloster ES. Canine rhinosporidiosis in Arkansas. *Lab Anim Sci.* 1986;36(1):54-5.
15. Karunaratne WAE. The pathology of rhinosporidiosis. *J Pathol.* 1936;42(1):193-202.
16. Kennedy FA, Buggage RR, Ajello L. Rhinosporidiosis: a description of an unprecedented outbreak in captive swans (*Cygnus* spp.) and a proposal for revision of the ontogenic nomenclature of *Rhinosporidium seeberi*. *J Med Vet Mycol.* 1986;33(3):157-65.
17. Lasnier EP. Un nuevo caso de *Rhinosporidium seeberi*. *Bol Soc Anat Patol (Montevideo).* 1930;1(1-2):181-216.
18. Martínez-Martínez A. Rhinosporidiosis en Colombia. Presentación de siete nuevos casos y revisión de la casuística nacional. *UISMed (Colombia).* 1986;14(2):49-60.
19. Mayer HF, Díaz BE. Primer caso de rinosporidiosis (*Rhinosporidium seeberi*) en *Canis familiaris*. *An Inst Med Reg Univ Nac Tucumán.* 1954;4(1):1-8.
20. Meier WA, Meinkoth JH, Bruncker J, Cunningham D, Bahr RJ. Cytologic identification of immature endospores in a dog with rhinosporidiosis. *Vet Clin Pathol.* 2006;35(3):348-52.
21. Miller RI, Baylis R. Rhinosporidiosis in a dog native to the UK. *Vet Rec.* 2009;164(7):210.
22. Moisan PG, Baker V. Rhinosporidiosis in a cat. *J Vet Diagn Inv.* 2001;13(4):352-4.
23. Mosier DA, Creed JE. Rhinosporidiosis in a dog. *J Am Vet Med Assoc.* 1984;185(9):1009-10.
24. Neves CD, Dutra NR, Neto FB, da Silveira LS. Rinosporidiose nasal canina: relato de caso no Brasil. *R Bras Ci Vet.* 1984;21(4):223-5.

25. Ramachandra RPV, Jain SN. Rhinosporidiosis in animals. *Ind J Otol.* 1971;23(3):106-9.
26. Silva V, Pereira CN, Ajello L, Mendoza L. Molecular evidence for multiple host specific strains in the genus *Rhinosporidium*. *J Clin Microbiol.* 2005;43(4):1865-68.
27. Stuart BP, O'Malley N. Rhinosporidiosis in a dog. *J Am Vet Med Assoc.* 1975;167(10):941-2.
28. Sudasinghe T, Rajapakse RPVJ, Perera NAND, Kumarasiri PVR, Eriyagama NB, Arseculeratne SN. The regional sero-epidemiology of rhinosporidiosis in Sri Lankan humans and animals. *Acta Tropica.* 2011;120(1-2):72-81.
29. Vogelsang EG. *Rhinosporidium seeberi*, parásito del bovino. *Rev Med Vet. (Montevideo)* 1924;2(24):279.
30. Wallin LL, Coleman GD, Froeling J, Parker GA. Rhinosporidiosis in a domestic cat. *Med Mycol.* 2001;39(1):139-41.
31. Wilson RB, Pope RW, Sumrall R. Canine rhinosporidiosis. *Comp Cont Ed (Small Anim Pract).* 1989;11(6):730-32.
32. Wolffhügel K. *Rhinosporidium* parásito del equino en Uruguay. *Rev Med Vet. (Montevideo)* 1916;1(5):172-3.