



Original Full Paper

Relationship Between Blood-borne Parameters and Gross Lesions in *Leishmania chagasi* Seroreagents Dogs

Pedro H. O. Viadanna¹, Alessandra A. Medeiros², Matias J. P. Szabó², Antonio V. Mundim²,
Nicolle P. Soares³, Jean E. Limongi⁴, Márcia B. C. Paula⁴

¹DVM, Laboratório de Patologia Comparada de Animais Silvestres, Pós-graduação em Patologia Experimental e Comparada, Departamento de Patologia, FMVZ-USP, São Paulo-SP, Brazil.

²DVM, PHD, Faculdade de Medicina Veterinária – UFU, Uberlândia-MG, Brazil.

³Undergraduated, Faculdade de Medicina Veterinária – UFU, Uberlândia-MG, Brazil.

⁴Centro de Controle de Zoonoses, Prefeitura de Uberlândia, Uberlândia-MG, Brazil.

Corresponding Author: Pedro H. O. Viadanna, Laboratório de Patologia Comparada de Animais Silvestres, Faculdade de Medicina Veterinária e Zootecnia Universidade de São Paulo, Av. Orlando Marques de Paiva, 87, 05508-270, Cidade Universitária, São Paulo/SP, Brasil.

Email: pedroh1986@gmail.com

Submitted February 11th 2011, Accepted September 2nd 2011

Abstract

Canine visceral leishmaniasis, a systemic and chronic zoonosis, is caused in Brazil by the protozoan *Leishmania chagasi*, a widely accepted synonym for *Leishmania infantum*. The agent and disease has recently arrived in Uberlândia city, Minas Gerais, Brazil. In this research, hematological parameters and gross lesions of dogs with visceral leishmaniasis were compared, to highlight aspects of disease in a recent outbreak. For this purpose forty mongrel dogs from Uberlândia seroreagents by ELISA and RIFI tests were selected. Animals were categorized as asymptomatic (AS); oligosymptomatic (OS) and symptomatic (SS). Blood samples were collected and dogs were euthanized according to Brazilian Federal rules. Animals were then submitted to standard necropsy procedures at Veterinary Pathology sector of the Federal University of Uberlândia. Most prominent alterations were observed in respiratory and integumentary systems, with pilose rarefaction (OS: 41.7%, SS: 60.1%), specially periocular (OS: 25.0%, SS: 26.1%) and thoracic/pelvic members (OS: 25.0%, SS: 30.4%). Onychogryphosis (OS: 41.7%, SS: 39.1%), pulmonar edema (OS: 25.0%, SS: 39.1%), and congestion (OS: 41.7%, SS: 60.9%). Moreover animals displayed increase of several organs; liver (67.5%), spleen (60%), lymph nodes (72.5%) and kidney (47.5%). Hematological alterations included low red cell counts and decreased hemoglobin content. Overall, 27.5% of animals presented leukocytosis, 52.5% of dogs had increased band neutrophil counts 5.0% had basophilia and 42.5% monocytopenia. No correlations was found between hematological findings and clinical status of animals (asymptomatic, oligosymptomatic or symptomatic). Presumptively, we can conclude that, in asymptomatic animals there are hematological as well as gross alterations.

Key Words: hematology, Uberlândia, visceral canine leishmaniasis, pathology

Introduction

According to World Health Organization (30), leishmaniasis is one of the six priority endemic diseases of the world and 90% of the cases occur in rural and suburban areas of five countries (Bangladesh, India, Nepal, Sudan and Brazil) (6, 30). Canine visceral leishmaniasis (CVL) is a systemic and chronic zoonosis, caused, in Brazil, by the protozoan *Leishmania chagasi*, a widely accepted synonym for

Leishmania infantum. The dog is considered as a reservoir of the CVL (1, 6, 20), and the agent and disease has recently arrived in Uberlândia city, Minas Gerais, Brazil. In fact that municipality already has an autoctone case of visceral leishmaniasis in human as well as the vector *Lutzomyia longipalpus*. Thus, Health Ministry of Brazil considers the city as a silent and vulnerable area (6, 21).

In order to evaluate the role of the dog in the cycle of CVL infection, and to establish appropriate

control measures aspects of the disease must be known at each locality. Such aspects include clinical and pathological features with description of the extension and progression of lesions in various compromised organs (4).

Classically the disease in dogs has been sorted into three clinical groups; asymptomatic, oligosymptomatic and symptomatic with, respectively, lack of clinical signs, two signs at most or at least with three alterations such as hepatomegaly, splenomegaly, lymphadenopathy, cutaneous lesions, onychogryphosis, alopecia and progressive weight loss (6, 24). At necropsy main alterations were the enlargement and congestion of the liver (19), generalized lymphadenopathy (4), integumentary lesions, (7), and enlargement of the spleen (2). Clinical pathology of CVL usually include anemia, (12, 13), and leucopenia in due to of lymphopenia, eosinopenia and monocytopenia (24, 26).

We herein describe and correlate hematological alterations and gross lesions of dogs with CVL in Uberlândia municipality to evaluate characteristics of the CVL outbreak. Furthermore such observations are a basic step for the forthcoming research that aims to help veterinary clinicians, local health authorities small animal veterinarians as well as diagnosis of canine leishmaniasis in the municipality.

Material and Methods

Animals

A total of 40 dogs seroreagent to *Leishmania chagasi* antigens by enzyme linked immunosorbent assay (ELISA) and indirect reaction of immunofluorescence (RIFI) were selected in Uberlândia (18°55'8"S, 48°16'37"W), Minas Gerais State, Brazil, 2010. Animals were both male and female, mostly adults and included various breeds (25 mongrel dogs, four Pit-bulls, two Pinschers, one Poodle, two Rottweillers, two Boxers, two Daschunds, one Australian Cattle Dog and one Dalmatian) Serological tests and euthanasia were performed in the Centre for Zoonosis Control of the city as determined by Brazilian Federal law. Euthanasia followed American Veterinary Medical Association (AVMA) protocol (5), with physical restraining, anesthesia with intramuscular ketamine hydrochloride (10mg/kg) and xylazine (1mg/kg) followed by intravenous thiopental (12.5 mg/kg) at last a rapid infusion of potassium chloride (1-2mmol/kg), was used IV. All experimental protocols were approved by the Bioethics Committee of Universidade Federal de Uberlândia, Brazil (CEUA/UFU 007/10).

The dogs were four with less than one year old (infant) and 36 with more than one year.

Blood sample collection

Blood samples were collected from either jugular or cephalic veins before euthanasia. Four milliliter samples were transferred to tubes with EDTA.

Samples were immediately processed in Electronic Counter-Cell - ABC Vet Animal Blood Counter (ABX Diagnostics) and slides with blood smears were stained with Quick Panoptic kit for differential leukocytes cells count. The following parameters were evaluated: red blood cell count, hemoglobin, hematocrit, mean cell volume (MCV), mean cell hemoglobin concentration (MCHC), mean corpuscular hemoglobin (MCH), spatial distribution of red blood cells (RDW), platelet count, mean platelet volume (MPV), white blood cell count, band and segmented neutrophils, eosinophils, basophils, monocytes and lymphocytes.

Gross alterations

Dogs were necropsied at Veterinary Pathology sector from the Federal University of Uberlândia. During the necropsies, samples of bone marrow, spleen, liver and lymph nodes were collected for cytological examination (imprinting technique) and skin, heart, kidney, bone marrow, spleen, liver and lymph nodes histopathology. According to the gross alteration observed during necropsy animals were sorted into either one of three groups as described previously (asymptomatic, oligosymptomatic and symptomatic).

Statistical analysis

For statistical analysis two way analysis of variance (ANOVA), correlation (PEARSON), test and post-test of Bonferroni were used. A value of $P < 0.05$ was considered statistically significant. Data were expressed as mean values (standard-deviation). Statistical analyses were performed using Prism software (GraphPad, California, USA).

Results

Blood parameters are presented in table 1. It was observed, that overall parameters varied greatly but mean band neutrophil and basophil numbers were above reference values, whereas erythrocyte numbers and hematocrit were below (Table 01).

Considering anemic animals individually it was observed that 55% had normocytic normochromic anemia, 25% normocytic hypochromic, 5% microcytic hypochromic and 15% microcytic normochromic.

No correlation was found between hematological parameters and gross lesion intensity (asymptomatic, oligosymptomatic and symptomatic) of dogs, (Figure 1), but with a strong correlation (0.99) between them.

Table 1. Mean, standard deviation, maximum and minimum hematological parameters of seroreagents dogs for *Leishmania chagasi*, Uberlândia-MG, 2010.

Parameters Assessed	Mean	SD	Minimum	Maximum	Reference values*	Unit
Erythrocytes	5.13	0.52	1.96	8.28	5.5-8.5	$\times 10^6/\mu\text{L}$
Hemoglobin	12.01	32.79	3.6	65	12.0-18.0	g/dL
Hematocrit	32.9	2.79	12.4	57.7	37-55	%
VCM	63	26	21	72	60-77	fL
MCHC	31.8	0.92	27.9	34.7	31-34	%
HCM	20.3	0.78	17.4	24.5	19-23	pg
RDW	15.2	0.95	12.8	18.6	14-17	%
Platelets	225150.3	34698.7	411	900000	200000-500000	$/\mu\text{L}$
VPM	9.51	0.35	7.2	12.7	6.7-11.1	μm^3
Leukocytes	15330.56	3288.36	1400	24800	6-18000	$/\mu\text{L}$
Band neutrophils	1018.05	825.67	0	4356	0-540	$/\mu\text{L}$
Segmented neutrophils	10324.97	2056.97	952	19662	3600-13860	$/\mu\text{L}$
Eosinophils	600.13	230.18	0	1593	120-1800	$/\mu\text{L}$
Basophils	10.91	124.70	0	216	0	$/\mu\text{L}$
Monocytes	349.33	60.01	0	1770	180-1800	$/\mu\text{L}$
Lymphocytes	3116.64	290.27	364	14823	720-5400	$/\mu\text{L}$

*(14)

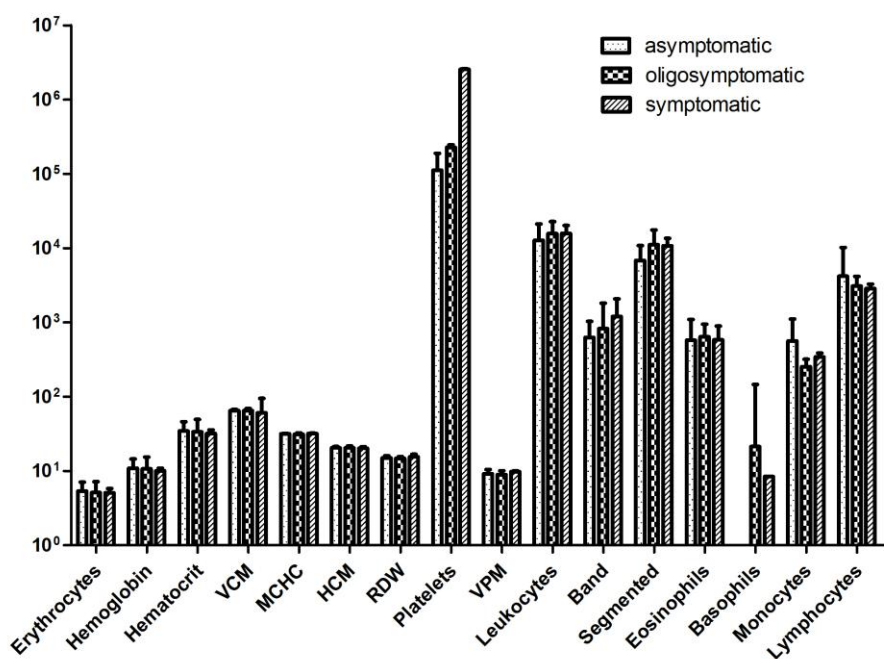


Figure 1. Means and SD of blood parameters of asymptomatic, oligosymptomatic and symptomatic dogs (n=40) seroreagent to *Leishmania* in Uberlândia-MG, 2010.

Most significant gross alterations observed at necropsy were of the respiratory and integumentary systems (Figure 2). Overall organ enlargement was a prominent feature with 67,5% of animals displaying hepatomegaly, 60% splenomegaly, 72,5% lymphadenomegaly and 47,5% kidney enlargement.

Positive correlation was found between symptomatic animals and number of parasitic forms viewed in cytological diagnosis. In fact seven symptomatic animals and one oligosymptomatic displayed parasitic forms under cytological examination. In this exam spleen was the most parasitized organ.

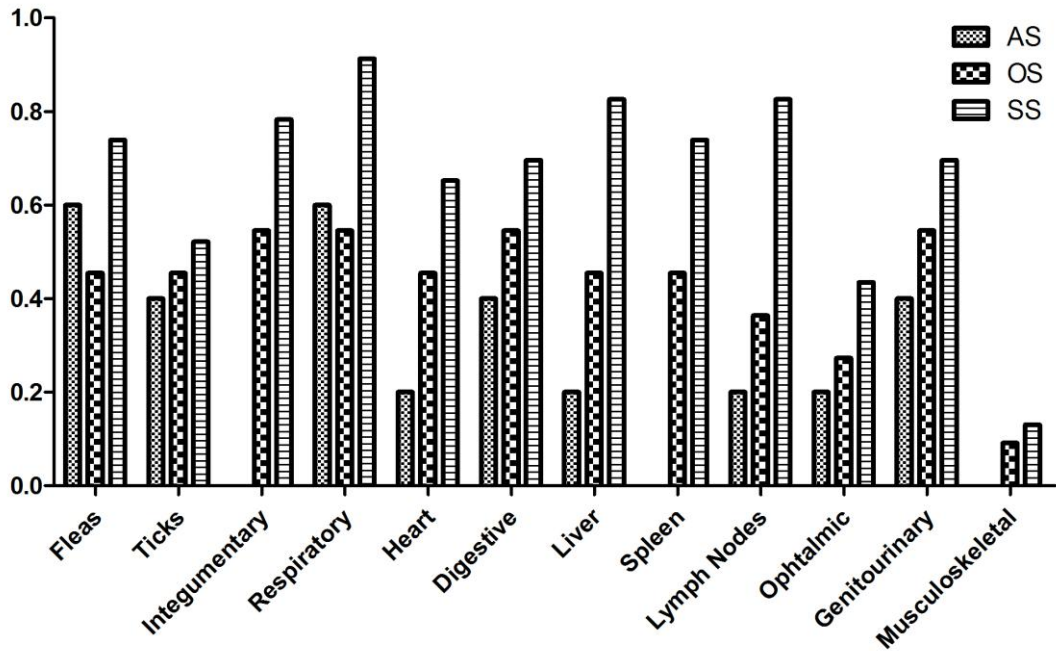


Figure 2. Percentual of specific gross alterations and ectoparasites observed in seroreagents dogs (n=40) to *Leishmania chagasi*, Uberlândia-MG, 2010. AS: asymptomatic, OS: oligosymptomatic and SS: symptomatic.

Lymph node enlargement was the gross feature that better discriminated oligosymptomatic (36% of animals) and symptomatic (82%), animals. Liver,

spleen and kidney enlargement was also more frequent in symptomatic animals (Figure 3).

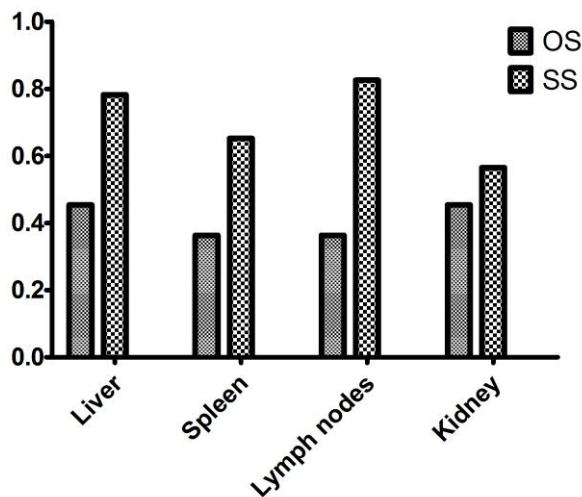


Figure 3. Percentual of animals with volume increase of liver, spleen, lymph node and kidney in oligosymptomatic (OS) and symptomatic (SS) animals. Uberlândia-MG, 2010.

Other specific gross alterations of the *Leishmania* soropositive dogs included bristle rarefaction (OS: 41,7%, SS: 60,1%), specially periocular (OS: 25,0 %, SS: 26,1%) and thoracic/pelvic members (OS: 25,0%, SS: 30,44%) (Figure 04). Onychogryphosis (OS: 41,7%, SS: 39,1%), pulmonary

edema (OS: 25,0%, SS: 39,1%), pulmonary passive hyperemia (OS: 41,7%, SS: 60,9%), dilated cardiomyopathy (OS: 41,7%, SS: 60,9%), and conjunctivitis (OS: 25,0%, SS: 30,4%).

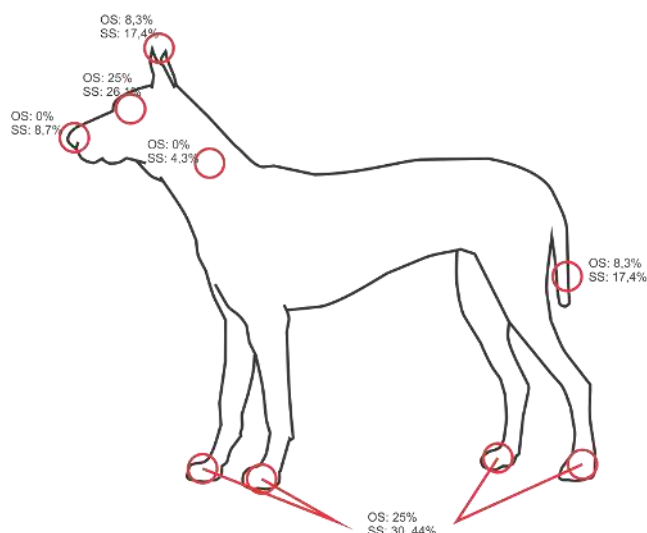


Figure 4. Major areas of bristle rarefaction found in OS: oligosymptomatic and SS: symptomatic. Uberlândia-MG, 2010.

Discussion

CVL is considered an immune-mediated disease due to the host immune system modulation capability of the *Leishmania* (22). The parasite multiplies within macrophages, causes chronic inflammation associated to intense polyclonal B cell proliferation. As a result, hepatosplenomegaly, splenomegaly and generalized lymphadenopathy occur in affected animals (13). The deposition of immune complexes and activation of the complement system in the tissues also collaborate with several gross alterations (16,12), specially in integumentary, respiratory and genitourinary systems. In fact the non-specific inflammation of tissues, edema and vessel proliferation, benefit the parasite by aiding its spread and dissemination (16; 12).

On the other hand chronic inflammation is a feature of several diseases and thus CVL cases might be over or under diagnosed on clinical basis. Moreover CVL as a chronic disease might have symptoms and lesions which fluctuate over time or might be progressive. These features preclude a clear-cut diagnosis and which should rely on an array of information, from clinical to several laboratory based ones. Whatever the case clinical and blood parameters are usually the starting point for diagnosis and should be described at each locality.

Onychogryphosis, a frequent feature of CVL, is attributed to apathy of affected dogs and overproduction of cytokines which stimulate the nail matrix overgrowth (28). The prevalence of onychogryphosis in dogs with CVL (OS: 41,7%, SS: 39,1%) in Uberlândia was similar to those described by Aguiar (2) who but higher in relation to the work of Alves (4) who found a prevalence of 13,3%. Bristle rarefaction of the thoracic/pelvic members that affected 25% of the dogs from this work are considered signs of advanced skin infection (30). Congestion of lungs were also observed by Alves (4) might be explained by

dilated cardiomyopathy which overloads the blood system,.

Prevalence of splenomegaly (60%) and lymphadenopathy (72.5%) were high if compared to other studies. For example Aguiar et al. (2), found respectively only 23.1% and 28.5% of animals affected. Observed integumentary lesion prevalence in dogs in our research, was as high as 85%, higher than that observed by Feitosa(9), who found that 68% dogs with CVL had skin and annexes altered.

Hepatomegaly, observed in 67.5% of our dogs is explained in human infection by the hyperplasia, fibrosis and dilation of sinusoids (17). In dogs, is caused by intense chronic granulomatous inflammatory reaction after dissemination of *Leishmania* to internal organs through lymphatic or blood vessels (29). In this regard Reis (25) observed an intense liver reaction of Kupffer cells, in capsule and portal inflammation as well as the onset of intralobular granulomas. This author observed a direct relationship between, inflammatory reaction intensity, symptoms and parasitism.

Preeminence of spleen alterations were an important feature as this organ were the major site for amastigotes forms as depicted from animals positive by cytological analysis. In fact spleen, has been strongly related as a parasitological marker to decode the clinical status of CVL (27), not applying in our work this relationship (all the cytological positive animals were symptomatic or oligosymptomatic). The contribution of the immune response to the genesis of splenomegaly during CVL is unclear, but with marked balanced production of Th1/Th2 cytokines, with a predominant accumulation of IL-10(25).

Regarding the cell blood count, high percentage of anemia was observed within all dog groups as already observed by Coutinho (10). Such anemia was predominantly normocytic normochromic irrespective of the clinical status of dogs as seen before h Kounitas et al. (15).

31% of animals from our work presented leukocytosis and 58% had increased band neutrophils numbers and 50% monocytopenia. CVL animals do have an increase in IL-10 levels (25) which is a cytokine that decreases antigen presentation and activity of monocytes and therefore, their blood numbers. Decreased immune system capacity probably enhances bacterial assaults and thus requirement for neutrophils. We speculate that this might explain the increase of young neutrophils in blood. According to Reis et al. (24), leucopenia in symptomatic dogs with CVL is common due to monocytopenia, eosinopenia and multifactorial processes with bone marrow, dysfunction of and decreased hematopoiesis(3).

The high percentage of anemic dogs in the oligosymptomatic and symptomatic groups, can be attributed to evolution of the disease's. The predominance of normocytic normochromic anemia is similar to observations of Kounitas et.al (15), who also stated that anemia in LVC is usually non-regenerative normocytic normochromic.

Overall no correlations were found between hematological alterations and clinical status of animals (asymptomatic, oligosymptomatic or symptomatic) depicted from gross lesions. However considering features separately it is clear that some of them are important for initial diagnosis of CVL in Uberlândia. Gross lesions such as skin alterations and organ enlargement are very frequent and should alert clinicians. Anemia and band neutrophilia should also be considered as linked to CVL and should be taken into account in initial diagnosis.

Acknowledgments

This research was supported by the Fundação de Amparo à Pesquisa do Estado de Minas Gerais (FAPEMIG, process number E-001/2009). Viadanna, P.H.O. was financed by FAPEMIG scientific initiation scholarship. We wish to thank the Center of Zoonosis and the Veterinary Hospital – UFU, for the support, the teachers and technicians for the hematology and citopathology exams.

References

1. ABRANCHES, P.; SILVA-PEREIRA, MC.; CONCEICAO-SILVA, FM.; SANTOS-GOMES, GM.; JANZ, JG.. Canine leishmaniasis: pathological and ecological factors influencing transmission of infection. J. Parasitol., 1991, 77, 557-561.
2. AGUIAR, PHP.; SANTOS, SO.; PINHEIRO, AA.; et al. Quadro clínico de cães infectados naturalmente por *Leishmania chagasi* em uma área endêmica do estado da Bahia, Brasil, Rev. Bras. Saúde Prod. An., 2007, 8, 283-294.
3. ALVAR, J., CAÑAVATE, C., MOLINA, R., MORENO, J., NIETO, J. Canine Leishmaniasis. Adv. Parasitol., 2004, 57, 1–88.
4. ALVES, GBB.; PINHO, F.A.; SILVA, SMMS.; CRUZ, MSP.; COSTA, FAL.. Cardiac and pulmonary alterations in symptomatic and asymptomatic dogs infected naturally with *Leishmania (Leishmania) chagasi*. Braz. J. Med. Biol. Res., 2010, 43, 310-315.
5. AVMA. American Veterinary Medical Association. Guidelines on Euthanasia, United States of America. p. 12, 2007.(http://www.avma.org/issues/animal_welfare/euthanasia.pdf)
6. BRASIL. Fundação Nacional de Saúde. Manual de Vigilância e Controle da Leishmaniose Visceral. Ministério da Saúde. Brasília, 2006.
7. CALABRESE, KS., CORTADA, VMCL., DORVAL, MEC., SOUZA LIMA, MAA., OSHIRO, ET., SOUZA, CSF., SILVA-ALMEIDA, M., CARVALHO, LOP., GONÇALVES DA COSTA, SC., ABREU-SILVA, AL.. *Leishmania (Leishmania) infantum/chagasi*: Histopathological aspects of the skin in naturally infected dogs in two endemic áreas. Exp. Parasitol., 2010, 124, 253–257.
8. CIARAMELLA, P.; OLIVA, G.; LUNA, RD.; GRADONI, L.; AMBROSIO, R.; CORTESE, L.; SCALONE, A.; PERSECHINO, A. A retrospective clinical study of canine leishmaniasis in 150 dogs naturally infected by *Leishmania infantum*. Vet. Rec., 1997, 41, 539-543.
9. CORRÊA, WM.; CORRÊA, CNM. Enfermidades infecciosas dos mamíferos domésticos. 2 ed. Rio de Janeiro: MEDSI, 1992.
10. COUTINHO, JFV.. Estudo clínico-laboratorial e histopatológico de cães naturalmente infectados por *Leishmania chagasi* com diferentes graus de manifestação física. 2005. 106p. Dissertação (mestrado). Universidade Federal do Rio Grande do Norte. Orientador Maria de Fátima F. M. Ximenes.
11. COUTINHO, MTZ., BUENO, LL., STERZIK, A., FUJIWARA, RT., BOTELHO, JR., MARIA, M., GENARO, O., LINARDI, PM., Participation of *Rhipicephalus sanguineus* (Acari: Ixodidae) in the epidemiology of canine visceral leishmaniasis. Vet. Paras., 2005, 128, 149–155.
12. IKEDA, FA.; CIARLINI, PC.; FEITOSA, MM. et al. Perfil hematológico de cães naturalmente infectados por *Leishmania chagasi* no município de Araçatuba SP: um estudo retrospectivo de 191 casos. Clín. Vet., 2003, 7, 42-8.
13. FEITOSA, MM., IKEDA, FA., LUVIZOTTO, MCR., PERRI, SHV. Aspectos clínicos de cães com

- leishmaniose visceral no município de Araçatuba - São Paulo (Brasil). Clín. Vet., 2000, 5,36-42.
14. GRAMICCIA, M.; GRADONI, L. Ther current status of zoonotic leishmaniasis and approaches to disease control. Int. J. Parasitol., 2005, 35, 1169-1180.
15. KOUNITAS, AF.; POLIZOPOULOU, ZS.; SARIDOMICHELAKIS, MN. et al. Clinical Consideration on Canine Visceral Leishmaniosis in Greece: a Retrospective Study of 158 cases (1989-1996). J. Amer. Ani. Hosp. Assoc., 1999, 35, 376-83.
16. LOPEZ, M., ORREGO, C., CANGALAYA, M., INGA, R., AREVALO, J. Diagnosis of *Leishmania* via the polymerase chain reaction a simplified procedure for field work. Am. J. Trop. Med. Hyg., 1993, 49, 348-356.
17. MEDEIROS, IM.; NASCIMENTO, ELT.; HINRICHSEN, SL.. Leishmanioses (Visceral e Tegumentar). In _____. DIP - Doenças Infecciosas e Parasitárias. Rio de Janeiro: Guanabara Koogan, 2005, 398-409.
18. MEINKOTH, JH.; CLINKENBEARD, KD. Normal hematology of the dog. In: FELDMAN, BF; ZINKEL, .G.; JAIN, NC. Schalm's veterinary hematology. Philadelphia: Lippincott Williams e Wilkins, 2000: 1055-1063.
19. MELO FA. , MOURA, EP., RIBEIRO. RR., ALVES, CF., CALIARI, MV., TAFURI, WL., CALABRESE, KS., TAFURI, WL.. Hepatic extracellular matrix alterations in dogs naturally infected with *Leishmania* (*Leishmania*) *chagasi*. Int. J. Exp. Path. 2009, 90, 538-548.
20. PAULA, AA.; SILVA, AVM.; FERNANDES, O.; JANSEN, AM. The use of immunoblot analysis in the diagnosis of canine visceral leishmaniasis in an endemic area of Rio de Janeiro. J Parasitol., 2003, 89, 832-836.
21. PAULA, MBC., RODRIGUES, EAS., SOUZA, AA., REIS, AA., et al. Primeiro encontro de *Lutzomyia longipalpis* (*Lutz* & *Neiva*, 1912) na área urbana de Uberlândia, MG, concomitante com o relato de primeiro caso autóctone de leishmaniose visceral humana. Rev. Soc. Bras. de Med. Trop., 2008, 41, 304-305.
22. PINELLI, E.; KILLICK-KENDRICK, R.; WAGENAAR, J.; BERNADINA, W.; REAL, G.; RUITENBERG, J. Cellular and humoral immune responses in dogs experimentally and naturally infected with *Leishmania infantum*. Infect. Immun., 1994, 62, 229-35.
23. REIS, A.. Avaliação de parâmetros laboratoriais e imunológicos de cães naturalmente infectados com *Leishmania* (*Leishmania*) *chagasi*, portadores de diferentes formas clínicas da infecção. Thesis. UFMG. 2001.
24. REIS, AB.; MARTINS-FILHO, OA.; CARVALHO, AT.; CARVALHO, MG.;et al. Parasite density and impaired biochemical/hematological status are associated with severe clinical aspects of canine visceral leishmaniasis Res. Vet. Sci., 2006, 81, 68-75.
25. REIS, AB., MARTINS-FILHO, OA., TEIXEIRA-CARVALHO, A., GIUNCHETTI, RC., CARNEIRO, CM., MAYRINK, W., TAFURI, WL., CORRÊA-OLIVEIRA, R.. Systemic and compartmentalized immune response in canine viscera *Leishmaniasis*. Vet. Immunol. Immunopathol.. 2009, 128, 87-95.
26. REIS, AB., TEIXEIRA-CARVALHO, A., GIUNCHETTI, RC., GUERRA, LL., CARVALHO, MG., MAYRINK, W., GENARO, O., CORREA-OLIVEIRA, R., MARTINS-FILHO, OA.. Phenotypic features of circulating leucocytes as immunological markers for clinical status and bone marrow parasite density in dogs naturally infected by *Leishmania chagasi*. Clin. Exp. Immunol.. 2006, 146, 303-311.
27. REIS, AB., TEIXEIRA-CARVALHO, A., VALE, AM., MARQUES, MJ., GIUNCHETTI, RC., MAYRINK, W., GUERRA, LL., ANDRADE, RA., CORREA-OLIVEIRA, R., MARTINS-FILHO, OA.. Isotype patterns of immunoglobulins: hallmarks for clinical status and tissue parasite density in Brazilian dogs naturally infected by *Leishmania* (*Leishmania*) *chagasi*. Vet. Immunol. Immunopathol. 2006, 112, 102-116.
28. SILVA, ES.; ROSCOE, EH.; ARRUDA, L. Q. Leishmaniose visceral canina: estudo clínico-epidemiológico e diagnóstico. R. Bras. Med. Vet. 2001, 23, 11-116.
29. TAFURI, WL.; OLIVEIRA, MR.; MELO, MN.; TAFURI, WL. Canine visceral leishmaniosis: a remarkable histopatological picture of one case reported from Brazil. Vet. Parasitol., 2001, 96, 203-212.
30. WHO. Report of the Fifth Consultative Meeting on *Leishmania*/HIV Coinfection Addis Ababa, Ethiopia, 20-22 March 2007 World Health Organization 2007.