BJVP
Brazilian Journal of Veterinary Pathology

Case Report

Congenital Nephroblastoma in a Buffalo Calf

Vemuri Rama Devi[1], Galan Veeraiah[2], Kolagani Yedukondalu[3], Shaik K. Begum[4]
Pillutla Annapurna[1], Penumaka Sunitha[1], Matha A. Devi[1]

[1]Department of Veterinary Pathology, NTR College of Veterinary Science, Gannavaram, India.
[2]Assistant Director, Buffalo Breeding Centre, Nekarikallu, A.P, India.
[3]Assistant Director, Veterinary Hospital, Narasaraopet, A.P, India
[4]Veterinary Assistant Surgeon, Veterinary Dispensary, Dechavaram, Nekarikallu, A.P.
Corresponding Author: Vemuri R. Devi, Department of Veterinary Pathology, NTR College of Veterinary Science, Gannavaram - 517502, India.*E.mail*: vrdpath@yahoo.com

Submitted May 23rd 2011, Accepted October 17th 2011

Abstract

A nine years old, Graded Murrah she buffalo was brought to the veterinary hospital with clinical signs of labour and dystocia. A caesarian section was performed and a dead male calf was noticed in the uterus. At necropsy, the calf had distended abdomen with the presence of an enlarged mass. Histopathologically, the tissue sections from the mass revealed the presence of blastemal cells forming glomeruli like structures and tubules in some areas and mesenchymal tissue suggesting a congenital nephroblastoma that developed during fetal life resulting in maternal dystocia and death of the calf.

Key Words: buffalo calf, kidney, nephroblastoma

Introduction

Nephroblastoma or embryonal nephroma is a congenital neoplasm that develops during fetal life or post natal life. It originates from metanephric blastema and the tumor is a mixture of embryonic renal tissue with immature glomerular like buds, tubules and myxomatous mesenchyme in various amounts (5). These tumors are common in young animals, especially pigs and chicken, but are rare in cattle. (4). There are reports of nephroblastoma in a bovine fetus (3), in a 2 month old Hariana calf (6) and in an adult sheep (2). It is observed also in rats (4).

The present paper describes a rare case of nephroblastoma in a male buffalo calf that developed during fetal life and noticed at the time of parturition leading to dystocia of dam and death of the calf.

Case Report

A 9 years old graded Murrah female buffalo that was pregnant for the third time and showing clinical signs of labour and dystocia after completion of full gestation period was brought to Veterinary Hospital, Narasaraopet, Andhra Pradesh, India from a near by village. After careful examination, it was decided to conduct caesarian operation. After opening the abdomen and uterus, a dead male calf was found in the uterus. The calf had distended abdomen with normal presentation (Fig.1). On necropsy, a huge, slightly round and encapsulated mass (60 x 40 cm) weighing about 10 kg and occupying the abdominal cavity was noticed in the calf . The capsule was about 2 cm. in thickness and after removal of the capsule the surface was grayish white with occasional cystic areas filled with fluid. On cut surface, it appeared like kidney but, there was no demarcation of cortex and medulla and the pelvis was distended and contained fat (Fig. 2). The tissue pieces from the mass were collected and sent in 10% formalin for histopathological diagnosis to NTR College of Veterinary Science, Gannavaram and they were processed routinely by paraffin embedding and the sections were stained with H&E.

 All rights reserved 2007.



Figure 1: Buffalo calf with nephroblastoma. Note distended abdomen.

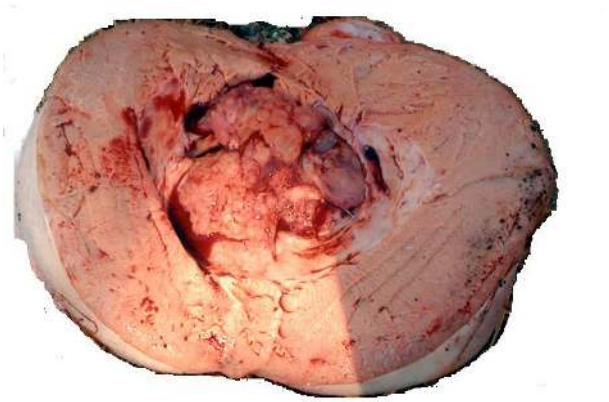

Figure 2: Nephroblastoma of buffalo calf. Enlarged kidney with distended pelvis filled with fat.

Results and Discussion

Histologically, the tissue sections revealed cellularity comprising of three types of cells viz. blastemal, epithelial and mesenchymal. The blastemal cells were arranged in dense, irregularly shaped clusters and nests. These cells were round with scanty cytoplasm and round nucleus. In some areas the blastemal cells formed glomeruloid structures and tubular structures lined by cuboidal epithelial cells (Fig.3). Some tubules were cystically dilated and a few also contained eosinophilic material. Mitoses was distinctly present in the blastemal areas. Spindle shaped cells comprised the mesenchymal component. The gross and histological appearance of the tissue sections of the mass in the present case were consistent with a diagnosis of nephroblastoma. (3, 5, 6, 7). They are presumed to arise because of the failure of the metanephric blastema to under go its normal differentiation pathway. The blastema differentiates to form nephrons and supporting connective tissue. These tumors establish the important principle that all component tissues of the kidney arise from a common blastema (4). In humans, it has been shown that loss of function of tumor suppressor genes, including WT1, is a major factor in nephroblastoma development (1). In the present case, the exact cause of development of nephroblstoma was not known and to the author's knowledge, this is the first report of a congenital nephroblastoma that developed during fetal life resulting in maternal dystocia and death of a male buffalo calf.

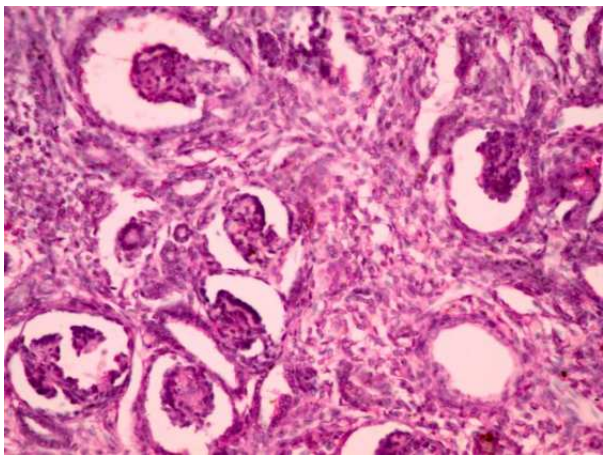

Figure 3: Photomicrography of nephroblastoma of buffalo calf showing glomeruloid and tubular structures surrounded by mesenchymal stroma. H&E obj. 40x

References

1. BROWN KW., MALIK KT. The molecular biology of Wilms' tumor. Exp. Rev. Mol Med. 2001: 3:1-16.

2. HEADLEY SA, SAUT JP, MAIORKA PC. Nephroblastoma in an adult sheep. Vet. Rec. 2006, 159:850- 852.

3. KIRKBRIDE CA., BICKNELL EJ. 1972. Nephroblastoma in a bovine fetus. Vet. Path. 1972, 9 : 96-98.

4.MAXIE MG. The urinary system . In Jubb KVF, Kennedy PC and Palmer N eds . The Pathology of Domestic animals, 4th Edn,Vol.2, 1993: 518-522.

5. MEUTEN DJ. Tumors of the urinary system. In MEUTEN, DJ. ed. Tumors of Domestic animals. 4 Edn. 2002:509-546.

6. SRIVASTAVA AK., SHARMA DN., DWIVEDI JN. Nephroblastoma in a calf. Vet. Rec. 1989, 125; 245-146.

7. YAMAMOTO YU., YAMADA M., NAKAMURA K., TAKAHASHI Y., MIYAMOTO, T. Nephroblastoma with transcoelomic metastasis in a Japanese Black bull. J. Vet. Med. Sci. 2006, 68:891-893.