BJVP
Brazilian Journal of Veterinary Pathology

Case Report

Fibrous Osteodystrophy in a Captive Common Eland Antelope (*Taurotragus oryx*)

Fabrizio Grandi[1,2], Lourdes M. B. Pessoa[3], Francisco Lúcio Filho[4], Rochele de Araújo[5], Rafael M. Rocha[6], Cláudia Del Fava[7]

[1]Laboratory of Investigative and Comparative Pathology, School of Veterinary Medicine and Animal Science, Univ. Estadual Paulista – UNESP, Botucatu, Brazil
[2]Department of Pathology, Botucatu Medical School, Univ. Estadual Paulista – UNESP, Botucatu, Brazil
[3]Fioravante Galvani Park, Luís Eduardo Magalhães – Bahia, Brazil
[4]School of Veterinary Medicine, Ceará State University - UECE, Ceará, Brazil
[5]Haras Claro Comercial Farmer, Caucaia – Ceará, Brazil
[6]Department of Investigative Pathology, A. C. Camargo Cancer Hospital, Antônio Prudente Foundation, São Paulo, Brazil
[7]Center for Research and Development in Animal Healthy, Biological Institute, São Paulo, Brazil
Corresponding Author: Fabrizio Grandi, Laboratory of Investigative and Comparative Pathology, School of Veterinary Medicine and Animal Science, Univ. Estadual Paulista – UNESP, Botucatu, Brazil. P.O. Box 560, Zip code 18618-000, Distrito de Rubião Júnior, Botucatu city, São Paulo State, Brazil, Tel +55 14 38116293
E-mail: fgrandivet@gmail.com

Submitted July 22nd 2011, Accepted October 10th 2011

Abstract

Fibrous osteodystrophy (FO) is a common condition described mainly in domestic species, with only few cases described in wild ones kept in captivity. Herein we report a case of FO in a 2 yr-old female common eland antelope (*Taurotragus oryx*) maintained in captivity and fed with a horse pelleted ration plus hays. The animal showed a firm bilateral symmetrical enlargement of upper maxillary bones which was submitted to histological evaluation. Microscopic findings were those related to extensive bone resorption and fibroplasia.

Key Words: antelope, eland, fibrous osteodystrophy, pathology, *Taurotragus oryx*.

Case Report

The common eland (*Taurotragus oryx*) is an animal who belongs to the order Artiodactyla, subfamily Bovinae. These captive wild ruminants have been fed commercial diets similar to those animals used for commercial purposes, which increase the rate of mineral imbalances and secondary diseases such osteodystrophia fibrosa (1).

Fibrous osteodystrophy (FO) is a generalized bone disease caused by prolonged and excessive secretion of parathyroid hormone (PTH) and is characterized by extensive resorption of normal hard bone and its replacement by fibrous connective tissue (2, 3). It is a metabolic disease associated with primary or secondary hyperparathyroidism. The former, is a rare condition in animals and generally are associated with a parathyroid adenoma. The last, is due to a nutritional imbalance, which result in lower serum-ionized calcium and increased synthesis and secretion of PTH (2, 4).

The aim of this paper is to describe a case of fibrous osteodystrophy in a common eland antelope (*Taurotragus oryx*) maintained in captivity and to discuss potential causes associated with this disease.

A 2-yr-old captive female common eland antelope, maintained in Caucaia Farm, was presented for clinical evaluation due to a chronic facial deformity. The animal was submitted to chemical restraint with ketamine (1.0 mg/Kg) and xylazine (0.3 mg/Kg) in order to proceed to physical examination. The animal showed bilateral symmetrical enlargement of upper maxillary bones (Fig. 1) and chronic weight loss. The enlarged bones were firm and painless on palpation. No other abnormalities were detected on physical evaluation.

The animal diet was composed by a mixture of variable proportion of *Brachiaria decubens*, *Brachiaria*

 All rights reserved 2007.

brizanta, *Pennisetum purpureum*, and *Cynodon nlemfuemsis* hays on morning, and pelleted horse ration on evening containing 12% (min.) crude protein, 10% (max.) crude fiber, 5% (min.) fat, 10% (max.) ash, 1.3% (max.) calcium, and 0.5% (min.) phosphorus. However, *Brachiaria spp* hays were always the main component since it presents a better acceptance by the animal. The water was given in an "*ad libitum*" regimen.



Figure 1. Common eland antelope. Marked bilateral symmetrical enlargement of upper maxillary bones.

Biopsy samples were obtained from multiple regions of both maxillae, fixed in 10% neutral-buffered formalin, and submitted to the Center for Research and Development in Animal Healthy – Biological Institute, for further histological analysis. The tissues were trimmed, routinely processed and embedded in paraffin wax. Routine histological sections 4 µm in thickness were stained with Hematoxilin and Eosin (HE), Alizarin Red S, Masson trichrome, Ziehl-Neelsen, Gram, and Gomori-Grocott and evaluated by light microscopy. Two days after the procedure, the animal was found dead by the owner in an advanced putrefaction state. Thus, we are unable to obtain a full biochemical, hematological and necropsy profile.

Histologically, it was noted a discrete number of small trabeculae of non-mineralized osteoid tissue with a high number of active osteoclasts, and an intense fibroblastic proliferation associated with a marked fibrous connective tissue deposition on intertrabecular spaces (Fig. 2 and 3). Masson trichrome and Alizarin Red S stained positively for fibrous and bone tissue, respectively. Ziehl-Neelsen, Gram, and Gomori-Grocott stains were negative for acid-fast and non-acid fast bacteria, and fungi.

Biopsy findings from our captive common eland antelope are consistent with severe fibrous osteodystrophy which had been reported in several domestic and wild species including Kudu antelopes (5). However, to the best of our knowledge, FO was not described in the common eland antelope maintained in captivity.

The antelope lived in a restricted area with other wild ruminants that were not fed with the same diet and showed no clinical signs. Actually, we don't have sufficient data concerning the adaptability of this specie in captivity, since there is no antelope farming in Brazil; however, given the potential to be domesticated, new reports describing metabolic diseases in these animals are of great interest.

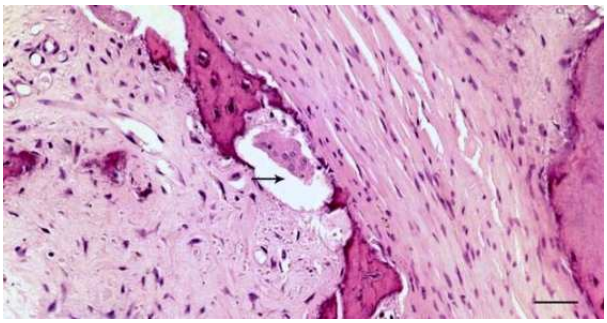

Figure 2. Photomicrography of a fibrous osteodystrophy in a common eland antelope. Note the marked fibroplasia and osteoclasia with a multinucleate giant cell in Howship lacunae (arrow). Hematoxilin and Eosin, 400x., bar= 100µm.

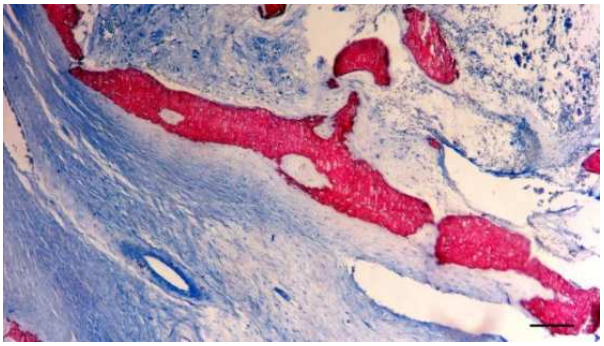

Figure 3. Photomicrography of a fibrous osteodystrophy in a common eland antelope. Note the marked fibroplasia (in blue) and bone trabeculae (in red). Alizarin red, 100x, bar = 50µm.

Pathological findings in this case are related to a hyperparathyroidism condition affecting the facial bones. Primary hyperparathyroidism is usually the result of a functional parathyroid gland adenoma which is rarely described in adult dogs, horses and cattle (4). Although necropsy evaluation was not performed, those are unlikely hypothesis since there are no related clinical signs such polydipsia/polyuria, and muscular weakness (4) in this case.

The facial swelling resembles those observed in maxillary bones and mandibles of animals with secondary hyperparathyroidism which is a much more common cause of FO in animals and may be due to either chronic renal disease or a dietary imbalance of calcium and phosphorus (4).

Renal secondary hyperparathyroidism occur mainly in adult dogs with renal failure, but the skeletal lesions are usually of secondary importance to the manifestation of uremia (4). A biochemical analysis for renal disease was not performed in this case due to lack of clinical manifestations related to renal insufficiency.

Eland populations have been reported to vary considerably in their diet, with various studies classifying them as browsers, mixed feeders or even grazes, behaving like concentrate selectors under some conditions and roughage feeders under others. The reason for the wide variation in reported contributions of grazing and browsing in eland diet remains unclear, but could be related to the season and type of food available (6, 7). Despite those diet variations, the antelope was exclusively fed with a unique farm diet consisting in a mixture of hays plus pellet food for horses during all seasons.

The long-term feeding of animals with diet containing low calcium and relatively high phosphorus levels leads to hypocalcemia which results in parathyroid stimulation and increased secretion of PTH. Increased levels of PTH cause diminished renal tubular reabsorption of phosphorus and increased rate of calcium absorption in bones which leads to facial deformity (2).

Minerals requirements for wildlife ruminants have traditionally been evaluated in relation to deficiency and their imbalance may constitute a chronic problem in some captive exotic ungulates. In domestic cattle, chronic changes may take months or longer to develop and only a small percentage of the affected herd will show clinical signs (1, 8, 9, 10). Actually, there are no information related to normal levels of mineral requirements to the common eland antelope, and also serum calcium: phosphorus (Ca:P) ratio responsible for causing FO, although recent feeding recommendations have attempted to address these concerns (9). The total intake of calcium and phosphorus was not quantified due to technical limitations, but was presumed to be inadequate since the diet was given in a mixed fashion, i.e. pelleted food plus hays which in turn might contribute to mineral imbalance and subsequent FO development.

Several grasses, including *Brachiaria decumbens* contain significant amounts of calcium-binding oxalates that can have a direct effect on mineral homeostasis in horses leading to fibrous osteodystrophy (4). It is therefore the most probably mechanism by which our antelope developed a calcium deficiency and subsequent fibrous osteodystrophy lesions. The high content of oxalates binds to calcium to form calcium-oxalate (Ca $[COO]_2$), which is insoluble and makes it unavailable for absorption (4, 5). However, another point to be considered it is whether antelope have oxalate-catabolyzing bacteria in the foregut that could convey some resistance to the deleterious effects of oxalate consumption. However, there is no such study regarding the composition of the ruminal microbial flora in antelopes.

There is one study describing a combination of low serum calcium and high serum phosphorus in a *T. oryx* fed with a highly fermentable carbohydrate diet (9). This fact could contribute to the FO observed in this case. However, the levels of fermentable carbohydrates was not specified by the fabricant nor measured due to technical limitations.

The microscopic features of FO are similar to those find in domestic animal species. The lesions are more pronounced in flat bones, particularly those of the skull, and are characterized by extensive resorption of normal hard bone, increased osteoclastic bone resorption, marked fibroplasia, and increased osteoblastic activity with formation of immature woven bone (4). Additionally, Masson trichrome confirm the colagenous nature of the replaced tissue, and Ziehl-Neelsen, Gomori-Groccot, and Gram methods didn´t reveal the presence of fungi, acid-fast, and non-acid fast bacteria, respectively.

Concluding, the possible cause of the bone pathology in this antelope was related to a metabolic disorder, more specifically a Ca:P imbalance that leads to a secondary nutritional hyperparathyroidism and clinical signs.

References

1. MILLER MA., WEBER M. Hypocalcemia, hypomagnesemia, and rumenitis in exotic ruminants. FOWLER ME., MILLER RE. Eds. Zoo & Wild Animal Medicine. St. Louis Missouri:Saunders Elsevier, 2008: 404-407.

2. ASLANI MR., MOVASSAGHI AR., MOHRI R., SEIFI HA. Outbreak of osteodystrophia fibrosa in young goats. J. Vet. Med., 2001, 48,385-389.

3. LYNCH MT., SLOCOMBE RF., HARRIGAN KE., LAING CJ. Fibrous osteodystrophy in dromedary camels (*Camelus dromuedarius*). J. Zoo Wildl. Life Med., 1999, 30, 577-583.

4. THOMPSON K. Bones and Joints. JUBB KVF., KENNEDY PC., PALMER NC. Eds. Pathology of Domestic Animals. Saunders Elsevier, 2007: 2-180.

5. HALLIWELL WH., HAHN FF. Fibro-osseous lesions in the mandible and maxilla of greater kudus. MONTALI R.J., MIGAKI G. Eds. The Comparative Pathology of Zoo Animals. Washington, D.C.: Smithsonian Institution Press, 1980: 573-578.

6. UNDERWOOD, R. The feeding behavior of grazing African ungulates. Behaviour, 1983, 84, 195-243.

7. WALLINGTON BP., MCKECHNIE AE., OWEN-SMITH N., WOODBORNE, S. Stable carbon isotope analysis of eland (*Taurotragus oryx*) diet in the Suikerbosrand Nature Reserve. S. Afr. J. Wildl. Res., 2007, 37, 127-131.

8. BALL RL., BURTON M., LEGER JST., DUMONCEAUX G., OLSEN JH. Comparison of parathyroid hormone, calcium, phosphorus, and magnesium in serum and urine of nyala (*Tragelaphus angasii*) on concentrates or a forage only diet. Proc. Am. Assoc. Zoo Vet. Annu. Meet., 2003, 13–14.

9. MILLER M., WEBER M., VALDES EV., NEIFFER D., FONTENOT D., FLEMING G., STETTER M. Changes in serum calcium, phosphorus, and magnesium levels in captive ruminants affected by

diet manipulation. J. Zoo Wildl. Life Med., 2010, 41, 404-408.

10. VAHALA J. Magnesium deficiency in captive antelope. Vet. Rec., 1997, 140, 207–208.