



## Case Report

# Pneumonia in Broiler Chicken Flocks Associated with $\beta$ -Hemolytic *Ornithobacterium rhinotracheale* Infection

Carlos D. Gornatti Churria<sup>1</sup>, Pablo L. Sansalone<sup>2</sup>, Germán B. Vigo<sup>3</sup>, Guillermo H. Sguazza<sup>4</sup>,  
Mariana A. Machuca<sup>5</sup>, Javier A. Origlia<sup>1</sup>, Miguel V. Píscopo<sup>1</sup>, Miguel A. Herrero Loyola<sup>1</sup>,  
Miguel A. Petrucelli<sup>1</sup>

<sup>1</sup>Cátedra de Patología de Aves y Pilíferos y Laboratorio de Diagnóstico de Enfermedades de las Aves y los Pilíferos, FCV - UNLP, Facultad de Ciencias Veterinarias, Universidad Nacional de La Plata, La Plata, Argentina

<sup>2</sup>Vetanco S.A., Argentina

<sup>3</sup>Laboratorio de Diagnóstico e Investigaciones Bacteriológicas, FCV - UNLP

<sup>4</sup>Cátedra de Virología, FCV - UNLP

<sup>5</sup>Cátedra de Patología Especial, FCV - UNLP

**Corresponding author:** Carlos D. Gornatti Churria, Cátedra de Patología de Aves y Pilíferos y Laboratorio de Diagnóstico de Enfermedades de las Aves y los Pilíferos, Facultad de Ciencias Veterinarias, Universidad Nacional de La Plata (UNLP)  
CC 296 B 1900 AVW, La Plata, Argentina.

E-mail: [danielgornatti@fcv.unlp.edu.ar](mailto:danielgornatti@fcv.unlp.edu.ar)

Submitted July 26<sup>th</sup> 2011, Accepted September 2<sup>nd</sup> 2011

## Abstract

Broiler chickens aged 40 and 46-days-old from two neighboring flocks belonging to a commercial broiler complex, presenting facial edema, severe respiratory signs and 10% mortality were analyzed. Pneumonic lesions and opaque thoracic and abdominal air sacs with foamy exudate were seen at postmortem examination. Histopathology of lungs showed fibrinoheterophilic pneumonia in both cases. Small pin point colonies with extensive  $\beta$ -hemolytic activity were isolated from tracheal and lung tissue samples and identified as *Ornithobacterium rhinotracheale* by polymerase chain reaction (PCR). Results of lung histopathology, bacteriological isolation and PCR identification confirmed the diagnosis of pneumonia caused by  $\beta$ -hemolytic *O. rhinotracheale* infection in both broiler chicken flocks. This paper appears to be the first report of  $\beta$ -hemolytic *O. rhinotracheale* field isolates obtained from broiler chickens associated with severe respiratory signs and pneumonia.

**Key Words:** *Ornithobacterium rhinotracheale*,  $\beta$ -hemolysis, pneumonia, broiler chickens

## Introduction

*Ornithobacterium rhinotracheale* is a gram-negative, highly pleomorphic, non-motile, nonsporulating bacterium (2, 3, 15), with inconsistent results for biochemical tests (2). *Ornithobacterium rhinotracheale* is associated with respiratory disease in avian species, primarily turkeys and chickens (2), and is considered as a primary pathogen (17). At postmortem examination, pneumonia and foamy white, “yoghurt-like” exudate in the air sacs are seen in broiler chickens and turkeys (2, 3, 15, 16). The causing agent was first identified as a non- $\beta$ -hemolytic microorganism (2, 3, 8, 15), such as the ATCC 51463 strain of *O. rhinotracheale* (13). However, it was demonstrated the

$\beta$ -hemolytic activity among North American *O. rhinotracheale* field strains isolated from affected turkeys (13, 18).

This is the first work to report the isolation and identification of  $\beta$ -hemolytic *O. rhinotracheale* field strains from tracheal and lung samples of broiler chickens with severe respiratory signs and pneumonia.

## Materials and Methods

### Case Report

Two neighboring 40 and 46-day-old broiler chicken flocks composed of 70,000 and 100,000 birds from a commercial broiler complex located in Buenos

Aires, Argentina, were studied by a poultry veterinarian because of the clinical signs noticed in both cases. Depression, reduced food intake, sneezing, nasal discharge, facial edema, and 10% mortality were observed. During the former winter season, similar signs were noticed in flocks from the named complex. Refrigerated lung and tracheal samples and serum samples from both flocks were submitted to the Laboratorio de Diagnóstico de Enfermedades de las Aves y los Pilíferos (Cátedra de Patología de Aves y Pilíferos, Facultad de Ciencias Veterinarias, Universidad Nacional de La Plata, Buenos Aires, Argentina) in September 2010. .

#### Pathology

At field necropsy, several poultry carcasses from both flocks showed unilateral and bilateral exudative pneumonic lesions, and opaque thoracic and abdominal air sacs with foamy exudate. Tracheal and lung tissues samples were fixed in 10% buffered formalin embedded in paraffin for 2 days, sectioned at approximately 4  $\mu$ m, and stained with haematoxylin and eosin (H&E) for histological evaluation.

#### Serology

Twenty five serum samples from each flock were tested using commercially available enzyme-linked immunosorbent assays (ELISAs) for the detection of antibodies against infectious bursal disease (IDEXX IBD Ab test, IDEXX Laboratories, Inc., Westbrook, ME, USA), Newcastle disease virus (IDEXX NDV Ab test, IDEXX Laboratories, Inc.), infectious bronchitis virus (IDEXX IBV Ab Test, IDEXX Laboratories, Inc.), and avian pneumovirus (IDEXX APV Ab Test, IDEXX Laboratories, Inc.), according to the manufacturer's directions. Moreover, plate agglutination tests were performed to detect antibodies against *Mycoplasma synoviae* and *Mycoplasma gallisepticum* infections by the use of commercial available antigens, such as MS RPA-Test (SOLEIL SARL, Cantenay-Épinard, France) and MG RPA-Test (SOLEIL SARL).

#### Bacterial isolation

Lung and trachea samples were inoculated in Mac Conkey's agar (Agar Mac Conkey, Laboratorios Britania S.A., Buenos Aires, Argentina) and incubated aerobically for 24 hr at 37°C. Tissue samples were also inoculated onto 10% defibrinated goat blood agar (Agar Nutritivo, Laboratorios Britania S.A.) and 10% defibrinated horse blood agar (Agar Nutritivo, Laboratorios Britania S. A.), both with the addition of 5  $\mu$ g/ml gentamicin (Gentamicina Interbiol, Laboratorio Interbiol S.R.L., Buenos Aires, Argentina) and incubated at 37°C in a candle jar for 48 hr. After incubation, both goat and horse blood agar plates were placed at room temperature for 48 hr and evaluated for the presence of  $\beta$ -hemolytic activity, as previously recommended (13). The isolates obtained were

analyzed by GRAM's stain (GRAM Britania, Laboratorios Britania S.A.), catalase test (Hydrogen peroxide 30%, Merck, Germany) and oxidase test (Monodiscos Oxidasa, Laboratorios Britania S.A.), following the manufacturer's recommendations. Moreover, solid and liquid Frey's medium (7) with 15% swine serum were used to isolate *Mycoplasma* spp. and incubated aerobically during seven days at 37°C.

#### Antimicrobial susceptibility

In vitro antibiotic susceptibility tests were performed by disc diffusion method (4, 11), using the following antibiotic discs (Monodiscos Britania, Laboratorios Britania S. A., and Vetanco S. A., Argentina): ampicilin, ceftiofur, gentamicin, enrofloxacin, erythromycin, doxycycline, florfenicol, trimethoprim sulfa, and fosfomicin. Blood Mueller Hinton agar plates were inoculated and evaluated after 24 hr of incubation at 37°C.

#### DNA extraction and PCR identification

DNA was extracted from pin point colonies isolated in blood agar plates with gentamicin from both cases using a DNA commercial extraction kit (Wizard® Genomic DNA Purification Kit, Promega Co., Madison, WI, USA) according to the manufacturer's instructions. *Ornithobacterium rhinotracheale* was identified by polymerase chain reaction (PCR) assay using the pair of primers OR16S-F1 (5'-GAGAATTAATTTACGGATTAAG-3') and OR16S-R1 (5'-TTCGCTTGGTCTCCGAAGAT-3'), (8). Amplification and detection were carried out with an IQ™5 Multicolor Real-Time PCR Detection System (BIO-RAD Laboratories, Hercules, CA, USA). The real-time PCR mixtures were prepared with 12.5  $\mu$ l of SYBR Green (IQ™ SYBR® Green Supermix, BIO-RAD Laboratories, Hercules, CA, USA), 1  $\mu$ l of each primer (10  $\mu$ M), 7.5  $\mu$ l of nuclease free water and 3  $\mu$ l of DNA extract (48  $\mu$ g/ml and 51  $\mu$ g/ml, respectively) made up to 25  $\mu$ l of mixture. Real-time PCR was performed using the following program: 1 cycle of 94 °C for 5', 45 cycles of 94 °C for 30'', 52 °C for 1', and 72 °C for 1' 30'', and 72 °C for 7', followed by the determination of the melting curve, which was carried out through increases of 0.2 °C every 30'' to a final temperature of 95 °C (66 steps). The PCR products were analyzed in a 1.5% agarose gel electrophoresis study with a 100 bp molecular weight marker (100 bp DNA Ladder®, Promega Co., Madison, WI, USA), stained with ethidium bromide, and visualized with ultraviolet light

#### Results and Discussion

The histopathologic examination of the lung sections showed diffuse accumulation of variable numbers of heterophils and fibrin in the air passages and interstitial tissue (Fig. 1). Fibrinous exudate with

heterophilic cells was noted in tertiary bronchi. In addition, several necrotic areas were seen in both cases. Microscopic examination of tracheas showed no evidence of lesions.

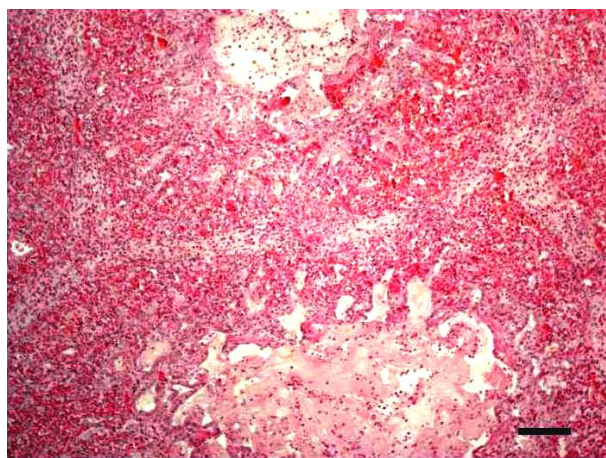


Figure 1: Section of a 46-day-old chicken lung showing diffuse accumulation of fibrin and heterophils in air passages and interstitial tissue. H&E, 100 X. Bar = 100  $\mu$ m.

Negative results of plate agglutination tests for *M. synoviae* and *M. gallisepticum* were found in both cases. According to manufacturer values, no serological evidence of infections caused by infectious bursal disease virus, Newcastle disease virus, infectious bronchitis virus and avian pneumovirus were detected in both flocks.

No *Mycoplasma* spp. growth was revealed in Frey's agar plates or liquid medium, no enterobacteria was seen in MacConkey's agar plates, but small pin point colonies with extensive  $\beta$ -hemolytic activity were observed after the 48h-period following incubation in blood agar plates of both cases. Both isolates were gram-negative pleomorphic rods, with negative results for catalase test and positive for oxidase test.

Both field strains were identified as *O. rhinotracheale* by conventional PCR and real-time PCR. The melting temperature showed no significant differences between the  $\beta$ -hemolytic *O. rhinotracheale* field isolates (86.2°C) and the non-hemolytic ATCC 51463 control strain of *O. rhinotracheale* (86°C). Moreover, the molecular weight of the PCR products from the  $\beta$ -hemolytic and non-hemolytic strains was similar (784 bp).

Because of the resistance of one or both strains against erythromycin, trimethoprim-sulfa, enrofloxacin, doxycycline and fosfomycin, it is proposed that adequate antimicrobial strategies will be useful for the control of this bacterium in broiler chicken flocks.

Because of the absence of serological responses against several infectious agents, it is supposed that housing environmental factors possibly triggered the immunosuppressive effect involved in the development of *O. rhinotracheale* infections.

*Ornithobacterium rhinotracheale* has been isolated and characterized in some countries of Latin America, such as Mexico (12), Peru (10), Brazil (1) and

Argentina (14), but its hemolytic activity among field isolates had not been described before. This paper describes for the first time the isolation and identification of  $\beta$ -hemolytic *O. rhinotracheale* field strains in Latin America and also, despite the numerous worldwide reports about *O. rhinotracheale* infection in poultry, the first  $\beta$ -hemolytic *O. rhinotracheale* isolates obtained from broiler chickens with severe respiratory signs.

Unilateral and bilateral lung consolidation with fibrinous exudate has been previously seen in clinical cases due to *O. rhinotracheale* infections in both chickens and turkeys (2, 9). Microscopically, the lesions caused by *Pasteurella multocida* and *O. rhinotracheale* are characterized by large areas of necrosis with edema and accumulation of fibrin and heterophils in the interstitial tissues and air passages (5). Moreover, fibrinoheterophilic diffuse pneumonia in turkeys is suspected to be caused by *O. rhinotracheale* infection (6). In the present work, the bacteriological isolation, PCR identification and lung microscopic findings confirmed the diagnosis of fibrinoheterophilic pneumonia due to  $\beta$ -hemolytic *O. rhinotracheale* infection in both broiler chicken flocks.

Despite the slight differences between the sodium-dodecyl sulfate-polyacrylamide gel electrophoresis protein profiles of the  $\beta$ -hemolytic and the non-hemolytic field isolates previously studied (18), the greater hemolytic activity of the hemolytic phenotypes among several North American *O. rhinotracheale* field isolates is still not linked with more severe respiratory symptoms *in vivo* (13). In the present study, the authors found no evidence of the association between the severity of respiratory clinical signs noted in broiler chickens at field conditions and the  $\beta$ -hemolytic activity of *O. rhinotracheale* strains observed *in vitro*.

In spite of the lack of differences between the molecular weight of the PCR products and the melting points from the non-hemolytic strain and the  $\beta$ -hemolytic field isolates analyzed in this study, further field and experimental studies will be necessary to demonstrate whether the  $\beta$ -hemolytic activity has a possible connection with an increased virulence in poultry. Also, further pathologic studies should be carried out to analyze the relationship between the presence of gross and microscopic lesions in low respiratory organs and the  $\beta$ -hemolytic and non-hemolytic field isolates obtained from those cases.

#### Acknowledgments

We thank Dr. Florencia Pantozzi from Laboratorio de Diagnóstico e Investigaciones Bacteriológicas for professional assistance and Roberto Abán for histotechnical assistance. We especially thank Dr. Frederic Hoerr for his advices.

#### References

1. CANAL, CW., LEÃO, JA., ROCHA, SLS., MACAGNAN, M., LIMA-ROSA, CAV.,

- OLIVEIRA, CD., BACK, A. Isolation and characterization of *Ornithobacterium rhinotracheale* from chickens in Brazil. *Res. Vet. Sci.*, 2005, 78, 225-230.
2. CHIN, RP., CHARLTON, BR. Ornithobacteriosis. DUFOUR-ZAVALA, L., SWAYNE, DE., GLISSON, JR., PEARSON, JE., REED, WE., JACKWOOD, MW., WOOLCOCK, PR., Eds. A Laboratory Manual for the Isolation, Identification, and Characterization of Avian Pathogens. 5 ed. Madison: American Association of Avian Pathologists, 2008: 75-76.
  3. CHIN, RP., VAN EMPEL, PCM., HAFEZ, HM. *Ornithobacterium rhinotracheale* infection. SAIF, YM., FADLY, AM., GLISSON, JR., MCDUGALD LR., NOLAN LK., SWAYNE DE., Eds. Diseases of Poultry. 12 ed. Oxford: Blackwell Publishing Ltd., 2008: 765-774.
  4. CLINICAL AND LABORATORY STANDARDS INSTITUTE. Performance Standards for Antimicrobial Disk and Dilution Susceptibility Tests for Bacteria Isolated from Animals; Approved Standard. 3 ed. CLSI Document M31-A3, Clinical and Laboratory Standards Institute, Wayne, 2008.
  5. FLETCHER, OJ., ABDUL-AZIZ, T., BARNES, HJ. Respiratory system. FLETCHER, OJ., ABDUL-AZIZ, T., Eds. Avian Histopathology. 3 ed. Madison: American Association of Avian Pathologists, 2008: 128-163
  6. FLETCHER, OJ. 2010. Avian histopathology in the digital age, update on virtual slides. Respiratory system. 4.3 Lung (<http://www.ncsu.edu/project/poultryhealth/fletcher/cbs595/learning-module-04/LM4LC3Master/LM4LC3/LM4-LC3-all.html>).
  7. FREY, MC., HANSON, R., ANDERSON, DP. A medium for the isolation of avian mycoplasmas. *Am. J. Vet. Res.*, 1968, 29, 2164-2171.
  8. HAFEZ, HM. Diagnosis of *Ornithobacterium rhinotracheale*. *Int. J. Poult. Sci.*, 2002, 1, 114-118.
  9. HINZ, K.-H., BLOME, C., RYLL, M. Acute exudative pneumonia and airsacculitis associated with *Ornithobacterium rhinotracheale* in turkeys. *Vet. Rec.*, 1995, 135, 233-234.
  10. HUNG, AL., ALVARADO, A. Phenotypic and molecular characterization of isolates of *Ornithobacterium rhinotracheale* from Peru. *Avian Dis.*, 2001, 45, 999-1005.
  11. INSTITUTO NACIONAL DE ENFERMEDADES INFECCIOSAS, ANLIS – “Dr. Carlos G. Malbrán”. XVII Curso Intensivo de Actualización en Antimicrobianos “Dra. Alicia Rossi” y XII Curso Latinoamericano de Actualización en Antimicrobianos. Servicio de Antimicrobianos, Departamento de Bacteriología. Buenos Aires, Argentina, 2003.
  12. SORIANO, VE., LONGINOS, MG., NAVARRETE, PG., FERNANDEZ, RP. Identification and characterization of *Ornithobacterium rhinotracheale* isolates from Mexico. *Avian Dis.*, 2002, 46, 686-690.
  13. TABATABAI, LB., ZIMMERLI, MK., ZEHR, ES., BRIGGS, RE., TATUM, FM. *Ornithobacterium rhinotracheale* North American field isolates express a hemolysin-like protein. *Avian Dis.*, 2010, 54, 994-1001.
  14. URIARTE, J., PISCOPO, M., ORIGLIA, J., GORNATTI, D., CERDA, R., HERRERO, M., PETRUCCELLI, M. Primer aislamiento de *Ornithobacterium rhinotracheale* en Argentina. *Analecta Vet.*, 2009, 29, 53-55.
  15. VAN EMPEL, PCM., HAFEZ, HM. *Ornithobacterium rhinotracheale*: a review. *Avian Pathol.*, 1999, 28, 217-227.
  16. VAN VEEN, L., GRUYS, E., FRIK, K., VAN EMPEL, P. Increased condemnation of broilers associated with *Ornithobacterium rhinotracheale*. *Vet. Rec.*, 2000, 147, 422-423.
  17. VAN VEEN, L., VAN EMPEL, P., FABRI, T. *Ornithobacterium rhinotracheale*, a primary pathogen in broilers. *Avian Dis.*, 2000, 44, 896-900.
  18. WALTERS, J., MAINOUS, M., CRAIG, M., EVANS, R., PIERSON, FW. Unusual phenotypic characteristics of *Ornithobacterium rhinotracheale* in Virginia. *Proceedings 81st Northeastern Conference on Avian Diseases (NECAD)*, Grantville, USA, 2009.