BJVP
Brazilian Journal of Veterinary Pathology

Case Report

Cryptococcus gattii and *Cryptococcus albidus* in Captive Domestic Pigeon (*Columba livia*)

Karin Werther[1], Eliane de Sousa[1], José R. F. Alves Júnior[1], Francisca A. Ardisson[1], Maria J. S. M. Giannini[2]

[1]Departamento de Patologia Veterinária, FCAV - UNESP - São Paulo State University, Jaboticabal - SP, Brazil,
[2]Departamento de Análises Clínicas, Faculdade de Ciências Farmacêuticas, UNESP - Câmpus Araraquara - SP, Brazil.
Corresponding Author: Karin Werther, Departamento de Patologia Veterinária, FCAV - UNESP - São Paulo State University, Via Paulo Castellane, km 5, Jaboticabal - SP, Brazil, CEP 14884-900
E-mail: werther@fcav.unesp.br

Submitted September 1st 2011, Accepted October 27th 2011

Abstract

Cryptococcosis in animals is an important fungal disease caused by the encapsulated yeast *Cryptococcus neoformans*. This report describes the occurrence of *Cryptococcus gattii* and *Cryptococcus albidus* in domestic pigeon (*Columba livia*), living together with other birds in a breeding center. The animal presented a pinkish, vascularized mass with gelatinous aspect localized subcutaneously under the right lower eyelid, with approximately 2cm in diameter. At microbiological exam it was isolated *Cryptococcus gatti* from the eyelid mass, lungs and liver, *C. albidus* from the trachea and both Cryptococcus species from muscle and kidney.

Key Words: Bird diseases, *Cryptococcus gatti*, *Cryptococcus albidus*, public health

Cryptococcosis is a disease caused by the encapsulated yeast *Cryptococcus neoformans* and *C. gattii*. The *Cryptococcus* species complex includes two basidiomycetous encapsulated yeast species, *C. neoformans,* an opportunistic pathogen, and *C. gattii*, a primary pathogen. Two varieties of *C. neoformans* are recognized, *C. neoformans* var. *grubii* (serotype A), which is found worldwide, and *C. neoformans* var. *neoformans* (serotype D), which occurs mainly in Europe and South America (15, 18). *C. gattii* was previously known as *C. neoformans* var. *gattii* (serotype B and C), and thought to be restricted to tropical and subtropical zones (4, 12, 14, 22) until a recent outbreak of cryptococcosis occurred on Vancouver Island, Canada, which has expanded the range of this yeast to temperate regions. It is an important zoonotic disease that can be fatal, affecting mostly people with immune depression (19, 20).

Cryptococcus gattii is associated with plants of the genus *Eucalyptus* sp. (1, 3) besides being isolated from humans (9, 24), *C. albidus* has been also isolated from humans (10, 17).

The natural reservoirs of *C. neoformans* are pigeon excrements and soil contaminated by bird feces (8, 23). This fungus has been isolated from columbiformes (5), psitaciformes (21) and ratite birds (7). In pigeons, the literature describes the isolation of *C. neoformans* serotype A of the craw of pigeons in captivity and serotype D in pigeons excrement collected in northern Europe (2). In addition there are descriptions of cryptococcosis caused by *C. neoformans* in Beccari´s crowned pigeon and in Bartlett´s bleeding-hear pigeon (6).

A study performed in São Paulo-SP using pigeons feces collected in the environment of urban areas showed the presence of *C. neoformans.* Fungus growth was higher (72.7%) in samples collected from places without solar radiation than of samples collected from other sites, showing the sensitivity of the agent in relation to the environment (16).

This report describes the occurrence of *Cryptococcus gattii* and *Cryptococcus albidus* in domestic pigeon (*Columba livia*), from conservation breeding facility living together with other birds. The bird, a male of 256g body weight presented a

 All rights reserved 2007.

subcutaneous mass in the right lower eyelid (Fig. 1). The needle aspiration biopsy of the mass revealed structures like *Cryptococcus* sp.



Figure 1: Domestic pigeon (*Columba livia*) with subcutaneous mass in the right lower eyelid (arrow).

The bird was euthanized and necropsied. Gross examination revealed a pinkish, gelatinous and vascularized mass with approximately 2cm in diameter in the subcutaneous of the right lower eyelid, (Fig. 2). Fragments of this gelatinous mass and of several organs were collected for mycological culture in agar Niger (14) and histopathological exam. The latter revealed structures like *Cryptococcus* spp. yeast in the gelatinous mass (Fig. 3). *C. gattii* was isolated from the eyelid mass, lung and liver, *C. albidus* from the trachea, and both species simultaneously from muscle and kidney.

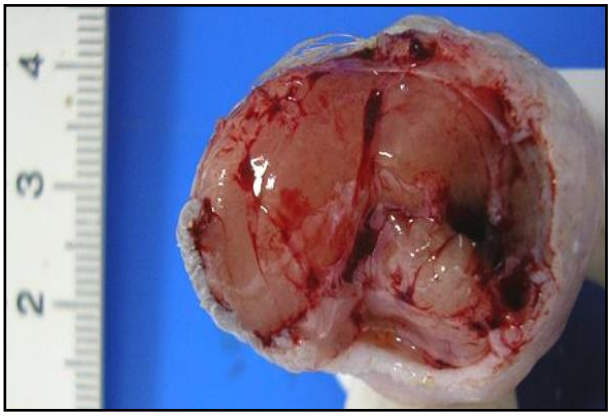

Figure 2: Macroscopic aspect of the cut surface of the mass (see Figure 1).

In natural conditions, pigeons in captivity show *C. neoformans* var. *grubii* (serotype A) in crop and *C. neoformans* var. *neoformans* (serotype D) in excrement (2). Although there is a correlation between the presence of *C. neoformans* in feces of pigeons, or places of pigeons habitat, the birds are rarely infected, maybe due to their high body temperature (41.5 to 43.3°C) (11), despite other authors demonstrated active infection in birds (21). Thus, this study confirms the presence of active cryptococcosis in a domestic pigeon, a bird that has the body temperature around 42°C. The subcutaneous mass observed in this report is consistent with findings of other authors in pigeons also (13).

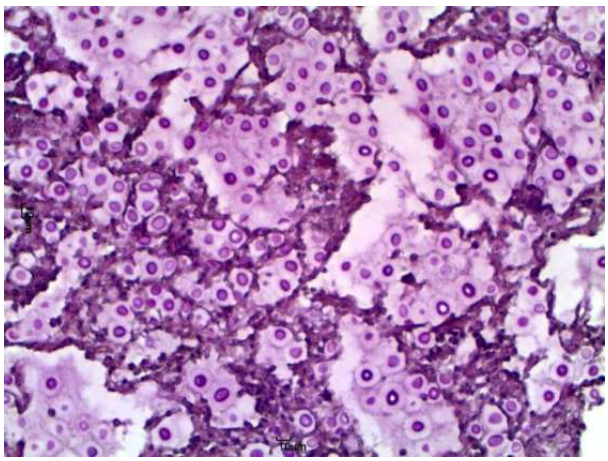

Figure 3: Microscopic aspect of the mass showing *Criptococcus* sp. structures. PAS, obj. 20x.

The importance of this report is related primarily to the isolation of *C. neoformans gattii* and *C. albidus* in pigeons, as these agents are usually associated with plants and human diseases, respectively. This isolation pointed out either a higher agent pathogenicity for birds or a greater susceptibility of them. Secondly, the presence of *C. albidus* in pet birds kept in shelters is a major risk for animal and public health.

References

1. BALTAZAR LM., RIBEIRO MA. Primeiro isolamento ambiental de *Cryptococcus gattii* no Estado do Espírito Santo. Rev. Soc. Bras. Med. Trop., 2008, 41, 5, 449-453.

2. BENNETT JE., KWONG KJ., HOWARD DH. Epidemiologic differences among serotypes of *Cryptococcus neoformans*. Am. J. Epidemiol., 1977, 105, 6, 582-586.

3. CALLEJAS A., ORDONEZ N., RODRÍGUEZ MC. CASTANEDA, E. First isolation of *Cryptococcus neoformans* var. *gattii*, serotype C, from the environment in Colombia. Med. Mycol., 1998, 36, 341-344.

4. CASADEVALL A., PERFECT JR. *Cryptococcus neoformans*. Washington, DC: ASM press, 1998.

5. GRINER LA., WALCH HA. Cryptococcosis in columbiformes at the San Diego Zoo. J. Wildl. Dis., 1978, 14, 389-394.

6. GRINER LA. Order Columbiformes. In: GRINER LA (Ed.). Pathology of Zoo Animals. Zoological Society of San Diego, 1983, 205-214.

7. HILL FI., WOODGYER AJ., LINTOTT MA. Cryptococcosis in a North Island brown Kiwi (*Apteryx australis mantelli*) in New Zealand. J. Med. Vet. Mycol., 1995, 33, 305-309.

8. KHOSRAVI AR. Isolation of *Cryptococcus neoformans* from pigeon (*Columbia livia*) droppings in North of Iran. Mycopathologia, 1997, 139, 2, 93-95.

9. KIDD SE., CHOW Y., MAK S., BACH PJ., CHEN H., HINGSTON AO., KRONSTAD JW., BARTLETT KH. Characterization of Environmental Sources of the Human and Animal Pathogen *Cryptococcus gattii* in British Columbia, Canada, and the Pacific Northwest of the United States. Appl. Environ. Microbiol., 2007, 73, 5, 1433–1443.

10. KORDOSSIS T., AVLAMI A., VELEGRAKI A., STEFANOU I., GEORGAKOPOULOS G., PAPALAMBROU C., LEGAKIS NJ. First report of *Cryptococcus laurentii* meningitis and a fatal case of *Cryptococcus albidus* cryptococcaemia in AIDS patients. Med. mycol., 1998, 36, 5, 335-339.

11. KWON-CHUNG KJ., BENNETT JE. Cryptococcosis. Med. mycol., Philadelphia. PA: Lea & Febiger, 1992, 397-446.

12. KWON-CHUNG KJ., BENNETT JE. Epidemiologic differences between the two varieties of *Cryptococcus neoformans*. Am. J. Epidemiol., 1984, 120, 123-130.

13. MALIK R., KROCKENBERGER MB., GROSS G., DONELEY R., MADILL DN., BLACK D., MCWHIRTER P., ROZENMAX A., ROSE K., ALLEY M., FORSHAW D., RUSSELL-BROWN I., JOHNSTONE AC., MARTIN P., O'BRIEN CR., LOVE, DN. Avian cryptococcosis. Med. Mycol., 2003, 41, 2, 115-124.

14. MENDES-GIANNINI MJS., MELHEM MSC. Infecções Fúngicas. In: FERREIRA AW., ÁVILA SLW. Diagnóstico Laboratorial das Principais Doenças Infecciosas e Auto-imunes. São Paulo. Guanabara Koogan, 1996, 219-275.

15. MEYER W., CASTAÑEDA A., JACKSON S., HUYNH M., CASTAÑEDA E.; IberoAmerican Cryptococcal Study Group. Molecular typing of IberoAmerican *Cryptococcus neoformans* isolates. Emerg. Infect. Dis., 2003, 9, 2, 189-195.

16. MONTENEGRO H., PAULA CR. Environmental isolation of *Cryptococcus neoformans* var. *gattii* e *Cryptococcus neoformans* var. *neoformans* in the city of São Paulo, Brazil. Med. Mycol., 2000, 38, 385-390.

17. NARAYAN S., BATTA K., COLLOBY P., TAN C. Cutaneous **Cryptococcus** infection due to **C. albidus** associated with Sézary syndrome. Br. J. Dermatol., 2000, 143, 632–634.

18. NISHIKAWA MM., LAZERA MS., BARBOSA GG., TRILLES L., BALASSIANO BR., MACEDO RC., BEZERRA CC., PÉREZ MA., CARDARELLI P., WANKE B. Serotyping of 467 *Cryptococcus neoformans* isolates from clinical and environmental sources in Brazil: analysis of host and regional patterns. J. Clin. Microbiol., 2003, 41, 1, 73-77.

19. NOSANCHUK JD., SHOHAM S., FRIES BC., SHAPIRO DS., LEVITZ SM., CASADEVALL A. Evidence of zoonotic transmission of *Cryptococcus neoformans* from a pet cockatoo to an immunocompromised patient. Ann. Intern. Med., 2000, 132, 3, 205-208.

20. PASSONI LFC., WANKE B., NISHIKAWA MM., LAZÉRA MS. *Cryptococcus neoformans* isolated from human dwellings in Rio de Janeiro, Brazil: an analysis of the domestic environment of AIDS patients with and without cryptococcosis. Med. Mycol., 1998, 36, 305-311.

21. RASO TF., WERTHER K., MIRANDA ET., MENDES-GIANNINI MJS. Cryptococcosis outbreak in psittacine birds in Brazil. Med. Mycol., 2004, 42, 4, 355-362.

22. REOLON A., PEREZ LRR., MEZZARI A. Prevalência de *Cryptococcus neoformans* nos pombos urbanos da cidade de Porto Alegre, Rio Grande do Sul. J. Bras. Patol. Med. Lab., 2004, 40, 5, 293-298.

23. SANTANA LS, COSTA MSF., QUEIROZ LA. Ocorrência de *Cryptococcus neoformans* (Sanfelice) Vuillemin (1901) em excretas de pombos no perímetro urbano de Salvador, Bahia, Brasil. Sitientibus Ser. Ci. Biol., 2007, 7, 2, 170-175.

24. UPTON A., FRASER JA., KIDD SE., BRETZ C., BARTLETT KH., HEITMAN J., MARR KA. First Contemporary Case of Human Infection with *Cryptococcus gattii* in Puget Sound: Evidence for Spread of the Vancouver Island Outbreak. J. Clin. Microbiol., 2007, 45, 9, 3086–3088.