



Case report

Pulmonary Aspergillosis due to *Aspergillus flavus* Infection in a Captive Eclectus Parrot (*Eclectus roratus*)

Carlos D. Gornatti Churria¹, Francisco J. Reynaldi^{2,3}, Javier A. Origlia¹,
Hugo A. Marcantoni⁴, Miguel V. Píscopo^{1,4}, Miguel A. Herrero Loyola¹,
Enso H. Reinoso², Miguel A. Petruccelli¹

¹Cátedra de Patología de Aves y Pilíferos y Laboratorio de Diagnóstico de Enfermedades de las Aves y los Pilíferos, FCV-UNLP, Facultad de Ciencias Veterinarias, Universidad Nacional de La Plata, La Plata, Argentina

²Cátedra de Micología Médica e Industrial "Prof. Dr. Pablo Negroni", FCV-UNLP

³CCT CONICET La Plata, Consejo Nacional de Investigaciones Científicas y Técnicas, Buenos Aires, Argentina

⁴Cátedra de Producción de Aves y Pilíferos, FCV-UNLP

* **Corresponding Author:** Carlos Daniel Gornatti Churria, Cátedra de Patología de Aves y Pilíferos y Laboratorio de Diagnóstico de Enfermedades de las Aves y los Pilíferos, Facultad de Ciencias Veterinarias, Universidad Nacional de La Plata, CC 296 B1900AVW, La Plata, Argentina. E-mail: danielgornatti@fcv.unlp.edu.ar

Submitted October 19th 2011, Accepted March 6th 2012

Abstract

A 2-year-old captive, male Eclectus parrot (*Eclectus roratus*), with a previous history of neurologic signs episodes, was found dead in its cage without premonitory signs in a private aviary. At necropsy, yellow and caseous nodules were observed in the lungs. Microscopically, the nodules were composed of granulomas that had a necrotic center with intralésional hyphae typical of *Aspergillus* spp. and a peripheral inflammatory cell response composed of macrophages and multinucleated giant cells. The mycologic culture allowed the isolation and identification of *A. flavus* from lung samples. The gross and microscopic lesions, in combination with the mycologic identification provided the diagnosis of pulmonary aspergillosis due to *A. flavus* infection. To the authors' knowledge, this is the first report of mycotic pneumonia caused by *A. flavus* infection in Psittaciformes.

Key Words: *Aspergillus flavus*, captivity, *Eclectus roratus*, pneumonia, pulmonary aspergillosis

Avian aspergillosis is characteristically a disease of captivity (1, 4, 11). *Aspergillus fumigatus* is the most common etiologic agent implicated (4, 7). It is a frequent cause of respiratory disease in companion, aviary and free-ranging birds (1). It has been found in several species of captive and wild New and Old World parrots (1, 2, 4, 6) and high prevalence values have been reported in African grey parrots (*Psittacus erithacus*) and blue-fronted Amazon parrots (*Amazona aestiva*) (1). In psittacine birds, the upper respiratory system (sinuses, larynx and syrinx) is often affected but the most serious disease occurs with infection of the lower respiratory system (lungs and air sacs) (12). The infection may cause chronic and insidious disease or peracute death (1).

A 2-year-old male Eclectus parrot (*Eclectus roratus*) was submitted from a private aviary located in La Plata (Buenos Aires Province, Argentina) to the Laboratorio de Diagnóstico de Enfermedades de las Aves y los Pilíferos (Cátedra de Patología de Aves y Pilíferos, Facultad de Ciencias Veterinarias, Universidad Nacional de La Plata, La Plata, Argentina) in December 2010 for its postmortem examination. The parrot had been raised in captivity and its death happened six months after importation. Episodes of neurologic signs including torticollis and ataxia had been suffered by the parrot since its arrival. No antemortem tests had been performed.

Necropsy examination revealed pectoral muscle atrophy. The lungs showed yellowish and caseous nodules approximately 0.5 cm in diameter (Fig. 1). Multifocal

eosinophilic granulomas of variable size were observed replacing and compressing the lung tissue. No gross lesions were observed in the upper respiratory tract, trachea, air sacs or other organs. Tissue samples from cerebrum, cerebellum, proventriculus, gizzard, heart, liver, spleen, kidney, trachea, air sacs and lungs were fixed in 10% buffered formalin, embedded in paraffin, sectioned at approximately 3 μ m, and stained with hematoxylin and eosin for microscopic evaluation. Samples of pulmonary granulomas were analyzed with Gueguen' stain to detect the presence of fungal hyphae. Samples from cerebrum, cerebellum, liver, spleen and lungs were cultured in 10% defibrinated horse blood agar plates (Agar Nutritivo, Laboratorio Britania S.A., Buenos Aires, Argentina), and Mac Conkey's agar plates (Agar Mac Conkey, Laboratorio Britania S.A.). Both were incubated aerobically for 24 hr at 37°C. Also, sterile and refrigerated cerebrum, cerebellum and lung samples were sent to the Cátedra de Micología Médica e Industrial "Prof. Dr. Pablo Negroni" (Facultad de Ciencias Veterinarias, Universidad Nacional de La Plata) for mycologic isolation. Tissue samples were cultured onto Sabouraud dextrose agar plates (Merck Química Argentina S.A.I.C., Buenos Aires, Argentina) with the addition of chloramphenicol and cycloheximide and incubated at 37°C for ten days under aerobic conditions.

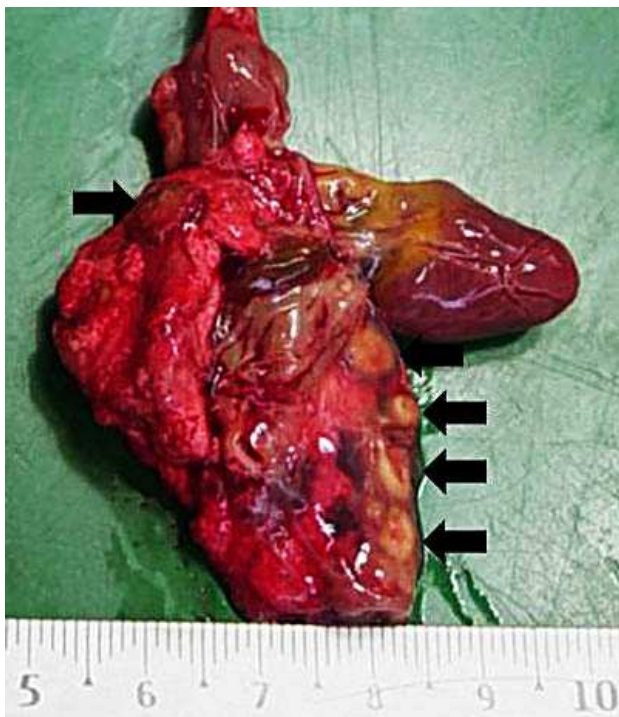


Figure 1 - Lungs of a 2-year-old Eclectus parrot (*Eclectus roratus*) showing yellowish and caseous pulmonary nodules identified as fungal granulomas of approximately 0.5 cm in diameter (arrows).

The fresh examination of lung granulomas using Gueguen' stain showed typical hyphae of *Aspergillus* spp. characterized by septate and dichotomously branched structures with parallel hyphal walls.

Microscopically, granulomas consisted of a central mass of necrotic exudate within typical and numerous intralesional hyphae of *Aspergillus* spp. as unstained structures, and a variable peripheral inflammatory cell reaction of macrophages and multinucleated giant cells. Moreover, numerous and typical hyphae of *Aspergillus* spp., were seen in air passages and interstitial tissue (Fig. 2). In addition, extensive lesions due to the coalescence of adjacent parabronchial granulomas were observed. No microscopic lesions were found in other organs.

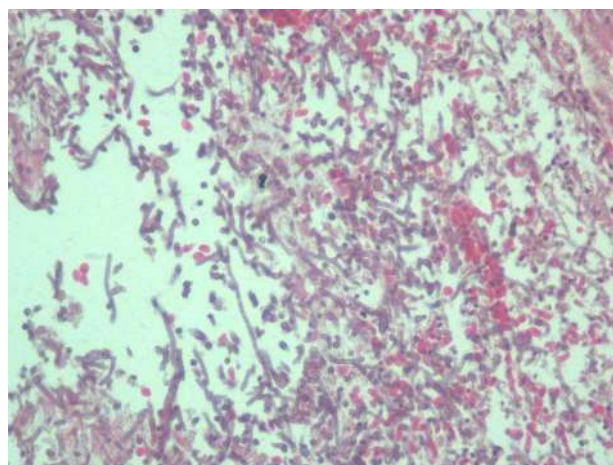


Figure 2 - Lung section of the affected parrot showing numerous hyphae typical of *Aspergillus* spp. H&E, 400 X.

No bacterial growth was seen in horse blood agar or Mac Conkey's agar plates, but Sabouraud agar plates revealed fungal presence isolated from lung samples. Following mycologic descriptions (7), the *Aspergillus* species involved was identified as *A. flavus*, because it showed yellow-green colonies, and it were observed radiate to columnar conidial heads with rough-walled stipes, and smooth to finely roughened conidia.

Aspergillosis typically occurs as a result of inhalation of its ubiquitously available spores (10). However, because of the good hygiene, sanitation practices and a recent history without cases due to *Aspergillus* spp. infection of the local aviary where the Eclectus parrot died, it is presumed that the bird was a latent carrier at the time of its arrival to its new location. Moreover, analysis of food for *Aspergillus* spp. spores and mycotoxins had been periodically performed by the aviary's owner, with negative results.

The gross lesions, histopathologic findings and mycologic isolation and identification provided the diagnosis of pulmonary aspergillosis due to *A. flavus* infection.

The stress caused by the new environment and the episodes of neurologic signs possibly contributed with the immunosuppressive effect involved in the development of the mycotic pneumonia.

Despite the absence of gross and microscopic lesions in cerebrum and cerebellum, no isolation of fungi from brain samples and no examination of spinal column and cord, the neurological signs observed could be associated with spinal cord and thoracic vertebrae lesions such as osteomyelitis and secondary degenerative myelopathy or myelitis produced by the fungal infection of air sacs.

The identification of the *Aspergillus* species played a key role in the diagnosis of mycotic pneumonia due to the lack of differences between the pulmonary lesions caused by *A. flavus* infection in this case and those previously described in several avian cases due to non-*Aspergillus flavus* infections (1, 3, 5, 11).

Aspergillus flavus infection is associated with pulmonary and disseminated fungal disease in Galliformes (10, 11), but mycotic pneumonia due to *A. flavus* infection had not been previously described in psittacine birds. To the authors' knowledge, in spite of the numerous worldwide reports about mycotic pneumonia due to *Aspergillus* spp. infection in psittacine birds, this is the first report describing pulmonary aspergillosis caused by *A. flavus* infection in Psittaciformes.

Aspergillosis is not a zoonotic or contagious disease (3), but with the exposure to an environmental source of *Aspergillus* spp., both birds and humans could develop an acute infection in the respiratory system that may then spread to other organs (4). Moreover, *A. flavus* has emerged as a predominant pathogen in humans with fungal sinusitis and fungal keratitis, especially in immunocompromised patients (8). However, the authors do not have available information about possible *Aspergillus* spp. infection cases among the people of the aviary from where the Eclectus parrot was imported.

Because no other deaths happened in the imported group of parrots, it is believed that further studies using antemortem procedures such as serologic methods to perform immunodiagnosis of *Aspergillus* spp. infection will be useful to know its prevalence in the psittacine collection and will allow early detection of possible cases.

Acknowledgments

We thank Roberto Abán for histotechnical assistance.

References

1. BAUCK, L. Aspergillosis. RITCHIE, BW., HARRISON, GJ., HARRISON, LR., Eds. **Avian Medicine: Principles and Applications**. Lake Worth: Wingers, 1994: 1000-1004.
2. BURR, EW. Enzootic aspergillosis in wild red vented cockatoos in the Philippines. **Mycopathologia**, 1981, 73, 21-28
3. CHARLTON, R., CHIN, RP., BARNES, HJ. Aspergillosis. SAIF, YM., FADLY, AM., GLISSON, JR., MCDUGALD, LR., NOLAN, LK., SWAYNE, DE., Eds. **Diseases of Poultry**. 12 ed. Oxford: Blackwell, 2008: 989-1001.
4. CONVERSE, KA. Aspergillosis. THOMAS, NJ., HUNTER, B., ATKINSON, C., Eds. **Infectious Diseases of Wild Birds**. Ames: Blackwell, 2008: 360-374.
5. FLETCHER, OJ., ABDUL-AZIZ, T., BARNES, HJ. Respiratory system. FLETCHER, OJ., ABDUL-AZIZ, T., Eds. **Avian Histopathology**. 3 ed. Madison: American Association of Avian Pathologists, 2008: 128-163
6. KAPLAN, W., ARNSTEIN, P., AJELLO, L., CHANDLER, F., WATTS, J., HICKLIN, M. Fatal aspergillosis in imported parrots. **Mycopathologia**, 1975, 56: 25-29.
7. KLICH, MA., PITT, JI. **A Laboratory Guide to Common Aspergillus Species and Their Teleomorphs**. North Ryde, New South Wales: Commonwealth Scientific and Industrial Research Organization (CSIRO), Division of Food Processing, 1988.
8. KRISHNAN, S., MANAVATHU, EK., CHANDRASEKAR, PH. *Aspergillus flavus*: an emerging non-fumigatus *Aspergillus* species of significance. **Mycoses**, 2009, 52, 206-222.
9. MARTIN, MP., BOUCK, KP., HELM, J., DYKSTRA, MJ., WAGES, DP., BARNES, HJ. Disseminated *Aspergillus flavus* infection in broiler breeder pullets. **Avian Dis.**, 2007, 51, 626-631.
10. OKOYE, JO., GUGNANI, HC., OKEKE, CN. Pulmonary infections due to *Aspergillus flavus* in turkey poults and goslings. **Mycoses**, 1989, 3, 336-339.
11. REDIG, P. Fungal diseases-aspergillosis. SAMOUR, J., Ed. **Avian Medicine**. 2 ed. St. Louis: Mosby, 2008: 373-387.