



Original Full Article

Infectious muscle necrosis etiology in the Pacific White Shrimp (*Penaeus vannamei*) cultured in Ecuador

José Melena^{1*}, Javier Tomalá², Fanny Panchana¹, Irma Betancourt¹, César Gonzabay¹, Stanislaus Sonnenholzner¹, Yasuji Amano³ & Jean-Robert Bonami⁴

¹Centro Nacional de Acuicultura e Investigaciones Marinas – Escuela Superior Politécnica del Litoral (CENAIM – ESPOL), Campus Gustavo Galindo Velasco, Km 30.5 vía Perimetral, P.O. Box 09-01-5863, Guayaquil, Ecuador

²Universidad Estatal Península de Santa Elena (UPSE), Avenida principal La Libertad – Santa Elena, La Libertad, Ecuador

³Instituto Nacional de Higiene y Medicina Tropical “Leopoldo Izquieta Pérez”, Guayaquil, Ecuador

⁴Pathogens and Environment, UMR 5119 EcoLag cc 093, CNRS/UM2, Place E. Bataillon, 34095 Montpellier Cedex 5, France.

*Corresponding Author: José Melena, Centro Nacional de Acuicultura e Investigaciones Marinas (CENAIM – ESPOL), Campus Gustavo Galindo Velasco, Km 30.5 vía Perimetral, P.O. Box 09-01-5863, Guayaquil, Ecuador. E-mail: jmelena@cenaime.spol.edu.ec

Submitted March 5th 2012, Accepted March 18th 2012

Abstract

In recent years, some Ecuadorian shrimp farmers have reported several cases of muscle necrosis in *P. vannamei* grow out cultures, associated to low mortalities at harvest. This abnormal condition is characterized by focal to extensive necrotic areas in striated tail muscle tissues, displaying a white, opaque appearance. Furthermore, histological analysis from suspected samples with macroscopic lesions revealed a loss of sarcomeric structure accompanied by coagulative muscle necrosis along with hemocytic infiltration. Two viruses, not reported in Ecuador, are described as etiological agents of muscle necrosis in *P. vannamei*: infectious myonecrosis virus (IMNV) and *Penaeus vannamei* nodavirus (PvNV). In this study, the etiology of the muscle necrosis cases found in the Pacific white shrimp *P. vannamei* cultured in Ecuador was examined. This muscle necrosis was hypothesized to be caused by an infectious agent. Three sequential challenge tests, using diseased *P. vannamei* with macroscopic lesions (opaque, whitish discolorations in the abdominal muscles) as starting material (crude inoculum), were carried out. Essentially, histological examination confirmed that most of the challenged shrimp had lesions in skeletal muscle, including multifocal necrosis, fibrocytic inflammation and phagocytosis. In the first trial, 7 challenged shrimp (out of 10) presented multifocal necrosis and hemocytic infiltration in the skeletal muscle. In the second trial, 14 challenged shrimp (out of 20) exhibited coagulative muscle necrosis and hemocytic infiltration. In the third trial, 48 challenged shrimp (out of 69) showed muscle necrosis and hemocytic infiltration. There were no mortalities throughout the all four-week trials. All challenged shrimp tested by RT-PCR assay were negative for IMNV. In our experimental procedures, muscle necrosis could be consistently reproduced through three sequential trials, confirming that the disease has an infectious etiology. Our results suggest that the etiological agent of this disease could be a new infectious agent or a different strain of IMNV.

Key Words: Muscle necrosis, hemocytic infiltration, infectious etiology, *Penaeus vannamei*.

Introduction

Infectious diseases have led to severe mortalities of cultured penaeid shrimp all over the world (11). In Ecuador, the development and sustainability of the cultured white shrimp, *Penaeus vannamei*, has been

threatened by the occurrence of several viral pathogens, mainly Taura syndrome virus (TSV) (5), infectious hypodermal and hematopoietic necrosis virus (IHHNV) (7), and white spot syndrome virus (WSSV) (21). In all cases mentioned, those pathogens were associated to clear,

macroscopic and microscopic changes, which have been widely studied by several researchers (12, 13, 24).

In recent years, some Ecuadorian shrimp farmers have reported several cases of muscle necrosis in *P. vannamei* grow out cultures, associated to low mortalities at harvest (15). This abnormal condition is characterized by focal to extensive necrotic areas in striated tail muscle tissues, displaying a white, opaque appearance. Furthermore, histological analysis from suspected samples with macroscopic lesions revealed a loss of sarcomeric structure accompanied by coagulative muscle necrosis along with hemocytic infiltration.

Similar lesions have been described for two infectious diseases not locally reported: Infectious myonecrosis (IMN) (18) and penaeid white tail disease (PWTd) (14). IMN affecting cultured *P. vannamei* in Brazil is caused by a double-stranded RNA virus that is named infectious myonecrosis virus (IMNV) (18). Meanwhile, PWTd was reported in cultured *P. vannamei* in Belize and its etiological agent is a nodavirus named *Penaeus vannamei* nodavirus (PvNV) (23). In both cases, multifocal necrosis, hemocytic congestion, fibrocytic inflammation, phagocytosis and the appearance of cytoplasmic inclusion bodies are typical histopathological changes in skeletal muscle (22, 23).

Before IMNV and PvNV caused myonecrosis was reported, non-infectious muscle necrosis in shrimp was well known. Among the causes of non-infectious muscle necrosis were physiological stress in response to environmental factors, such as sudden changes in temperature, salinity or dissolved oxygen (10). In our experience, this condition affecting shrimp is largely non-inflammatory. On this matter, several evidences suggested there appeared to be two forms of muscle necrosis in crustaceans, one involving extensive hemocytic infiltration (3, 16), and the other comprising a non-inflammatory necrosis, in which a weak immune reaction is observed (1, 9, 19). In turn, other study (4) suggested that the hemocytic infiltration may occur in response to injury caused by secondary pathogens. Interestingly, an unusual cellular immune response, i.e. hemocytic infiltration was found in local farmed *P. vannamei* with muscle necrosis, suggesting an infectious causation (15).

In this study, the etiology of several muscle necrosis cases found in the Pacific white shrimp *P. vannamei* cultured in Ecuador was examined. This muscle necrosis was hypothesized to be caused by an infectious agent. Three sequential challenge tests (trials), using *P. vannamei* obtained from the CENAIM-ESPOL experimental culture facilities, were carried out. This methodology was considered to generate conclusive evidence of infectious causation.

Material and methods

One batch of healthy *P. vannamei* (n= 400, 7.5 g average weight), was used for inoculum preparation and

bioassays. Previously, randomly selected shrimp from this experimental population (~5%) were preserved in Davidson's fixative and their health status were verified by routine histology following standard methods (2). The shrimp population was kept in one 500-L plastic tank for supplying the experimental hosts during the bioassays. Sea water was filtered to 5 µm and UV sterilized (300000 µWs.cm²). The tank received continuous aeration and was provided with a 10% daily water exchange. Salinity was 35 ppt and water temperature between 27 – 28 °C. Experimental shrimp were fed with artificial feed (Wayne Super U 27%, MOLINOS CHAMPION S.A., Guayaquil – Ecuador).

Starting material for the first challenge test was prepared with 40 diseased shrimp (15 g average weight) from affected grow out ponds, which were preliminary chosen by external signs (opaque, whitish discolorations in the abdominal muscles) and verified by histological analysis later. After removal, soft tissues (pleopods, muscle and gills) were resuspended in five parts of TN buffer (0.02 M Tris-HCl; 0.4 M NaCl, pH 7.4) and then homogenized in a blender at 4 °C. After centrifugation at 10000 g for 10 min at 4 °C (SORVALL Discovery™ 90SE, rotor A-1256), the supernatant was cleared once again at 20000 g for 10 min at 4 °C. Finally, supernatant was centrifuged at 35000 g for 20 min at 4 °C. The pellet was resuspended in 2 mL TN buffer and filtered through a 0.45 µm membrane to produce a crude inoculum, aliquoted and stored at -80 °C until use.

In the first trial, 50 shrimp (8 g average weight) from the experimental population were equally distributed in five 40L glass aquaria. Shrimp were acclimated for three days prior to challenge test. Later, specimens were intramuscularly injected with 150 µL of previously 100-fold diluted crude inoculum. Injection was performed into the 2nd abdominal segment using a sterile 1 mL tuberculin syringe. Inoculated shrimp were maintained in seawater at room temperature (28 °C) for four weeks. When concluded, ten challenged shrimp were histologically analyzed while remaining shrimp were harvested and stored at -80 °C for further analysis.

In the second trial, 100 shrimp (8.5 g average weight) were equally distributed in ten 40L glass aquaria. Eight aquaria were used as treatment (challenge test) and 2 as negative controls. Shrimp were acclimated and starved for 2 days prior to the challenge test. All shrimp belonging to treatment aquaria were fed with minced tissues (muscle and pleopods) obtained from frozen shrimp of the first bioassay, at a feeding rate equivalent to 8% of their mean body weight divided into two rations over 3 days. Later, challenged shrimp were fed with pelleted artificial feed twice daily for 25 days post-challenge. In the case of negative controls a homogenate of healthy shrimp was prepared using approximately 15 g muscle tissues of *P. vannamei* and supplied to both control aquaria at the same rate, dosage and feeding period as treatment groups. When concluded, all challenged shrimp were harvested and

preserved in Davidson's fixative. Their health status post-challenge was tested analyzing 20 randomly selected shrimp by routine histology following standard methods.

In the third trial, 100 experimental shrimp (8,5 g average weight) were tested following the same conditions of the second trial. When concluded, all challenged shrimp were harvested and preserved in Davidson's fixative as above mentioned. Their health status post-challenge was tested analyzing 69 randomly selected shrimp by routine histology following standard methods.

As a complementary analysis, IMNV was tested by reverse-transcriptase polymerase chain reaction (RT-PCR) in challenged shrimp (n= 25) from third trial exhibiting evident muscle necrosis signs. IMNV test was performed using a commercially available kit (IQ2000™ IMNV Detection and Prevention System Kit; GeneReach Biotechnology Corp., Taipei, Taiwan) according to the manufacturer's instructions. Previously, total RNA extraction from muscle tissues was performed using the buffer lysis supplied with the IQ2000™ kit.

Results

In the case of starting material, small pieces of necrotic abdominal segments obtained from diseased shrimp (Fig. 1) cultured in commercial grow out ponds were submitted to histological analysis. The occurrence of skeletal muscle necrosis in the specimens collected was confirmed with the presence of multifocal coagulative necrosis and hemocytic infiltration (Fig. 2).



Figure 1 - Diseased *P. vannamei* shrimp obtained from commercial grow out ponds and used as starting material (inoculum), exhibiting skeletal muscle necrosis as an opaque, whitish, discoloration of several abdominal segments (arrows).

Essentially, histopathological examination confirmed that most of the challenged shrimp had lesions in skeletal muscle, including multifocal necrosis, fibrocytic inflammation and phagocytosis.

In the first trial, 7 challenged shrimp (out of 10) presented multifocal necrosis and hemocytic infiltration in the skeletal muscle (Fig. 3, Table 1).

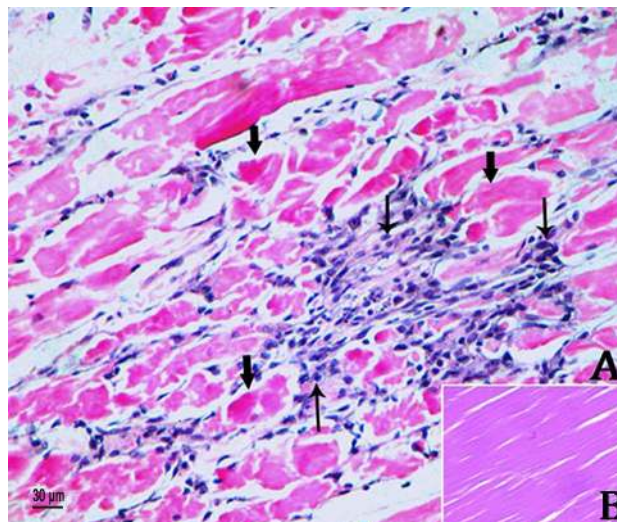


Figure 2 - Multifocal areas of extensive coagulative necrosis and hemocytic infiltration in skeletal muscle obtained from diseased *P. vannamei* shrimp found in commercial grow out ponds and used as starting material (inoculum) for the first trial. A. Coagulative necrosis in skeletal muscle (wide arrows) along with hemocytic infiltration (thin arrows). Extensive loss of abdominal muscle structure. B. Normal skeletal muscle from a healthy shrimp. Mayer-Bennett hematoxylin/eosin-phloxin (H&E) stain.

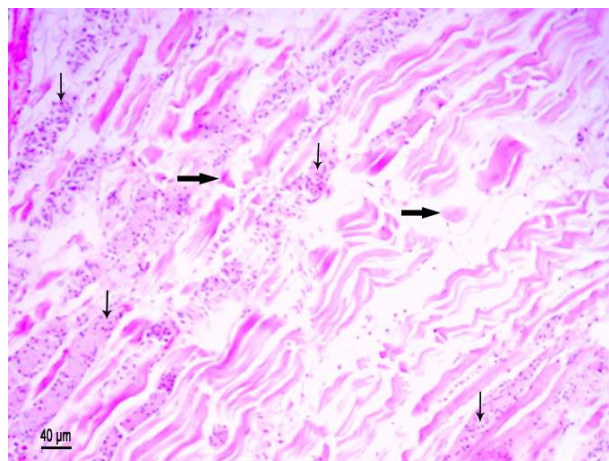


Figure 3 - Histological section with muscle necrosis (wide arrows) and hemocytic infiltration (thin arrows) in experimental *P. vannamei* shrimp challenged by intramuscular injection from trial 1. H&E stain.

In the second trial, 14 challenged shrimp (out of 20) exhibited coagulative muscle necrosis and hemocytic infiltration (Fig. 4, Table 1). At the end of this challenge test, diseased experimental shrimp showed typical, external signs of muscle necrosis (Fig. 5). Five shrimp from negative control were randomly analyzed by histology and no muscle necrosis signs were found (results not shown).

In the third trial, 48 challenged shrimp (out of 69) showed muscle necrosis and hemocytic infiltration (Fig. 6, Table 1). Five shrimp from negative control were randomly analyzed by histology and no muscle necrosis signs were found (results not shown). There were no mortalities throughout the all four-week trials. In addition, there was no evidence of opportunistic bacterial infection in analyzed tissues from all challenged shrimp.

Finally, all challenged shrimp tested by RT-PCR assay were negative for IMNV (Fig. 7, Table 1), showing the presence of one internal control amplicon (house-keeping gene) only.

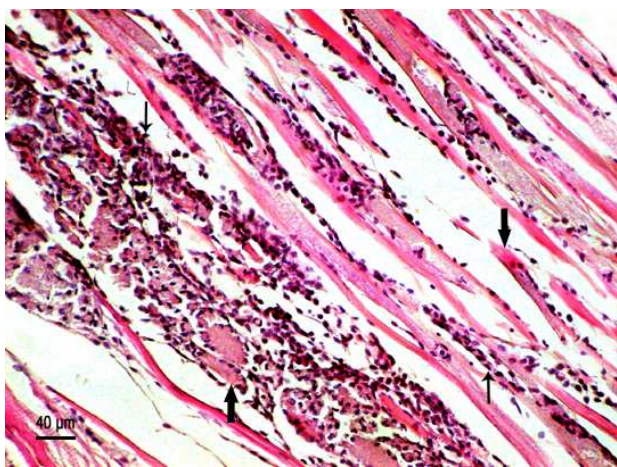


Figure 4 - Histological characteristics of skeletal muscle revealing coagulative muscle necrosis (wide arrows) and hemocytic infiltration (thin arrows) in experimental *P. vannamei* shrimp challenged per os from trial 2. H&E stain.



Figure 5 - Gross signs of typical muscle necrosis observed in challenged *P. vannamei* from trial 3, seen as opaque, whitish discolorations in the tail, with emphasis on the last abdominal segments (arrows).

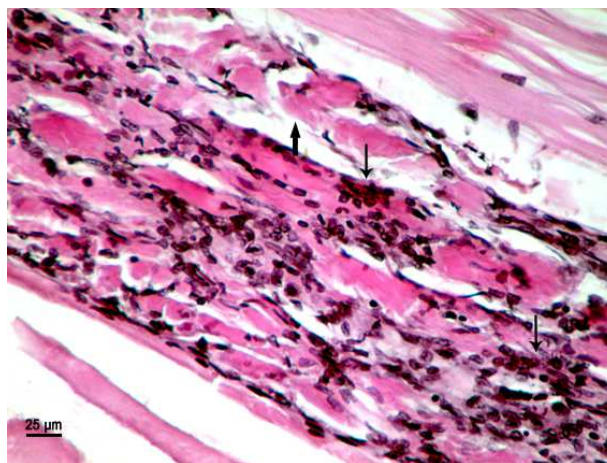


Figure 6 - Section of skeletal muscle showing severe coagulative necrosis (wide arrow) and hemocytic infiltration (thin arrows), with loss of sarcomeric structure, in experimental *P. vannamei* shrimp challenged per os from trial 3. H&E stain.

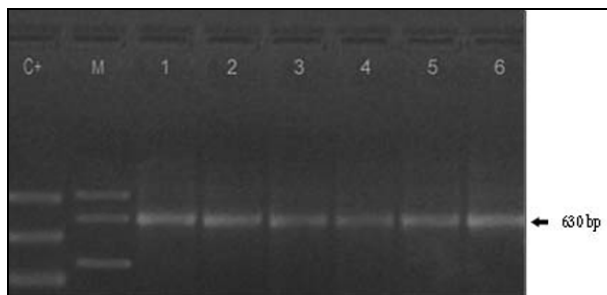


Figure 7 - RT-PCR amplification for IMNV detection by IQ2000™ kit using RNA extracts from challenged *P. vannamei* shrimp from trial 3, seen on ethidium bromide-stained agarose gel. Lane C+: Positive control (positive standard). Lane M: Molecular weight marker (848 bp, 630 bp, 333 bp). Lane 1-6: Individual challenged shrimp showing one 630-bp amplicon corresponding to internal control.

Discussion

Our results, based on macroscopic examination and histopathological analysis of the experimental challenged shrimp, showed that some cases of muscle necrosis found in *P. vannamei* cultured in local grow out systems have an infectious etiology.

In 2006 several signs associated with muscle necrosis were found in cultured *P. vannamei* shrimp from a commercial grow out farm located to the south of Guayas province in Ecuador. Originally identified as a syndrome, original cases of muscle necrosis were represented by diseased shrimp exhibiting white, opaque appearance in abdominal segments, with persistent mortalities reaching up to 30% at harvest (15).

Two typical histopathological changes related to this syndrome were found in the analyzed local samples: muscle necrosis and hemocytic infiltration. Both were similar to those described for 2 infectious diseases not locally reported yet: IMN and PWTD. Although PWTD and IMN are characterized by muscle necrosis, there is a difference in the mortality caused in *P. vannamei*

by their etiological agents: PvNV did not cause any mortality in laboratory-infected *P. vannamei* (23), whilst IMNV caused 20% mortality in similar experimental bioassays (22).

The etiological elucidation of emerging diseases is one of the most relevant issues in the field of aquatic animal health. As a matter of fact, contributions have been done for determining the etiology of several diseases affecting shrimp (5, 6, 17, 18). In general,

pathogenicity assays have been conducted with the aim of fulfilling the Koch's Postulates (8) or Rivers' Postulates (20). Essentially, these guidelines were formulated for proving disease causation by microbes or viruses, including their isolation, culture and experimental transmission. In our experimental procedures, muscle necrosis could be consistently reproduced through three sequential trials, confirming that the disease has an infectious etiology (Table 1).

Table 1: Histopathological and RT-PCR analysis of muscle necrosis in experimental challenged *P. vannamei*

Trial	Challenge method	Number of challenged shrimp	Histology	RT-PCR for IMNV
1	Injection	50	Positive (7/10 ^a)	*
2	<i>Per os</i>	80	Positive (14/20 ^a)	*
3	<i>Per os</i>	80	Positive (48/69 ^a)	Negative (25/25 ^b)

^a Number of positive shrimp / Total number of shrimp tested

^b Number of negative shrimp / Total number of shrimp tested

* Not done

On the other hand, histological lesions found in local diseased shrimp (Figs. 2, 3, 4 & 6) were almost indistinguishable from those reported in *P. vannamei* for IMN and PWD. However, there is a small difference in the histopathological changes, e.g. no cytoplasmic inclusion bodies were observed in skeletal muscle. In spite of this, our results required further confirmation for determining the possible causative agent(s) of this disease, by RT-PCR assay for IMNV detection. On this matter, PvNV has not been detected in samples submitted for diagnosis from farms in Central or South America, except from Belize and an adjacent area of Nicaragua (14).

In addition, shrimp samples from the same bioassays were sent to the University of Arizona Aquaculture Pathology Laboratory (UAZAPL) for IMNV and PvNV detection by RT-PCR, resulting negative for both viruses. The absence of IMNV by RT-PCR in analyzed shrimp harboring muscle necrosis and the lack of mortality registered in our challenge tests suggest that the etiological agent of this disease could be either a new infectious agent or a different strain of IMNV.

Further studies are necessary to elucidate the etiological agent of this muscle necrosis, including the development of specific molecular methods for its detection, and the design of control strategies in order to mitigate its impact in local shrimp farms.

Acknowledgements

This research was supported financially by Escuela Superior Politécnica del Litoral (ESPOL). Mr. Andrés Pedrazzoli and Dr. Samuel Stern are acknowledged for providing the facilities to carry out this work. We are also grateful to Dr. Federico Brown for reading the manuscript and valuable comments. Finally, we thank to scientific staff of CENAIM-ESPOL for their collaboration during this investigation.

References

- AKIYAMA DM., BROCK JA., HALEY SR. Idiopathic muscle necrosis in the cultured fresh water prawn (*Macrobrachium rosenbergii*). **Vet. Med. Sm. Anim. Clin.**, 1982, 77, 1119-1121.
- BELL TA., LIGHTNER DV. A Handbook of Normal Shrimp Histology. World Aquaculture Society, Baton Rouge, Louisiana, 1988.
- CHENG W., CHEN JC. Isolation and characterisation of an Enterococcus-like bacterium causing muscle necrosis and mortality in *Macrobrachium rosenbergii* in Taiwan. **Dis. Aquat. Organ.**, 1998, 34, 93-101.
- EVANS LH., FOTEDAR S., FAN A., JONES B. Investigation of idiopathic muscle necrosis and circulating haemocytes in the freshwater crayfish *Cherax tenuimanus* to acute and chronic stressors. **Freshwater Crayfish**, 1999, 12, 356.
- HASSON KW., LIGHTNER DV., POULOS BT., REDMAN RM., WHITE BL., BROCK JA., BONAMI JR. Taura Syndrome in *Penaeus vannamei*: demonstration of a viral etiology. **Dis. Aquat. Organ.**, 1995, 23, 115-26
- HASSON KW., WYLD EM., FAN Y., LINGSWELLER SW., WEAVER SJ., CHENG J., VARNER PW. Streptococcosis in farmed *Litopenaeus vannamei*: a new emerging bacterial disease of penaeid shrimp. **Dis. Aquat. Organ.**, 2009, 86, 93-06.
- JIMÉNEZ R., BARNIOL R., DE BARNIOL L., MACHUCA M. Infection of IHNV virus in two species of cultured penaeid shrimp *Litopenaeus vannamei* (Boone) and *Litopenaeus stylirostris* (Stimpson) in Ecuador during El Niño 1997-98. **Aquac. Res.**, 1999, 30, 695-05.
- KOCH R. Ueber bakteriologische Forschung. Verhandlungen des X Internationalen Medicinischen Congresses, Berlin, 1890, 1, 35, **August Hirschwald, Berlin**. 1891.
- LAKSHMI GJ., VENKATARAMIAH A., HOWSE HD. Effect of salinity and temperature changes on spontaneous muscle necrosis in *Penaeus aztecus* Ives. **Aquaculture**, 1978, 13, 35-43.

10. LIGHTNER DV. Muscle necrosis of penaeid shrimp. In: Sindermann CJ, Lightner DV (eds). **Disease diagnosis and control in north America marine aquaculture. Developments in Aquaculture and Fisheries Science, Vol 17.** Elsevier Press, New York, 1988, 122-24.
11. LIGHTNER DV. The penaeid shrimp viruses TSV, IHHNV, WSSV and YHV: current status in the Americas, available diagnostic methods and management strategies. **J. Appl. Aquaculture**, 1999, 9, 27-52.
12. LIGHTNER DV., REDMAN RM., BELL TA. Infectious hypodermal and hematopoietic necrosis, a newly recognized virus disease of penaeid shrimp. **J. Invertebr. Pathol.**, 1983, 42, 62-70.
13. LIGHTNER DV., REDMAN RM., HASSON KW., PANTOJA CR. Taura syndrome in *Penaeus vannamei*: histopathology and ultrastructure. **Dis. Aquat. Organ.**, 1995, 21, 53-59.
14. LIGHTNER DV., PANTOJA C., REDMAN RM., NOBLE B., SCHOFIELD P., TANG KFJ. White tail disease in shrimp mimics Infectious myonecrosis. **Global Aquaculture Advocate**, 2008, May-June, 44-45.
15. MELENA J. Estudio de la etiología de la necrosis muscular en camarón cultivado *Penaeus vannamei* en Ecuador. **Aquacultura**, 2007, 64, 42-46.
16. MOMOYAMA K., MATSUZATO T. Muscle necrosis of the culture kuruma shrimp (*Penaeus japonicus*). **Fish Pathol.**, 1987, 22, 69-75.
17. NUNAN LM., LIGHTNER DV., ODOURI MA., GASPARICH GE. *Spiroplasma penaei* sp. nov., associated with mortalities in *Penaeus vannamei*, Pacific white shrimp. **Int. J. Syst. Bacteriol.**, 2005, 55, 2317-22.
18. POULOS BT., TANG KFJ., PANTOJA RC., BONAMI JR., LIGHTNER DV. Purification and characterization of infectious myonecrosis virus of penaeid shrimp. **J. Gen. Virol.**, 2006, 87, 987-96.
19. RIGDON RH., BAXTER KN. Spontaneous necrosis in muscles of brown shrimp *Penaeus aztecus* Ives. **T. Am. Fish. Soc.**, 1970, 3, 383-387.
20. RIVERS TM. Viruses and Koch's Postulates. **J. Bacteriol.**, 1937, 33, 1-12.
21. RODRÍGUEZ J., BAYOT B., AMANO Y., PANCHANA F., DE BLAS I., ALDAY V., CALDERÓN J. White spot syndrome virus infection in cultured *Penaeus vannamei* (Boone) in Ecuador with emphasis on histopathology and ultrastructure. **J. Fish Dis.**, 2003, 26, 439-50.
22. TANG KFJ., PANTOJA RC., POULOS BT., REDMAN RM., LIGHTNER DV. In situ hybridization demonstrates that *Litopenaeus vannamei*, *L. stylirostris* and *Penaeus monodon* are susceptible to experimental infection with infectious myonecrosis virus (IMNV). **Dis. Aquat. Organ.**, 2005, 63, 261-5.
23. TANG KFJ., PANTOJA RC., REDMAN RM., LIGHTNER DV. Development of in situ hybridization and RT-PCR assay for the detection of a nodavirus (PvNV) that causes muscle necrosis in *Penaeus vannamei*. **Dis. Aquat. Organ.**, 2007, 75, 183-90.
24. WONGTEERASUPAYA C., VICKERS JE., SRIURAIRATANA S., NASH GL., FLEGEL TW. A non-occluded, systemic baculovirus that occurs in cells of ectodermal and mesodermal origin and causes high mortality in the black tiger prawn *Penaeus monodon*. **Dis. Aquat. Organ.**, 1995, 21, 69-77.