



Case Report

Nasal Amyloidosis in a Horse

Roseane A. Portela¹, Antônio Flávio M. Dantas¹, Diego Barreto de Melo¹, Josemar Medeiros Marinho¹, Pedro Isidro da Nóbrega Neto¹, Franklin Riet-Correa^{1*}.

¹ Hospital Veterinário, CSTR, Universidade Federal de Campina Grande, Patos, PB, 58708-110.

*Corresponding author: Franklin Riet-Correa E-mail: franklin.riet@pq.cnpq.br

Submitted July 4th 2012, Accepted July 21st 2012

Abstract

A 16-year-old Quarter Horse was admitted to the Veterinary Hospital after recurrent epistaxis episodes. Dyspnea and intolerance to exercise were noticed. An irregular multinodular mass was observed in the mucosa of the rostral nasal cavity, causing partial stenosis of the anterior airways. To improve the respiratory condition of the animal, most of the mass was surgically removed. Histologic examination revealed eosinophilic hyaline material in the lamina propria, walls of submucosal lymphatic and blood vessels, and basement membrane of mucosal glands of the nasal cavity. This material stained orange-red with Congo-red, with the characteristic green birefringence under polarizing light, confirming the amyloid diagnosis. Giant cells and mononuclear cell infiltrate were also observed. One year after the partial removal of the lesion, the horse had only mild respiratory signs.

Key Words: type AL amyloidosis, horse, nasal cavity, Paraíba, Northeastern Brazil

Introduction

Amyloidosis is a group of diseases of protein metabolism characterized by the deposition of extracellular amyloid protein in tissues. It can be primary or secondary to other pathologies, and is classified into different types, depending on the amyloid-forming protein (1-5). In horses, amyloidosis can be either systemic or localized. The most common systemic amyloidosis in this species, mainly in horses used for serum production, is secondary (reactive) amyloidosis, due to chronic inflammatory diseases, in which the amyloid apoprotein (AA) derived from serum amyloid A (SAA) protein is deposited (2, 7). Systemic AL amyloidosis is rare in horses. Localized amyloidosis is more common, and the amyloid in these cases appears to be the AL type mainly (3). At least ten cases of idiopathic amyloidosis of the nasal cavity have been reported in the last 25 years (10, 11, 12, 14, 16). In one of these cases, amyloid was also deposited in the conjunctiva (11). Three cases of localized cutaneous amyloidosis were reported; one of unknown cause (17) and two others associated with lymphohistiocytic lymphosarcoma (18) and

extramedullary plasmacytoma (9). Localized cardiac amyloidosis of unknown cause has also been reported (13). One case of nasal amyloidosis was reported in the state of Rio de Janeiro, Southeastern Brazil (16).

In nasal amyloidosis, deposition is characterized by either nodular or diffuse thickening of the nasal vestibulum, anterior septum and turbinates (1, 8), occasionally resulting in stenosis which can be severe enough to cause signs of nasal obstruction (1). The amyloid is recognized microscopically by the green birefringence observed in Congo red-stained tissue specimens under polarized light. AA and AL amyloid can be distinguished by potassium permanganate treatment of tissue sections; AL amyloid is resistant, but AA amyloid is oxidized with subsequent loss of its Congo red stain (6). The amyloid is deposited in the connective tissue, blood vessels and basal membrane of the submucosal glands, associated with the presence of giant cells, lymphocytes and macrophages (1,12,14). The aim of this paper is to report a new case of nasal amyloidosis in a horse in Brazil.

Case Report

In April 2009, a 16 year-old Quarter horse from

the municipality of Itaporanga in the State of Paraíba was admitted at the Veterinary Hospital after recurrent episodes of epistaxis one year long. The animal has been used for vaquejada, a sport of Northeastern Brazil, which consists in knocking a bovine over by pulling its tail. Clinically the animal showed inspiratory dyspnea with dilated nostrils, difficult respiration, and intolerance to exercise. The respiratory rate during resting was 32 movements per minute. An irregular bilateral mass with multinodular, smooth, shiny and reddish, non-ulcerated surface, and firm and elastic consistency was detected in the mucosa of the rostral nasal cavity (Figure 1), causing partial stenosis of the anterior airways. After bilateral infraorbital nerves block with 10 mL of 2% lidocaine per foramen, much of the mass was surgically removed to improve the respiratory condition of the animal. Samples of the mass were fixed in 10% buffered formalin, embedded in paraffin, sectioned at 4-6 µm, and stained with hematoxylin and eosin. Selected sections were also stained with Congo red and observed under polarized light. Other samples were cultivated in agar agar and 2% Sabouraud agar and incubated at 30°C during 24 to 96 hours.

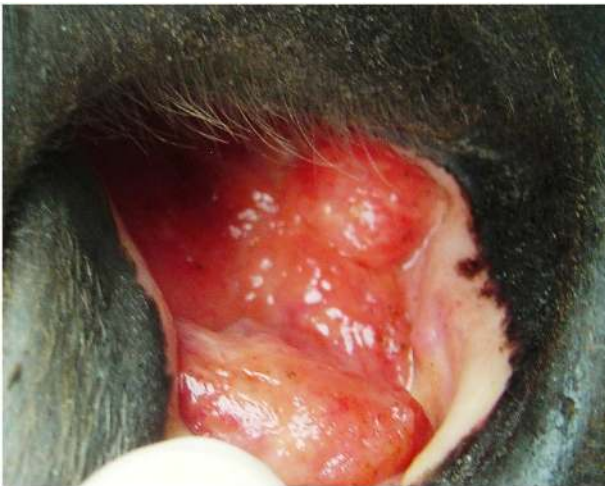

Figure 1. Mass with multinodular, smooth, shiny and reddish, non-ulcerated surface in the nasal mucosa of a Quarter horse.

On histological examination the lamina propria and walls of lymphatic vessels and glands of the nasal cavity were distended by rounded masses of eosinophilic hyaline material (Figure 2). Similar material was observed also, in linear arrays, under the hyperplastic nasal epithelium. Numerous giant cells were bordering the nodular masses and calcification was observed in the center of some of these structures. Mononuclear cell infiltrate was also observed around the glands. The deposited material stained orange red with Congo red, with the characteristic green birefringence under polarizing light, confirming the amyloid diagnosis. No bacterial or fungal growth was observed in the cultures. One year after the surgical removal of part of the lesion, the horse had only mild respiratory signs and the lesion did not progress.

The diagnosis was based on clinical history and confirmed by histopathology. There was no association with

any other pathology. In the few cases of localized nasal amyloidosis in horses the specific cause is unknown and there are no concurrent diseases (12, 14, 16). Idiopathic nasal amyloid deposition is not part of widespread amyloidosis, although it can occur simultaneously with cutaneous amyloidosis (1). In this report an old Quarter Horse was affected; for amyloidosis there is no predilection for race, gender, and age, or familial tendency (12, 16). The gross and histologic lesions observed in this case are similar to those reported previously (8, 12), although there was no mucosal ulceration, as mentioned in other reports (12, 14, 16). Histological examination is always necessary to diagnose nasal amyloidosis (16). Also in this case the lesion was located in the anterior nasal cavity favoring the survival of the animal. One year after the surgical removal of part of the lesion the animal is in stable condition, but is no longer used for training. Deposits extending into the pharynx and epiglottis, as noted in two horses by Shaw et al. (14), prevent the respiratory function and the animals must be euthanized.

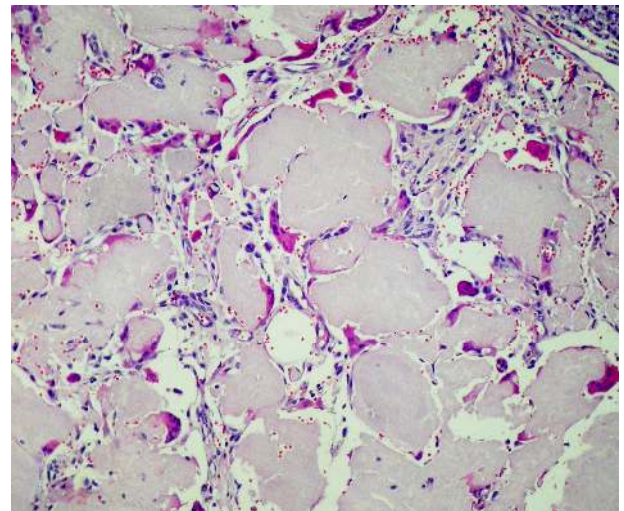


Figure 2. Lamina propria of the nose showing multifocal deposition of a hyaline substance. The foci are surrounded by few giant cells and lymphoplasmacytic exudate. HE stain, Obj 40x.

The clinical differential diagnosis of amyloidosis includes nasal fungal granulomas caused by *Aspergillus* spp., *Cryptococcus* spp., *Rhinosporidium* spp. and *Conidiobolus* spp, ethmoid hematoma, glanders, nasal polyps, dental tumors of the maxilla eroding into the nasal cavity, and other tumors (14; 16; 19), including fibrosarcoma (4; 15).

References

1. CASWELL JL., WILLIAMS KJ. Respiratory system. In: **Jubb, Kennedy and Palmer's Pathology of Domestic Animals**. St. Louis: Saunders, 2007, 523-653.
2. HAWTHORNE TB, BOLON B, MEYER DJ. Systemic amyloidosis in a mare. **J. Am. Vet. Med. Ass.**, 1990, 2, 323-325.

3. HAYDEN DW, JOHNSON KH, WOLF CB, WESTERMARK P. AA amyloid-associated gastroenteropathy in a horse. **J. Comp. Pathol.**, 1988, 2, 195-204.
4. HEAD KW, DIXON PM. Equine nasal and paranasal sinus tumors. Part 1: Review of the literature and tumor classification. **The Vet. Journal.** 1999, 157, 261-278.
5. HUSBY G. Classification of amyloidosis. **Baillire's Clin. Rheumatol.** 1994, 8, 503-511.
6. HUSBY G. Equine amyloidosis. **Eq. Vet. J.**, 1998, 20, 235-238.
7. KIM DY, TAYLOR HW, EADS SC, CHO D. Systemic AL amyloidosis associated with multiple myeloma in a horse. **Vet. Pathol.**, 2005, 42, 81-84.
8. KNOTTENBELT DC., PASCOE RR. **Diseases and disorders of the horse.** London: Mosby-Wolfe, 1994. 432p
9. LINKE RP., GEISEL O., MANN K. Equine cutaneous amyloidosis derived from an immunoglobulin lambda-light chain. Immunohistochemical, immunochemical and chemical results. **Biol. Chem. Hoppe-Seyler.** 1991, 372, 835-843.
10. LINKE RP., TRAUTWEIN G. Immunoglobulin lambda-light-chain-derived amyloidosis (A lambda) in two horses. **Blut**, 1989, 58, 129-132.
11. MOULD JR, MUNROE GA, ECKERSALL PD. Conjunctival and nasal amyloidosis in a horse. **Eq. Vet. J.**, 1990, 10, 8-11.
12. NAPPERT G, VRINS A, DORE M, MORIN M, BEAUREGARD M. Nasal amyloidosis in two quarter horses. **Can. Vet. J.**, 1988, 29, 834-835.
13. NOUT YS, HINCHCLIFF KW, BONAGURA JD, MEURS KM, PAPPENFUSS TL. Cardiac Amyloidosis in a Horse. **J. Vet. Int. Med.**, 2003, 17, 588-592.
14. SHAW DP, GUNSON DE, EVANS LH. Nasal amyloidosis in four horses. **Vet. Pathol.**, 24,183-185.
15. SILVA LCLC, OLIVEIRA SLP, BORJA MC, BACCARIN RYA. Fibrossarcoma em cavidade oral de equino: relato de caso. Available in <http://www.abraveq.com.br/artigos>. Access on July 10 2009.
16. TROTTE MNS, SANTOS IB, MIRANDA LHM, AMORIN AR, BORGES JRJ, MENEZES RC. Histopatologia de lesões tumoriformes presentes na cavidade nasal de equídeos do Brasil. **Ciência Rural.** 2008, 38, 2535-2539.
17. VALENTINE BA. Equine cutaneous non-neoplastic nodular and proliferative lesions. **Vet. Dermatol.** 2005, 16, 425-428.
18. VAN ANDEL ACJ. Amyloid in the horse: a report of nine cases. **Eq. Vet. J.**, 1988, 20, 277-285.
19. ZOPPA ALV. Obstrução nasal por granuloma fúngico em equino: relato de caso. **Arq. Bras. Med. Vet.**, , 2008, 60, 315-321.