



## Case Report

# Tracheitis in a Broiler Chicken Flock Caused by Dual Infection with *Cryptosporidium* spp. (Apicomplexa: Cryptosporiidae) and Non-hemolytic *Ornithobacterium rhinotracheale*

Carlos D. Gornatti Churria<sup>1\*</sup>, Pablo L. Sansalone<sup>2</sup>, Mariana A. Machuca<sup>3</sup>, Germán B. Vigo<sup>4</sup>, Guillermo H. Sguazza<sup>5</sup>, Javier A. Origlia<sup>1</sup>, Miguel V. Píscopo<sup>1</sup>, Miguel A. Herrero Loyola<sup>1</sup>, Miguel A. Petrucci<sup>1</sup>

<sup>1</sup>Cátedra de Patología de Aves y Pilíferos y Laboratorio de Diagnóstico de Enfermedades de las Aves y los Pilíferos, Facultad de Ciencias Veterinarias, Universidad Nacional de La Plata, FCV - UNLP, La Plata, Argentina, <sup>2</sup>Vetanco S.A, Argentina, <sup>3</sup>Cátedra de Patología Especial, FCV - UNLP, <sup>4</sup>Laboratorio de Diagnóstico e Investigaciones Bacteriológicas, FCV - UNLP, <sup>5</sup>Cátedra de Virología, FCV- UNLP

\* **Corresponding Author:** Carlos D. Gornatti Churria, Cátedra de Patología de Aves y Pilíferos y Laboratorio de Diagnóstico de Enfermedades de las Aves y los Pilíferos, + 54 221 483 4237, Facultad de Ciencias Veterinarias, calle 60 y 118 s/n, CC 296 B 1900 AVW, Universidad Nacional de La Plata, La Plata, Argentina. E-mail: [danielgornatti@fcv.unlp.edu.ar](mailto:danielgornatti@fcv.unlp.edu.ar)

Submitted June 17<sup>th</sup> 2012, Accepted June 28<sup>th</sup> 2012

## Abstract

Broiler chickens aged 41-day-old from a flock of a broiler complex, presenting depression, reduced food intake, facial edema, dyspnea, gasping, sneezing, and 5% mortality were studied. At necropsy, opaque thoracic and abdominal air sacs and mucous tracheal content were observed. Histopathology of tracheas showed multifocal hyperplasia of mucosa with a large number of small, round and ovoid basophilic organisms on their surface, which were identified as *Cryptosporidium* spp. In addition, there was an inflammatory response due to infiltration of mononuclear cells and heterophils in the submucosa. Small pin-point colonies without hemolytic activity were isolated from tracheal samples and identified as *Ornithobacterium rhinotracheale* by conventional and real time polymerase chain reaction (PCR). Results of tracheal histopathology, bacteriology, and PCR identification provided the diagnosis of tracheal cryptosporidiosis associated with non-hemolytic *O. rhinotracheale* secondary infection. This report describes the unusual dual infection with *Cryptosporidium* spp. and non-hemolytic *O. rhinotracheale* causing tracheitis in broiler chickens.

**Key Words:** *Cryptosporidium* spp., non-hemolytic *Ornithobacterium rhinotracheale*, tracheitis, broiler chickens.

## Introduction

Tracheitis in poultry can be caused by infectious agents and/or non-infectious conditions such as exposure to ammonia, the most common aerolized chemical agent involved in poultry houses (4, 16). Histological evidence of injuries of the respiratory epithelium in birds includes loss of cilia, cell degeneration, necrosis, hyperplasia or metaplasia, infiltration of inflammatory cells and hypertrophy and/or hyperplasia of mucous glands (4, 5, 6). Some diseases such as Newcastle disease, infectious bronchitis, infectious laryngotracheitis, fowl pox, *Mycoplasma gallisepticum* infections, and

*Cryptosporidium* spp. infections cause histopathological changes in the trachea of poultry. Newcastle disease and infectious bronchitis are associated with an increased thickness of the mucosa and general absence of mucous glands and cilia; infectious laryngotracheitis is related to the presence of syncytial cells and intranuclear inclusion bodies in epithelial cells; fowl pox causes hyperplasia, pustule formation, and intracytoplasmic inclusion bodies in epithelial cells; *Mycoplasma gallisepticum* infections are related to diffuse lymphofollicular reactions in an expanded tracheal mucosa, and *Cryptosporidium* spp. infections cause loss of cilia and hyperplasia of epithelial cells (4, 5, 6). Other infectious agents such as

*Ornithobacterium rhinotracheale* are known to be involved in outbreaks of respiratory disease causing severe tracheitis in turkeys and broiler chickens (18).

This report describes for the first time a case of tracheitis caused by the unusual dual infection with *Cryptosporidium* spp. and non-hemolytic *O. rhinotracheale* in a broiler chicken flock.

## Material and methods

### Case report

A 41-day-old broiler chicken flock composed of 80,000 birds belonging to a broiler complex located in Buenos Aires Province, Argentina, was studied by poultry veterinarians because signs including depression, reduced food intake, facial edema, dyspnea, gasping, sneezing, and 5% mortality had been observed. In addition, poor conditions of the litter and high levels of ammonia were noticed. Lung, tracheal, and air sac samples and serum samples were collected and submitted to the Laboratorio de Diagnóstico de Enfermedades de las Aves y los Pilíferos (Cátedra de Patología de Aves y Pilíferos, Facultad de Ciencias Veterinarias, Universidad Nacional de La Plata, La Plata, Argentina) in August 2011.

### Pathology

The *postmortem* examination of 20 carcasses showed opaque thoracic and abdominal air sacs and moderate mucous content in tracheas; however no lesions were seen in the lungs. Tracheal, lung and air sacs tissue samples were fixed in 10% buffered formalin, dehydrated in graded alcohol, cleared in xylene, embedded in paraffin, sectioned at approximately 4 µm, and stained with hematoxylin and eosin (H&E) for histopathological studies.

### Bacterial isolation

Lung and tracheal samples were inoculated onto Mac Conkey's agar plates (Agar Mac Conkey, Laboratorios Britania S.A., Buenos Aires, Argentina) and incubated aerobically at 37°C for 24 hours and onto 10% defibrinated goat blood agar (Agar Nutritivo, Laboratorios Britania S.A.) with the addition of 5 µg/ml gentamicin (GENTA G, Laboratorio Vetué, Santa Fé, Argentina) and incubated at 37°C in a candle jar for 48 hours. After incubation, blood agar plates were evaluated for the presence of hemolytic activity caused by the growth of *O. rhinotracheale*, as previously reported (9). Solid Frey's medium was used for the isolation of Mycoplasma spp. and was incubated at 37°C for 7 days.

### Antimicrobial susceptibility

The disc diffusion method was performed to test *in vitro* antibiotic sensitivity as previously described (9), using the following antibiotics: ampicillin (Laboratorios Britania S. A.), chlortetracycline (Vetanco S. A., Buenos Aires, Argentina), doxycycline (Vetanco S. A.), enrofloxacin (Vetanco S. A.), erythromycin (Laboratorios Britania S. A.), fosfomicin (Laboratorios Britania S. A.), florfenicol (Vetanco S. A.), gentamicin (Laboratorios Britania S. A.), and trimethoprim-sulfa (Vetanco S. A.).

### Inoculation of chicken embryos

A filtered suspension made from tracheal, lung and air sacs samples from the broiler chicken flock studied was inoculated into specific pathogen free 11-day-old developing chicken embryos by the allantoic cavity and chorioallantoic membrane routes, following standard methods (15). The study was carried out to detect the possible presence of respiratory viruses such as Newcastle disease virus, infectious bronchitis virus, fowl pox virus, and laryngotracheitis virus. At 24 hours post-inoculation, the dead embryonated eggs were discarded. The rest of the chicken embryos were checked for 7 days in case of possible viability changes. Both allantoic fluid and chorioallantoic membranes were harvested in sterile conditions and four serial passages were made using both routes.

### Serology

Commercially available enzyme-linked immunosorbent assays (ELISAs) were used to detect antibodies against infectious bursal disease (IDEXX IBDAb test, IDEXX Laboratories, Inc., Westbrook, ME, USA), chicken anemia virus (IDEXX CAV Ab test, IDEXX Laboratories, Inc.), Newcastle disease virus (IDEXX NDV Ab test, IDEXX Laboratories, Inc.), infectious bronchitis virus (IDEXX IBV Ab Test, IDEXX Laboratories, Inc.), and avian metapneumovirus (IDEXX APV Ab Test, IDEXX Laboratories, Inc.), following the manufacturer's instructions. In addition, serum plate agglutination tests were carried out by using *M. gallisepticum* antigen (BioVac Laboratoire, Beaucauzé, France) and *M. synoviae* antigen (BioVac Laboratoire) for the detection of serological responses against avian pathogenic mycoplasmas.

### DNA extraction and PCR identification

DNA was extracted from pin-point colonies isolated in blood agar plates with gentamicin by using a DNA commercial extraction kit (DNeasy® Blood & Tissue Kit, QIAGEN GmbH, Hamburg, Germany) according to the manufacturer's instructions. *Ornithobacterium rhinotracheale* was identified by real time and conventional PCR procedures, as previously described (9).

## Results and Discussion

As a result of bacterial isolation, neither *Mycoplasma* spp. nor enterobacteria were isolated on appropriate media. However, small pin-point colonies showing no hemolytic activity after the 48 hour-period following incubation in 10% goat blood agar plates with gentamicin were isolated from tracheal samples. *Ornithobacterium rhinotracheale* was identified by real time and conventional PCR. No differences were seen between the melting temperatures of the non-hemolytic field strain obtained from tracheal samples in the present study, and the  $\beta$ -hemolytic field strains of our previous report (9), which were isolated from pneumonic lungs (86.2°C). Conventional PCR showed high similarity between the molecular weight of the PCR products of the non-hemolytic tracheal strain of this study and the ATCC 51463 control strain of *O. rhinotracheale* (784 bp).

*In vitro* antimicrobial sensitivity tests of the non-hemolytic *O. rhinotracheale* field strain showed resistance against enrofloxacin, fosfomicin, trimethoprim-sulfa, and gentamicin and susceptibility against ampicillin, chlortetracycline, doxycycline, erythromycin, and florfenicol. Despite the natural resistance of *O. rhinotracheale* to gentamicin and polymyxin B (19), and because of the absence of treatment strategies to control this bacterium, further *in vitro* antimicrobial sensitivity studies considering hemolytic and non-hemolytic field isolates of *O. rhinotracheale* will be useful. Moreover, the spread of this agent among the principal areas of broiler production remains unknown in Argentina.

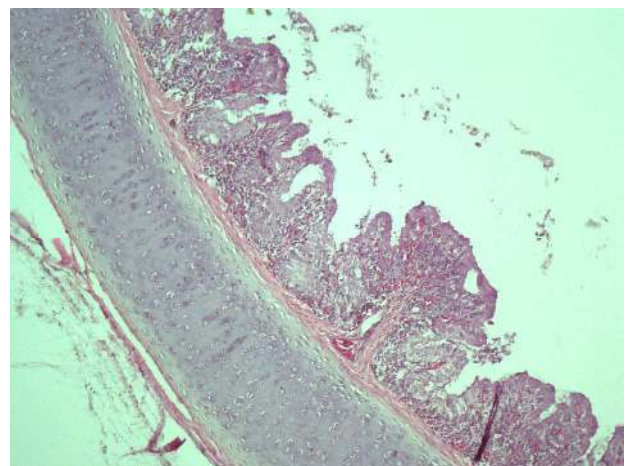
Because no pathological findings were observed in the inoculated chicken embryos after the fourth serial passage, we assumed that there were no viral agents involved in the lesions of respiratory tissues in field conditions.

The serum plate agglutination tests revealed no positive reactions to the presence of antibodies against *M. gallisepticum* and *M. synoviae*, and ELISA results provided no diagnosis of field infections associated with the viral agents tested.

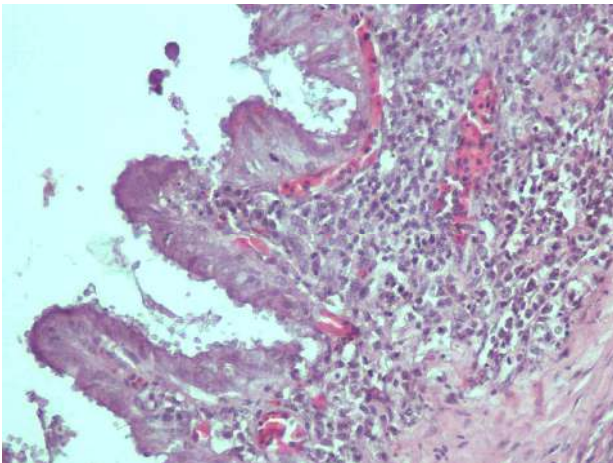
The histopathological study of tracheal sections showed an increased thickness of the mucous membrane due to multifocal hyperplasia (Fig. 1). Degenerated and necrotic epithelial cells of the mucosa, hypertrophic mucous glands and absence of cilia were seen. A large number of round and ovoid basophilic bodies (4–6  $\mu$ m in diameter) were observed by H&E staining adhered to the apical surface of the hyperplastic tracheal epithelium. Also, in the mucosal layer an inflammatory cell response composed of mononuclear cells such as lymphocytes and plasmocytes and heterophils was observed (Fig. 2). According to previous histopathological descriptions (5, 10), the morphology of the organisms observed in tracheal sections were suggestive of *Cryptosporidium* spp infection. Although few necrotic areas and foci of

mononuclear inflammatory response were seen within air sacs, both air sacs and lung tissues did not show either the protozoan parasite or bacterial colonies.

Cryptosporidiosis, which is caused by protozoan parasites of the genus *Cryptosporidium* (11), is one of the most prevalent parasitic infections in domesticated birds (14). In poultry, *Cryptosporidium* spp. is detected in the conjunctiva, sinus, trachea, lungs, kidneys, small and large intestine, cloaca, and bursa of Fabricius (4, 5, 7, 8, 10, 14, 17), and it is a primary pathogen that can cause morbidity and mortality (11, 17). Cryptosporidiosis is present as respiratory, enteric or renal disease in broiler chickens but the respiratory disease is the most common form of cryptosporidiosis, causing high economic losses in the broiler industry (1, 14). Respiratory cryptosporidiosis could be found without bacterium infection (8), but because of the disruption of the mucociliary system, *Escherichia coli* infection is the most prevalent secondary invasion (7, 11). In contrast to usual respiratory cryptosporidiosis, where tracheal and bronchial colonization is known to be concomitant with pneumonia and airsacculitis in poultry (11), *Cryptosporidium* spp. organisms in the present case were found only in tracheal sections and were considered as the cause of severe parasitic tracheitis. Moreover, the increased susceptibility to secondary respiratory diseases of chickens infected by *Cryptosporidium* spp. has also been attributed to the immunosuppressive effect caused by the protozoan parasite (13). Together with the result of bacterial isolation, our pathological study indicates that the isolated *O. rhinotracheale* strain was related to cryptosporidiosis in this case.



**Figure 1.** Section of a 41-day-old broiler chicken trachea showing inflammation and severe multifocal epithelial hyperplasia of the mucosa. H&E, 100 X..



**Figure 2.** Section of a 41-day-old broiler chicken trachea showing numerous ovoid to rounded basophilic organisms measuring 4–6  $\mu\text{m}$  in diameter adhered on the epithelial apical surface compatible or suggestive of *Cryptosporidium* spp. Also, lymphocytes and plasmacytes could be seen in the mucosa. H&E, 400 X.

Although ammonia levels were not measured at the moment of tissue and serum sampling, excess of ammonia associated with poor litter conditions were noticed by field veterinarians. Because exposure to ammonia causes reduced weight gain, poor feed conversion, and even mortality during brooding of chickens (12), we believe that this environmental factor not only was involved in the development of clinical signs but also triggered the injury of the respiratory system and facilitated the secondary bacterial infection caused by non-hemolytic *O. rhinotracheale*.

Because the serological studies performed in this work revealed no signs of respiratory or immunosuppressive infections and because we were not able to isolate avian mycoplasmas or other bacteria different from *O. rhinotracheale*, we believed that the lesions observed in tracheas were caused by *Cryptosporidium* spp., which predisposed to a non-hemolytic *O. rhinotracheale* secondary infection. Thus, the secondary role played by *O. rhinotracheale* isolated in this case causing tracheitis in field conditions is not associated with the absence of hemolytic activity found *in vitro*.

Although it is known that *O. rhinotracheale* is related to other respiratory pathogens of poultry such as *E. coli*, *Bordetella avium*, Newcastle disease virus, infectious bronchitis virus, avian metapneumovirus, *M. synoviae*, and *Chlamydophila psittaci* (3, 19), dual infection with tracheal cryptosporidiosis and *O. rhinotracheale* had not been previously reported.

This work describes for the first time the unusual association between non-hemolytic *O. rhinotracheale* and *Cryptosporidium* spp. infections causing tracheitis in broiler chickens.

Further experimental *O. rhinotracheale* infection using a broiler chicken model and different administration routes to compare the pathogenicity of non-hemolytic and hemolytic field isolates will be valuable to know whether the *in vitro* hemolytic activity is associated with severe clinical signs and lesions.

#### Acknowledgements

We thank Dr. Florencia Pantozzi from Laboratorio de Diagnóstico e Investigaciones Bacteriológicas, Facultad de Ciencias Veterinarias, Universidad Nacional de La Plata for professional assistance and Roberto Abán for histotechnical assistance. We also thank Prof. Dr. Carlos Perfumo, PhD from Cátedra de Patología Especial, Facultad de Ciencias Veterinarias, Universidad Nacional de La Plata, and Yu Yamamoto, DVM, PhD from National Institute of Animal Health, Tsukuba, Japan, for reviewing the manuscript and for valuable comments.

#### References

1. BLAGBURN, BL., LINDSAY, DS., HOERR, FJ., DAVIS, JF., GIAMBRONE, JJ. Pathobiology of cryptosporidiosis (*C. baileyi*) in broiler chickens. **J. Protozool.**, 1991, 38, 25S-28S.
2. CHIN, RP., CHARLTON, BR. Ornithobacteriosis. DUFOUR-ZAVALA, L., SWAYNE, DE., GLISSON, JR., PEARSON, JE., REED, WE., JACKWOOD, MW., WOOLCOCK, PR., Eds. **A Laboratory Manual for the Isolation, Identification, and Characterization of Avian Pathogens**. 5 ed. Madison: American Association of Avian Pathologists, 2008: 75-76.
3. CHIN, RP., VAN EMPEL, PCM., HAFEZ, HM. *Ornithobacterium rhinotracheale* infection. SAIF, YM., FADLY, AM., GLISSON, JR., MCDUGALD, LR., NOLAN, LK., SWAYNE, DE., Eds. **Diseases of Poultry**. 12 ed. Oxford: Blackwell Publishing Ltd., 2008: 765-774.
4. FLETCHER, OJ. Pathology of the avian respiratory system. **Poult. Sci.**, 1980, 59, 2666-2679.
5. FLETCHER, OJ., ABDUL-AZIZ, T., BARNES, HJ. Respiratory system. FLETCHER, OJ., ABDUL-AZIZ, T., Eds. **Avian Histopathology**. 3 ed. Madison: American Association of Avian Pathologists, 2008: 128-163.
6. FLETCHER, OJ. 2010. Avian histopathology in the digital age, update on virtual slides. Respiratory system. 4.2 Trachea (<http://www.ncsu.edu/project/poultryhealth/fletcher/cbs595/learnimg-module04/LM4LC2Master/LM4L C2/LM4-LC2-all.html>).
7. GOODWIN, MA., LATIMER, KS., BROWN, J., STEFFENS, WL., MARTIN, PW., RESURRECCION, RS., SMELTZER, MA., DICKSON, TG. Respiratory cryptosporidiosis in chickens. **Poult. Sci.**, 1988, 67, 1684-1693.
8. GOODWIN, MA., BROWN, J., RESURRECCION, RS., SMITH, J. Respiratory coccidiosis (*Cryptosporidium baileyi*) among Northern Georgia broilers in one company. **Avian Dis.**, 1996, 40, 572-575.
9. GORNATTI CHURRIA, CD., SANSALONE, PL., VIGO, GB., SGUAZZA, GH., MACHUCA, MA., ORIGLIA, JA., PISCOPO MV., HERRERO LOYOLA MA., PETRUCCELLI, MA. Pneumonia in broiler chicken flocks associated with  $\beta$ -hemolytic *Ornithobacterium rhinotracheale* infection. **Braz. J. Vet. Pathol.**, 2011, 4, 243-246.
10. HERRERO LOYOLA, MA., BRANDETTI, E., PETRUCCELLI, MA., PISCOPO, MV., PERFUMO, CJ., MENENDEZ, NA. Descripción de casos de criptosporidiosis en aves. **Rev. Med. Vet.**, 1992, 73, 188-190.

11. MCDUGALD, LR. Cryptosporidiosis. SAIF, YM., FADLY, AM., GLISSON, JR., MCDUGALD, LR., NOLAN, LK., SWAYNE, DE., Eds. **Diseases of Poultry**. 12 ed. Oxford: Blackwell Publishing Ltd., 2008: 1085-1091.
12. REECE, FN., LOTT, DB., DEATON, JW. Ammonia in the atmosphere during brooding affects performance in broiler chickens. **Poult. Sci.**, 1980, 59, 486-488.
13. RHEE, JK., YANG, HJ., YOON, SY., KIM, HC. Immunosuppressive effect of *Cryptosporidium baileyi* on vaccination against avian infectious bronchitis in chicks. **Korean J. Parasitol.**, 1998, 36, 203-206.
14. RYAN, UM., XIAO, L. Birds. FAYER, R., XIAO, L., Eds. **Cryptosporidium and Cryptosporidiosis**. 2 ed. Boca Raton: CRC Press, Taylor & Francis Group, LLC, 2008: 395-418.
15. SENNE, DA. Virus propagation in embryonating eggs. DUFOUR-ZAVALA, L., SWAYNE, DE., GLISSON, JR., PEARSON, JE., REED, WE., JACKWOOD, MW., WOOLCOCK, PR., Eds. **A Laboratory Manual for the Isolation, Identification, and Characterization of Avian Pathogens**. 5 ed. Madison: American Association of Avian Pathologists, 2008: 204-208.
16. SENTIES-CUE, G., CRESPO, R., CHIN, RP. Focal transmural necrotic tracheitis in commercial meat turkeys. **Avian Dis.**, 2003, 47, 234-239.
17. SRETER, T., VARGA, I. Cryptosporidiosis in birds—A review. **Vet. Parasitol.**, 2000, 87, 261-279.
18. THACHIL, AJ., VELAYUDHAN, BT., SHAW, DP., HALVORSON, DA., NAGARAJA, KB. **J. Appl. Poult. Res.**, 2009, 18, 780-788.
19. VAN EMPEL, PCM., HAFEZ, HM. *Ornithobacterium rhinotracheale*: a review. **Avian Pathol.**, 1999, 28, 217-227.