



Case Report

Report of Cerebellar Hypoplasia in Three Calves

Daniela Junqueira de Queiroz¹, Deborah Penteadó Martins Dias¹, Luciana Maria Curtio Soares²,
Marcio de Barros Bandarra², Rosemeri de Oliveira Vasconcelos², Antonio Carlos Alessi²,
Luiz Carlos Marques^{1*}

¹ Departamento de Clínica e Cirurgia Veterinária, Faculdade de Ciências Agrárias e Veterinárias, Unesp, Jaboticabal, SP, Brasil.

² Departamento de Patologia Veterinária, Faculdade de Ciências Agrárias e Veterinárias, Unesp, Jaboticabal, SP, Brasil.

* Corresponding Author: Via de acesso Prof. Paulo Donato Castellane, s/n, Departamento de Clínica e Cirurgia Veterinária, FCAV/Unesp, Jaboticabal, SP 14884-900, Brasil. E-mail: lmarques@fcav.unesp.br

Submitted July 18th 2012, Accepted November 8th 2012

Abstract

Hereditary or acquired cerebellar hypoplasia (CH) is commonly diagnosed in Holstein, Guernsey, Shorthorn and Jersey cattle. Bovine viral diarrhoea (BVD) has been associated to acquired CH due to viral infection during the second trimester of pregnancy. Stricken calf usually shows ataxia, hypermetria, opisthotonus, intentional tremor and wide-based stance when in standing position. Three newborn calves were referred to the FCAV/Unesp Veterinary Teaching Hospital because of neurological distress. The clinical presentation, similar in all cases, indicated CH. Two weeks later, clinical signs did not improve and euthanasia was performed. Macroscopic examination revealed a gelatinous serosanguineous fluid over the brain surface and within the cervical spinal canal. Histologically the cerebellum had disorganization of the internal granular layer and moderate disappearance of Purkinje cells. The observed clinical signs and nervous tissue lesions were consistent with congenital cerebellar syndrome, possibly associated to viral infection during fetal development. Despite CH has been assumed to be related to BVD, blue tongue and Akabane viruses, only the BVD etiology has been already identified in Brazil.

Key Words: bovine viral diarrhoea, cattle, cerebellar malformation, opisthotonus.

Introduction

Nervous system disorders in cattle usually represent a great financial loss worldwide (8). Congenital malformations may be associated with hereditary defects, teratogenic agents, plant toxins, nutritional deficiencies or may still be infectious in origin (2,8). Congenital disorders in calves could manifest only few months after birth, and their pathogenesis is not fully understood (2,23). Structural abnormalities resulting from organogenesis defects, as deformities, and enzyme production deficiencies were described (7,20,23).

Cerebellar hypoplasia (CH) is considered an important congenital disease affecting domestic animals (24). According to Brewer (1987) (4), cerebellar disorders could be hereditary, congenital or acquired in origin, and hypoplasia is the most common cerebellar disorder found in calves. The hereditary form was described for Holstein,

Guernsey, Shorthorn and Jersey cattle (4). Acquired CH develops following cerebellar infection by bovine viral diarrhoea (BVD), Akabane and blue tongue virus (11,24,25).

BVD infection during the second trimester of pregnancy could result in different congenital anomalies (5). The central nervous tissue is the most affected by congenital defects, including CH (12,24), microencephaly, hydrocephalus, hydranencephaly (1), porencephaly (10) and hypomyelination (3). The BVD virus penetrates fetal tissues infecting germinative cells of the developing cerebellum, leading to a destruction of Purkinje cells and granular layer, and consequent hypoplasia (25).

Clinical signs associated with cerebellar syndrome usually include wide-based stance and ataxia, which could vary from discrete incoordination to complete inability to coordinate normal movements and stance.

Hypermetria, opisthotonus and intention tremor could also be observed (4,24,25). According to Scott (2008) (25), severe lesions at the rostral portion of the cerebellum in calves could be associated to opisthotonus, or lateral recumbency accompanied by neck and forelimbs extension and stiffness, and hindlimbs flexion. Macroscopically, cerebellar size reduction could be observed or not, and upon histological evaluation low cellular density of the granular layer and rarefaction of Purkinje cells are evident (19,27).

Cerebellar hypoplasia diagnosis is based on clinical signs and necropsy findings. Immunohistochemical methods could be applied to the central nervous tissue aiming to isolate the pathogenic virus parasiting the cells (24). The differential diagnosis includes other disorders that could induce cerebellar syndrome, as cerebellar abiotrophy and lysosomal storage diseases (16,21). Due to similar clinical presentation, showing opisthotonus and muscle tremors, all disorders causing cerebral edema should also be considered for differential diagnosis from CH (20).

The viral bovine diarrhea is considered a cosmopolitan disease and it has been suggested that antibodies prevalence is about 60% in adult cattle

worldwide (18). According to Samara et al. (2004) (22), the prevalence of anti-BVD antibodies in the northeast region of São Paulo state, Brazil, is 56,49%. The present report describes three cases of CH in calves.

Case report

Three newborn calves, one *Bos taurus* heifer, one *Bos indicus* calf and one mixed breed heifer during the first week of life, were referred on different dates, and from different breeders, to the FCAV/Unesp Veterinary Teaching Hospital, at Jaboticabal city, SP, Brazil. The signs were similar in all cases, and included lateral recumbency and marked opisthotonus or head retraction (star gazing) (Fig. 1). The *Bos taurus* heifer presented blindness identified according to physical examination. Blood count was performed revealing normal values. The calves received trimethoprim (4 mg/kg, IV, SID) associated with sulfamethoxazole (20 mg/kg, IV, SID) for five days, ringer-lactate fluid based on dehydration and acid-base deficit, and were sustained in quadrupedal position aiming to stimulate limbs support. Two weeks later, clinical signs did not improve and given the poor prognosis, the owners elected euthanasia because of financial limitations.

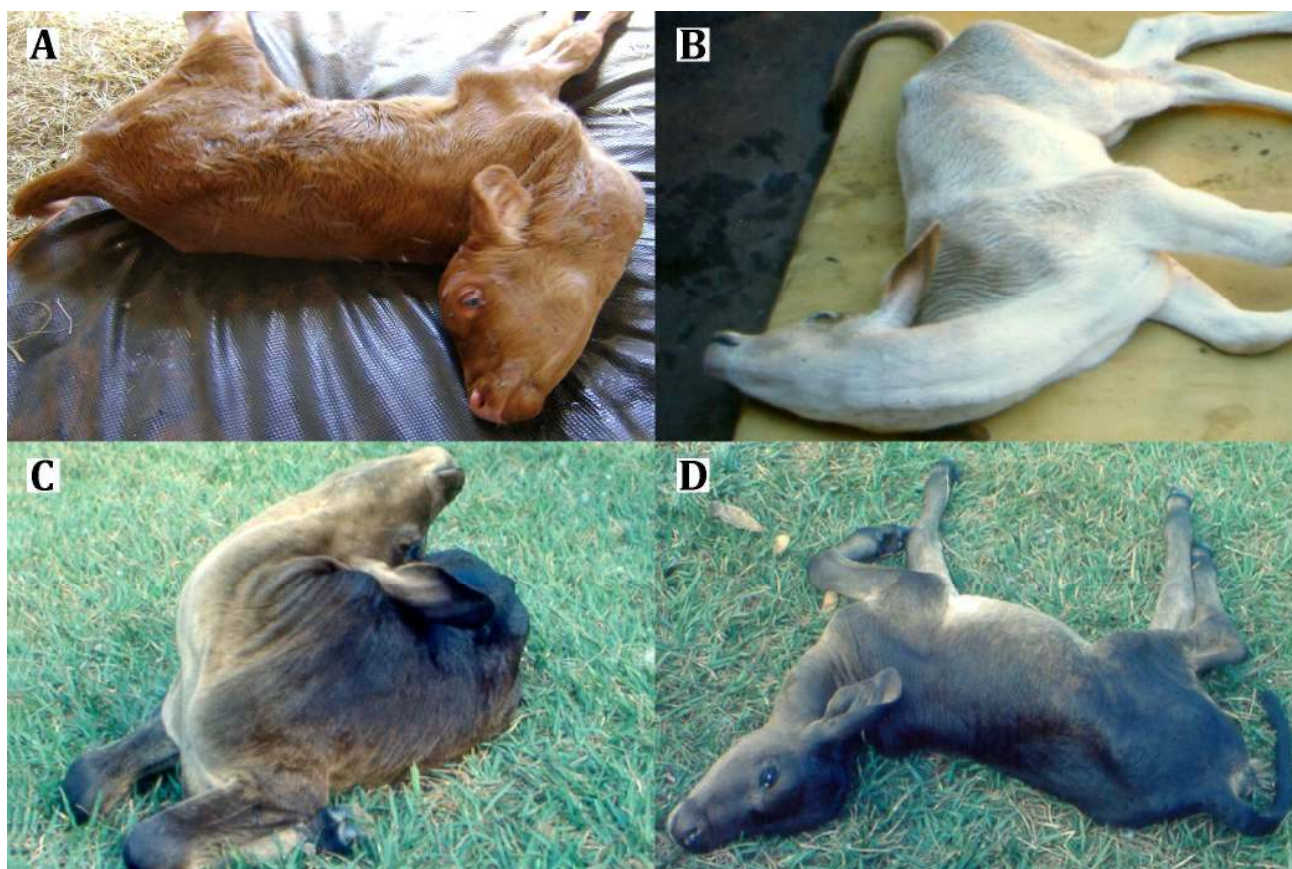


Figure 1. Calves affected by cerebellar hypoplasia showing permanent recumbency and opisthotonus. **A.** *Bos taurus* heifer. **B.** *Bos indicus* calf. **C and D.** Mixed breed heifer.

Gross examination showed deposition of a serosanguineous tissue, of edematous and gelatinous appearance, on cervical spinal canal, cervical spinal cord and encephalic surface mainly within the fourth ventricle of the brain. The cerebellum did not show any changes in volume. Following routine laboratory methods (paraffin embedding and HE stained 5 µm sections) histological findings showed, specifically near to cerebellar leptomeninges, a decreased number of cells in the external germinal layer. The cerebellum had a discrete disorganization of the internal granular layer and moderate rarefaction of Purkinje cells in this layer (Fig. 2 and Fig. 3).

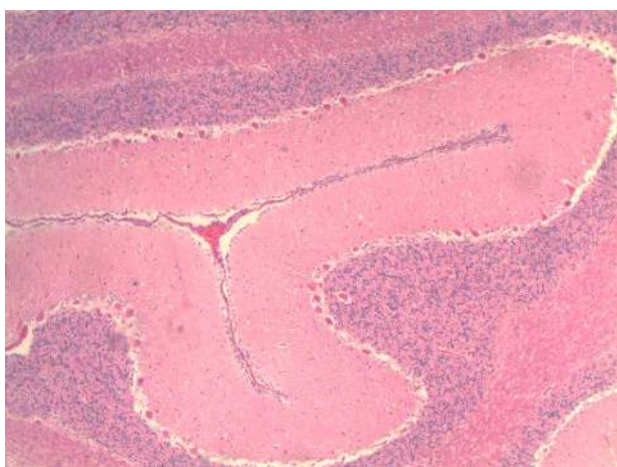


Figure 2. Cerebellum internal granular layer presenting moderate rarefaction of Purkinje cells. HE, 10x.

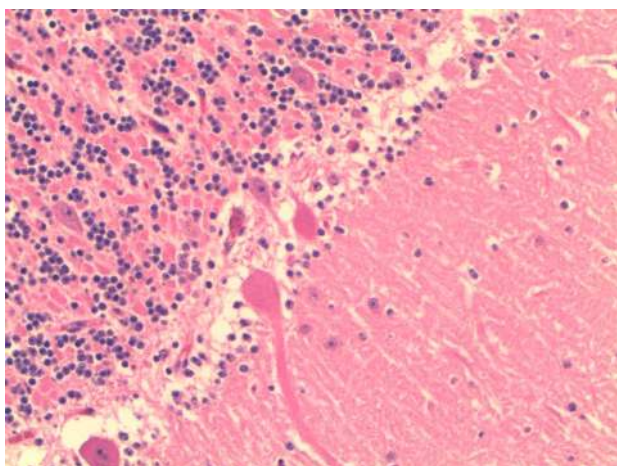


Figure 3. Cerebellum internal granular layer with ectopic Purkinje cells. HE, 40x.

The meninges presented perivascular cuffs. The subependymal region of the fourth ventricle revealed severe edema associated with gliosis and also discrete perivascular cuffs. In the other regions of the brain, lesions were milder, showing interstitial edema at white and grey matter, as well as neuronal degeneration and neuronophagia. The eyes of the heifer that presented blindness were considered normal upon gross and histological evaluation, and unrelated to the cerebellar

changes.

Discussion and conclusion

Cerebellar hypoplasia that develops within the third trimester of pregnancy involves two different processes: necrosis of external germinal layer and vasculitis that leads to white matter ischemia (29). Bovine viral diarrhea, blue tongue and Akabane disease viruses proliferate in the cerebellar external germinal layer, which presents a high mitotic activity during the fetal and neonatal phases. The infection leads to cellular death and disorganization of Purkinje cells location, which may appear off their layer, usually at the internal granular layer. Cell lysis characterizes infectious CH (9,26,29).

The infection of susceptible pregnant cows by BVD virus leads to stillbirth, abortion or developmental disorders, including neurological and ocular defects (6,11). Thus, the effects caused by BVD virus infection are related to the gestation period, as well as immunological resistance is related to fetal maturity. Due to the high mitotic activity, the germinal layer cells are susceptible to the effects of teratogenic agents leading to selective necrosis of these cells. The process is aggravated by vascular lesions also due to viral infection. Infections within the first 100 days of gestation tend to be lethal, resulting in abortion or fetal mummification (11). The second trimester of pregnancy is the most common period for virus infection. The lesions could be of different severity degrees, depending on the gestation period in which infection occurred. Therefore, clinical signs could differ, macroscopic lesions were not always observed and sometimes only histological evaluation could reveal the disease (9,26). The calves of this report presented clinical signs of neurological disease, however without macroscopic alterations. It is known that the embryological formation of normal fetal organs and tissues, including the cerebellum, occurs at early gestation period (15). Despite the occurrence of BVD infection has not been proved, the microscopic findings here described could be associated with a viral infection occurred in the second trimester of pregnancy, when the cerebellum was already formed and was partially destroyed by the virus.

The use of trimethoprim and sulfamethoxazole was recommended initially, because it is known that this drug is the antibiotic of choice in cases of bacterial infections involving the central nervous system, which could promote neurological signs similar to those of CH (20). As abscesses of the central nervous system are often referred to the Hospital routine, this clinical suspicion was not ruled out and the antibiotic treatment was recommended. The treatment was discontinued after five days owing to persistence of neurological signs.

Concerning clinical signs, permanent lateral recumbency, opisthotonus or head retraction (star gazing), and incoordination of different degrees are considered consistent to CH (4,24) and were observed in the calves described in the present report. However, according to Kahrs et al. (1970) (12), neurological clinical signs could

range from mild ataxia to permanent inability to stand. Cases associated with BVD infection usually evidence ataxia, difficulty to stand, hypermetric gait and opisthotonus. Furthermore, clinical signs intensity follows the morbidity of each virus strain (9). Severe lesions include a nonsuppurative inflammation of the brain, associated with necrosis and hemorrhage of the neuropil, resulting in porencephaly or hydranencephaly (26). These lesions description suggests that the present cases were mild probably related to infection installation during a less susceptible gestation phase, due to the low morbidity of the virus, or because there was a low viral load in the nervous tissue. The blindness, observed in one calf, could not be related to CH since the visual awareness is not controlled by the cerebellum (14). Thus, blindness origin remained unclear.

Low cellular density of the granular layer and of Purkinje cells, without gross evidence of a smaller cerebellum, were found in Shorthorn calves presenting CH of hereditary origin (19,27). Wilson et al. (1983) (28) described BVD infection in Holstein cattle leading to cerebellar malformation and hypoplasia. The histological findings included white matter cavitation (porencephaly), rarefaction of Purkinje and granular layer cells, cerebellar cortex disorganization and myelin reduction areas. Some of these findings were also observed in the cases herein described. However, in the present report, calves were from distinct origin and breed, and there were no evidences of genetic transmission. Pathologic changes in genetic cerebellar aplasia or hypoplasia in calves seem to differ from BVD virus-induced cerebellar defect. The inflammatory processes observed in BVD virus cases have not been described in the genetic form (13). Cerebellar size reduction determines clinical signs and could change according to the developmental stage of the fetus when infection occurred (4,24). Therefore, due to mild histological presentation, the infection was probably of an initial stage for the three calves, corroborating Purkinje cells rarefaction. Moreover, according to Kahrs et al. 1970 (12), in cases of CH, clinical signs severity is not always correlated to nervous tissue injury. This statement comes now to explain the concomitant presence of severe opisthotonus upon clinical evaluation and mild neurological injury on histology.

Although the presence of BVD virus was not determined in the present cases, negative results of immunohistochemistry for BVD performed in the cerebellar tissue were reported for calves presenting signs of CH later in the postnatal period (17,24), showing that this determination is not always possible to be completed. In conclusion, considering the clinical and histological presentation, the studied CH cases possibly occurred from viral infection. Assuming that, to date, only cerebellar hypoplasia caused by BVD virus has been identified in Brazil, this report presents three cases of CH possibly related to BVD infection during pregnancy, whose etiology has been associated with transplacental infection.

References

- BADMAN RT., MITCHELL G., JONES RT., WESTBURY HA. Association of bovine viral diarrhoea virus infection to hydranencephaly and other central nervous system lesions in perinatal calves. *Aust. Vet. J.*, 1981, 57, 306-7.
- BARROS CSL., DRIEMEIER D., DUTRA IS., LEMOS RAA. **Doenças do sistema nervoso de bovinos no Brasil (Coleção Valée)**. 1.ed. Montes Claros: Med Vet, 2006.
- BINKHORST GJ., JOURNÉE DL., WOUUDA W., STRAVER PJ., VOS JH. Neurological disorders, virus persistence and hypomyelination in calves due to intra-uterine infections with bovine virus diarrhoea virus. I. Clinical symptoms and morphological lesions. *Vet. Q.*, 1983, 5, 145-55.
- BREWER BD. Examination of the bovine nervous system. *Vet. Clin. North Am. Food Anim. Pract.*, 1987, 3, 13-24.
- BROCK KV., GROOMS DL., GIVENS MD. Reproductive disease and persistent infections. GOYAL SM., RIDPATH JF. Eds. **Bovine viral diarrhoea virus: diagnosis, management and control**. 1.ed. Ames: Blackwell, 2005: 145-156.
- BROWN TT., BISTNER SI., De LAHUNTA A., SCOTT FW., McENTEE K. Pathogenetic studies of infection of the bovine fetus with bovine viral diarrhoea virus. II. Ocular lesions. *Vet. Pathol.*, 1975, 12, 394-404.
- CARLTON WW., McGAVIN MD. **Patologia veterinária especial Thomson**. 2.ed. Porto alegre: Artmed, 1998.
- GALIZA GJN., SILVA MLCR., DANTAS AFM., SIMÕES SVD., RIET-CORREA F. Doenças do sistema nervoso de bovinos no semiárido nordestino. *Pesq. Vet. Bras.*, 2010, 30, 267-76.
- GRAÇA DL., ALESSI AC., ECCO R., VIOTT AM. Patologia do sistema nervoso. SANTOS RL., ALESSI AC. Eds. **Patologia Veterinária**. 1.ed. São Paulo: Roca, 2010: 525-610.
- HEWICKER-TRAUTWEIN M., TRAUTWEIN G. Porencephaly, hydranencephaly and leukoencephalopathy in ovine fetuses following transplacental infection with bovine virus diarrhoea virus: distribution of viral antigen and characterization of cellular response. *Acta Neuropathol.*, 1994, 87, 385-97.
- JUBB KVF., KENNEDY PC., PALMER N. **Pathology of Domestic Animals**. 4.ed. San Diego: Academic Press, 1993.
- KAHRS RF., SCOTT FW., De LAHUNTA A. Congenital cerebellar hypoplasia and ocular defects in calves following bovine viral diarrhoea-mucosal disease infection in pregnant cattle. *J. Am. Vet. Med. Assoc.*, 1970, 156, 1443-50.
- LEIPOLD HW., DENNIS SM. Congenital defects of the bovine central nervous system. *Vet. Clin. North Am. Food Anim. Pract.*, 1987, 3, 159-77.
- LOMAS CA., PIGGINS D., PHILLIPS CJC. Visual awareness. *Appl. Anim. Behav. Sci.*, 1998, 57, 247-57.
- McGREADY TA., QUINN PJ., FITZPATRICK ES., RYAN MT. **Veterinary Embryology**. 1.ed. Oxford: Blackwell Publishing, 2006.
- MAYHEW IG. **Large animal neurology: a handbook for veterinary clinicians**. 1.ed. Philadelphia: Lea & Febiger, 1989.
- MONTGOMERY DL., VAN OLPHEN A., VAN CAMPEN H., HANSEN TR. The fetal brain in bovine viral diarrhoea virus-infected calves: lesions, distribution and cellular

- heterogenicity of viral antigen at 190 days gestation. **Vet. Pathol.** 2008, 45, 288-96.
18. NETTLETON PF., ENTRICAN G. Ruminant pestiviruses. **Br. Vet. J.**, 1995, 151, 615-42.
 19. O'SULLIVAN BM., McPHEE CP. Cerebellar hypoplasia of genetic origin in calves. **Aust. Vet. J.**, 1975, 51, 469-71.
 20. RADOSTITS OM., GAY CC., HINCHCLIFF K.W., CONSTABLE P.D. **Veterinary Medicine: a textbook of the disease of cattle, horses, sheep, pigs and goats**. 10.ed. Philadelphia: Saunders, 2007.
 21. RECH RR., RISSI DR., RODRIGUES A., PIEREZAN F., PIAZER JVM., KOMMERS GD., BARROS CSL. Intoxicação por *Solanum fastigiatum* (Solanaceae) em bovinos: epidemiologia, sinais clínicos e morfometria das lesões cerebelares. **Pesq. Vet. Bras.**, 2006, 26, 183-9.
 22. SAMARA SI., DIAS FC., MOREIRA SPG. Ocorrência da diarréia viral bovina nas regiões sul do Estado de Minas Gerais e nordeste do Estado de São Paulo. **Braz. J. Vet. Res. Anim. Sci.**, 2004, 41, 396-403.
 23. SCHILD AL. Defeitos congênitos. RIET-CORREA F., SCHILD AL. MENDEZ MC., LEMOS RAA. Eds. **Doenças de ruminantes e eqüinos**. 2.ed. São Paulo: Varela, 2001: 19-44.
 24. SCHILD AL., RIET-CORREA F., FERNANDES CG., DAMÉ MC., GRAÇA DL. Hipoplasia cerebelar e porencefalia em bovinos charolês no sul do Rio Grande do Sul. **Cienc. Rural**, 2001, 31, 149-53.
 25. SCOTT PR. Distúrbios neurológicos. ANDREWS AH., BLOWEY RW., BOYD H., EDDY RG. Eds. **Medicina bovina: doenças e criação de bovinos**. 2.ed. São Paulo: Roca, 2008: 787-811.
 26. SUMMERS BA., CUMMINGS JF., De LAHUNTA A. **Veterinary Neuropathology**. St. Louis: Mosby, 1994.
 27. SWAN RA., TAYLOR EG. Cerebellar hypoplasia in beef Shorthorn calves. **Aust. Vet. J.**, 1982, 59, 95-6.
 28. WILSON TM., De LAHUNTA A., CONFER L. Cerebellar degeneration in dairy calves: clinical, pathologic, and serologic features of an epizootic caused by bovine viral diarrhea virus. **J. Am. Vet. Med. Assoc.**, 1983, 183, 544-7.
 29. ZACHARY JF. Sistema Nervoso. McGAVIN MD., ZACHARY JF. Eds. **Bases da patologia em veterinária**. 4.ed. Rio de Janeiro: Elsevier, 2009: 833-971.