Case report

Bone Marrow Involvement in a Dog with Cutaneous Mast Cell Tumor

Sabrina dos Santos Costa Poggiani[1], Flávia Façanha Viana[2], Rosana de Paula Branquinho[3], Fernanda Gomes Velasque Gama[4].

[1]Departamento de Medicina Veterinária, União Pioneira de Integração Social, Brasilia, Distrito Federal, Brasil.
[2]Programa de Residência em Medicina Veterinária, União Pioneira de Integração Social, Brasilia, Distrito Federal, Brasil.
[3]Programa de Residência em Medicina Veterinária, União Pioneira de Integração Social, Brasilia, Distrito Federal, Brasil.
[4]Médica Veterinária, Centro de Especialidades Veterinárias, Brasilia, Distrito Federal, Brasil*
*** Corresponding Author:** [1]Departamento de Medicina Veterinária, União Pioneira de Integração Social. SEP Sul EQ 712/912 Conjunto A, Asa Sul, Brasilia, Distrito Federal, Brasil. 70390-125. E-mail: bina1304@gmail.com

Submitted January 15th. 2013, Accepted June 6th. 2013

Abstract

Cutaneous mast cell tumors with bone marrow involvement are rarely described in dogs and are associated with a poor prognosis. The aim of this report is to describe a case of bone marrow involvement secondary to cutaneous mast cell tumor in a dog and to discuss clinical and pathological abnormalities associated to this finding. Clinical findings associated with bone marrow infiltration included anemia, thrombocytopenia, staging and recurrent and progressive disease. The dog showed a short survival time. A combination of clinical and laboratory evaluation helps in identifying dogs with this type of tumor with bone marrow involvement, since it is not a common metastatic site reported

Key words: dog, mastocytoma, metastases, bone marrow, prognosis, skin

Introduction

Canine cutaneous mast cell tumor (mastocytoma) is the most commonly encountered malignant skin cancer in dogs (10). Animals that are affected are usually older, with a mean age of nine years (1,14). Boxer, Boston Terrier, Collie, Bull Mastiff, Labrador Retriever, Golden Retriever, Pug, Vizsla, Miniature Poodle, Weimaraner, Chinese Shar Pei, Rhodesian Ridgeback and German Shepherd have been reported to be at increased risk of mast cell tumor development (10). Most dogs will present with a solitary mass, but some will present with multiple lesions. Common metastatic sites include the regional lymph nodes, liver, spleen and bone marrow, which influence clinical staging and therefore, treatment and prognosis (14).

Clinical staging requires complete blood counts, aspirates of regional lymph nodes, splenic and liver evaluation and bone marrow aspirations. It also includes depth and number of tumors. Abdominal ultrasound has low sensitivity to identify spleen (43%) and liver (0%) metastasis in dogs with cutaneous mast cell tumors (2). A recent study suggests that cytology should be performed either in ultrasonographically normal or abnormal spleen and liver (8). Cytological criteria utilized by the Clinical Pathology Service at the Matthew J. Ryan Veterinary Hospital of the University of Pennsylvania for determination of metastatic mast cell disease in regional lymph nodes have been published (6).

Bone marrow aspiration for routine clinical staging of canine cutaneous mast cell tumor is not usually performed and the overall incidence of bone marrow infiltration until recently was unknown. Controversy exists among oncologists regarding bone marrow aspiration and evaluation in dogs diagnosed with this tumor. A previous study evaluated a series of 157 dogs presented for cutaneous mast cell tumor in which a complete blood

Brazilian Journal of Veterinary Pathology. www.bjvp.org.br . All rights reserved 2007.

count and bone marrow aspiration were performed. Bone marrow infiltration was identified in seven dogs for an overall incidence of 4,5%. The incidence of bone marrow infiltration on initial presentation was lower (2.8%). Factors significantly associated with bone marrow infiltration included increased age, anemia, neutrophilia, monocytosis, eosinophilia and thrombocytopenia (4). Based on these results, those authors suggest that a bone marrow sample is not indicated for routine staging but maybe indicated for those dogs with mast cell tumors having either an abnormal CBC or presenting tumor regrowth, progression or new occurrence. The goal of our article is to report a case of bone marrow involvement secondary to cutaneous mast cell tumor in a dog and describe clinical and pathological abnormalities associated with this finding.

Case report

A 13-year-old male Dachshund was presented to a referring veterinarian for a gingival mass (approximately 2 cm in diameter) adjacent to the right maxillary first incisor tooth (Figure 1). Cytology showed right submandibular lymph node involvement. Histopathology revealed a grade II mast cell tumor, based on Patnaik et al. (1984) (8) criteria. Five months later, the dog was referred to the Veterinary Medical Teaching Hospital for evaluation of a cutaneous mast cell tumor recurrence within the oral cavity. On oral examination, there was a hemorrhagic ulcerated mass (4 x 3 x 2 cm) on the labial aspect of tooth n.101, that extended to the skin of the muzzle. Regional lymph nodes were enlarged (Figure 2). The dog showed dysphagia and progressive weight loss. Cytology from the regional lymph nodes and the mass were performed and were consistent with mast cell tumor. No evidence of metastatic disease was found on abdominal ultrasound. However, the owner did not allow spleen and liver fine needle aspirates. Thoracic radiographs were unremarkable. Results of the CBC revealed a normocytic, normochromic anemia (hematocrit, 27%: reference range, 37 to 57%). The serum biochemical profile did not reveal any abnormalities. Follow-up treatment involved a neoadjuvant (cytoreductive) chemotherapy protocol using 2mg/m^2 vinblastine intravenously once weekly and 1mg/kg prednisone per os once daily. The chemotherapy regimen was supposed to comprise 8 doses of vinblastine and the dose of prednisone was supposed to be tapered and stopped by the end of the 12-week treatment period (11). However, after 2 cycles, the dog was presented for a complaint of anorexia, lethargy and diarrhea. CBC revealed a normocytic, normochromic anemia (hematocrit, 26%; reference range, 37 to 57%) and thrombocytopenia (100.000 platelets/mm^3: reference range 150.000 to 300.000 platelets/mm^3). Due to persistent anemia and thrombocytopenia, despite the fact that there was no more nodule bleeding and also the absence of melena, a suspicion of bone marrow metastasis has occurred. Bone marrow aspirate smears was performed on sternum. Specimens were examined by the cytopathologist using Panoptic and Rosenfeld modified stains. Bone marrow infiltration was identified, characterized by myelophthisis due to mast cell tumor. Bone marrow aspirate contained low numbers of hematopoietic precursor cells and numerous mast cells, showing malignant characteristics, such as nucleoli of different shape and size (Figure 3). Thus, the animal had a stage V tumor. Treatment involved chemotherapy protocol using 70mg/m^2 lomustine per os. However, after the first cycle, the dog showed continuous episodes of emesis, anorexia and severe lethargy. Despite hospitalization, supportive care and nutritional management, the dog did not show clinical improvement. The dog showed progressive disease and had a survival time of 40 days after the diagnosis of bone marrow metastasis.



Figure 1. A 13-year-old male Dachshund with a gingival mast cell tumor (approximately 2 cm of diameter) to the right maxillary first incisor tooth.



Figure 2. Note the right submandibular lymph node involvement.

Brazilian Journal of Veterinary Pathology. www.bjvp.org.br . All rights reserved 2007.

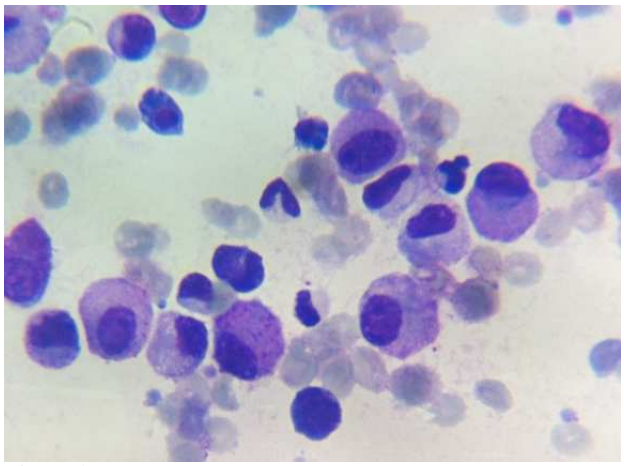

Figure 3. Mast cell tumor in bone marrow, presence of mast cells with small amount of intracytoplasmic granules near hematopoietic myeloid precursor cells (arrows). Panoptic staining (1000X).

Discussion

There are few published reports of bone marrow metastasis due to cutaneous mast cell tumor in dogs (4,7,12). Previous studies state that hematological abnormalities are common findings (4,7). Leukopenia has also been reported on affected dogs, but it was not observed in this dog. In these cases, anemia can also be caused by gastric ulcers as a consequence of increased circulating concentrations of histamine as a paraneoplastic syndrome. Moreover, bone marrow toxicity can also be a consequence of chemotherapy (13). However, this dog showed these findings since the onset of the disease, thus they could not be related to adverse effects of chemotherapy. Veterinary oncologists do not routinely perform bone marrow aspiration for complete mast cell tumor staging and have begun to use CBC results to guide whether or not to perform it. Bone marrow of 157 dogs with cutaneous mast cell tumor has been evaluated (4). The authors found that 2.8% of cases were positive at initial evaluation, with 4.5% positive overall. Additionally, 3/18 dogs were positive after recurrence or progression of clinical signs, suggesting that bone marrow is not indicated for routine staging, but may be considered in cases with progressive disease or when indicated based on CBC. We have observed that the dog did show any of those important criteria, which would have given us support to perform it.

Involvement of bone marrow is unlikely in the absence of disease in the regional lymph nodes (3,14). In this dog, we did observe regional lymph nodes metastases on cytology, based on recent criteria published (6), which strengthens the decision of making bone marrow aspirates. As stated in previous studies, muzzle mast cell tumors are biologically aggressive tumors with higher regional metastatic rates than formerly reported for mast cell tumors in other sites (5).

We have observed a short survival time, as also reported on the literature (7). In that study, they have evaluated the prognosis in 14 dogs that were positive for bone marrow involvement. Median survival time in these cases was 43 days (range, 14-57) and most cases had concurrent metastases to the lymph nodes or visceral metastases, with 3 cases that had evidence of pulmonary metastases. Necropsy was not performed to a full evaluation of distant metastases in our clinical case. However, at the initial presentation, the dog also had regional lymph node metastases.

Staging with bone marrow aspirates has been shown to be a moderately low yield evaluation. Nevertheless, it is worthwhile because the prognosis is significantly altered with a positive bone marrow. Those clinical cases are poorly documented in dogs and successful treatment approaches have not been reported. The treatment with lomustine induced partial remission in 1 of 8 dogs with bone marrow involvement (7). We have also concluded that the use of lomustine was not helpful in this case, based on the absence of clinical improvement and progressive disease. On that former study, dogs on imatinib experienced complete remission. Two dogs survived for 117 and 159 days, and the third was alive after 75 days. Dogs treated symptomatically did not improve and were euthanized after 1, 14, and 32 days. It has been indicated that the beneficial effect of imatinib warrants further investigation (7). Because of financial concerns, tyrosine kinase inhibitor was not performed in this dog.

A combination of clinical and laboratory evaluation helps in identifying dogs with bone marrow involvement, since it is not a common metastatic site reported. An 8-year retrospective study has been conducted to evaluate the prevalence and the classification of canine bone marrow disorders in a clinical pathology service at a university referral hospital. Bone marrow aspirate smears and core biopsy specimens from 717 dogs were investigated and in only 3 metastatic mast-cell tumor were observed (12). The clinician should be aware about the clinical and laboratory findings in cases of bone marrow metastasis due to mast cell tumor, such as recurrence disease and regional lymph node metastases, besides, anemia and thrombocytopenia that highlights the requirement of bone marrow aspirates.

References

1. ARGYLE DJ, TUREK MM, BREARLEY MJ. **Decision making in small animal oncology.** Singapore: Blackwell, 2008: 147-60.
2. BOOK AP, FIDEL J, WILLS T, BRYAN J, SELLON R, MATTON J. Correlation of ultrasound findings liver anda spleen cytology, and prognosis in the clinical staging of high metastatic risk canine mast cell tumors**. Vet. Radiol. Ultrasound,** 2011, 52, 548-54.
3. DOBSON JM, SCASE TJ. Advances in the diagnosis and management of cutaneous mast cell tumours in dogs. **J. Small Anim. Pract.**,2007, 48, 424-31.
4. ENDICOTT MM, CHAMEY SC, McKNIGHT JA, LOAR AS, BRAGER AM, BERGMAN PJ. Clinicopathological findings and

results of bone marrow aspiration in dogs with cutaneous mast cell tumours: 157 cases (1999-2002). **Vet. Comp. Oncol.**, 2007, **5**, 31-7.

5. GIEGER TL, THEON AP, WERNER JA, McENTEE MC, RASSNICK KM, DeCOCK HEV. Biologic behavior and prognostic factors for mast cell tumors of the canine muzzle: 24 Cases (1990–2001). **J. Vet. Intern. Med.**, 2003, 17, 687-92.
6. KRICK EL, BILLINGS AP, SHOFER FS, WATANABE S, SORENNO KU. Cytological lymph node evaluation in dogs with mast cell tumours: association with grade and survival. **Vet. Comp. Oncol.**, 2009, 2,130–8.
7. MARCONATO L, BETTINI G, GIACOBONI C, ROMANELLI G, CESARI A, ZATELLI A, ZINI E. Clinicopathological features and outcome for dogs with mast cell tumors and bone marrow involvement. **J. Vet. Intern. Med.,** 2008, 22, 1001-79.
8. PATNAIK AK, EHLER WJ, MAcEWEN EG. Canine cutaneous mast cell tumors: morphologic grading and survival time in 83 dogs. **Vet. Pathol.** 1984, 21, 469-474.
9. STEFANELLO D, VALENTI P, FAVERZANI S, BRONZO V, FIORIBIANCO V, PINTO da CUNHA N, ROMUSSI S, CANTATORE M, CANIATTI M. Ultrasound-guided cytology of spleen and liver: a prognostic tool in canine cutaneous mast cell tumor. **J. Vet. Intern. Med.**, 2009, 23, 1051–7.
10. VILLAMIL JA, HENRY CJ, BRYAN JN, ELLERSIECK M, SCHULTZ L, TYLER JW, HAHN AW. Identification of the most common cutaneous neoplasms in dogs and evaluation of breed and age distributions for selected neoplasms. **J. Am. Vet. Med. Assoc.**, 2011, 239, 960-5.
11. WEBSTER JD, YUZBASIYAN-GURKAN V, THAMM DH, HAMILTON E, KIUPEL M. Evaluation of prognostic markers for canine mast cell tumors treated with vinblastine and prednisone. **BMC Vet. Res.**, 2008, 4, 32.
12. WEISS DJ. A retrospective study of the incidence and the classification of bone marrow disorders in the dog at a veterinary teaching hospital (1996-2004). **J. Vet. Intern. Med.**, 2006, 20, 955-61.
13. WELLE MM, BLEY CR, HOWARD J, RÜFENACHT S. Canine mast cell tumours: a review of the pathogenesis, clinical features, pathology and treatment. **Vet. Dermatol.**, 2008, 19, 321–39.
14. WITHROW SJ, VAIL DM. **Withrow & MacEwen's Small Animal Clinical Oncology**.5th ed. St Louis, United States: Saunders Elsevier, 2013, Cap 20, 335-55.

Brazilian Journal of Veterinary Pathology. www.bjvp.org.br . All rights reserved 2007.