



## Original full paper

## Female Paraurethral Prostate Gland in Bitches

Adriana C. S. Aguiar<sup>1</sup>, Marcela Marcondes Pinto Rodrigues<sup>1</sup>, Carlos Eduardo Fonseca-Alves<sup>1</sup>,  
 Fernanda C. A. Santos<sup>2</sup>, Patricia S. L. Vilamaior<sup>3</sup>, Sebastião Roberto Taboga<sup>3</sup>, Renée Laufer-Amorim<sup>1\*</sup>

<sup>1</sup>Department of Clinical Veterinary Medicine, School of Veterinary Medicine and Animal Science, São Paulo State University - UNESP, Botucatu, São Paulo, Brazil <sup>2</sup>Department of Morphology, Federal University of Goiás – UFG, Goiânia, Goiás, Brazil.

<sup>3</sup>Department of Biology, Institute of Biosciences, Humanities and Exact Sciences - IBILCE, São Paulo State University - UNESP, Sao Jose do Rio Preto, SP, Brazil.

\* **Corresponding Author:** Department of Veterinary Clinical Science, College of Veterinary Medicine and Animal Science (FMVZ)/UNESP. Rubiao Jr – 18618-970, Botucatu, Sao Paulo, Brazil Phone: 551438802066, e-mail: [renee@fmvz.unesp.br](mailto:renee@fmvz.unesp.br)

Submitted October 3<sup>rd</sup> 2013, Accepted November 28<sup>th</sup> 2013

### Abstract

Even though the presence of the female prostate has been reported in many species, including humans, bats and several rodents, it has many anatomical and histological variations. There is still plentiful discussion on the biological function of this organ. Many authors state that paraurethral ducts and glands are functional and homologous to the male prostate. The use of experimental models and a better knowledge of the female prostate gland in other species, can be useful to veterinary medicine as well as human medicine. Therefore the aim of this study is to check for the presence of this gland in female dogs of various breeds and age. For that purpose 25 urethras, from the bladder to the vulva, were collected, fixed in 10% neutral buffered formalin, routinely processed and sectioned into 4 slides of 4 µm, each with 40 µm gap between each set of 4 slides, using an automatic microtome and stained with Hematoxylin and Eosine (HE). The HE sections were evaluated for the presence of prostatic gland in the sample. Unstained tissue sections cut from paraffin blocks were marked with a polyclonal anti-PSA primary antibody. The prevalence of the gland was 32% (8/25). The structure of the paraurethral PSA-positive gland was acinar, organized in buds, with secretory epithelium varying from cubic to columnar; eccentric nuclei, with loose chromatin and a layer of basal cells, very similar to the male prostate were observed. In view of these characteristics, for the first time in the literature, was demonstrate that those glands may be considered as female prostate in dogs, as they are in other vertebrates.

**Key Words:** female prostate, histology, immunohistochemistry, PSA.

### Introduction

The occurrence of paraurethral glands in females have been reported since the seventeenth century, when Graaf described for the first time the presence of glands located around womens' urethra (15). Two-hundred years later, Alexander Skene described the histology of these glands, which was called Skene's paraurethral glands, anatomically and histologically distinct of the "urethral glands" (2). Since then, several researches have shown the occurrence of paraurethral glands in humans (3, 4) and rodents (5, 6). The female prostate presents many anatomical and histological variations and little is known about the physiology and functional role of this gland in

females (1, 11). Researches point to similarities in the chemical constituents of prostatic liquid eliminated during female ejaculation, to male prostatic liquid, besides the detection of PSA levels in womens' serum and in urine (10). Yet it has been judged as having a function related to sexual behaviour (13) whereas some studies have associated it with the Gräfenberg spot (G-spot), which when stimulated enables the release of female ejaculate by the prostate (14), while other researchers have defended treating it as the same structure (13). Furthermore this gland is an organ that can develop as benign or malignant prostatic disease, similar to the male prostatic gland, mainly during senescence (12).

Using cytochemical, ultrastructural, immunocytochemical and enzymatic techniques, Zaviačič et al. (2000) (16) showed that 90% of the women analyzed presented a glandular cluster associated with the urethral wall, mainly in the anterior and posterior portions. This glandular cluster represented about 10% to 25% of the total weight of the male human prostate and it is formed by a group of acini and ducts inserted into a fibromuscular stroma. Ultrastructurally, the epithelial secretory cells showed a cytoplasm rich in organelles related to the synthesis and secretion of proteins such as rough endoplasmic reticulum, Golgi complex and mitochondria. Besides, the acinar epithelium released large amounts of prostate-specific antigen (PSA) and prostate specific acid phosphatase (PSAP). Based on these structural and functional similarities, Zaviačič argued that the "Skene's paraurethral glands" correspond to the prostate growing in females and that these glands cannot be viewed as vestigial since, though underdeveloped, they present full secretory capacity.

The main focus on the female prostate, besides the biological and behavioural implications, is its capacity to develop some benign, pre-malignant and malignant lesions with aging (12). Recent studies by these authors report cases of urethral neoplasms that had the female prostate as the origin and there is also evidence that other prostatic disorders, such as prostatitis and benign prostatic hyperplasia affect women in a frequency similar to that observed in the male prostate. Pathological changes in the female prostate are: cysts, adenocarcinoma and prostatitis, there are also suspicions that lesions in this gland might be responsible for problems in the urethra and female genitalia (16).

There are no reports about the female prostatic gland in any of the domestic species, therefore the aim of this study was to verify the presence of this gland in female dogs, with no restriction to breed or age.

## Material and Methods

### Samples

Twenty-five urethras, from the bladder to the vulva, from animals brought to the Veterinary Pathology Service, Veterinary Clinical Department, School of Veterinary Medicine and Animal Science, Universidade Estadual Paulista (UNESP), Botucatu, São Paulo, Brazil were collected. The animals were brought to necropsy, from veterinary practitioners after dying from different reasons, but without history of genitourinary tract disease. Table 1 describes the breed, reproductive status, and age (young: up to 2-year-old; adult: from 2 to 5-year-old and old: over 5-year-old) of each bitch included in this study.

### Material processing

The samples were fixed in a 10% neutral buffered formalin solution for 24 h and transferred to a 70% alcohol solution. They were then dissected into to small sections, approximately 5 mm in width and placed in

plastic cassettes ordered by the distance they were located from the vulva.

The material was processed routinely for paraffin embedding and sectioned into 4 slides of 4 µm, each with a 40 µm gap between each set of 4 slides using an automatic microtome. Paraffin was removed and the first section stained with haematoxylin and eosin (HE). When a gland was found in this section, the other 3 slides were stained with Periodic Acid-Schiff (PAS). Masson's trichrome and immuno histochemistry (PSA antigen).

**Table 1.** Animal breed, age and reproductive status of each dog included in this study.

Animal number	Breed	Age	Reproductive status
1	Mongrel	Adult	ovary-intact
2	Mongrel	Adult	ovary-intact
3	Mongrel	Adult	ovary-intact
4	Mongrel	Adult	ovary-intact
5	Mongrel	Adult	ovary-intact
6	Mongrel	Adult	ovary-intact
7	Mongrel	Adult	ovary-intact
8	Mongrel	Adult	ovary-intact
9	Mongrel	Adult	ovary-intact
10	Boxer	Adult	spayed
11	Poodle	Adult	ovary-intact
12	Mongrel	Adult	ovary-intact
13	Mongrel	Adult	ovary-intact
14	Mongrel	Old	spayed
15	Dane	Adult	ovary-intact
16	Mongrel	Adult	ovary-intact
17	Mongrel	Adult	ovary-intact
18	Mongrel	Adult	ovary-intact
19	Mongrel	Adult	ovary-intact
20	Mongrel	Adult	ovary-intact
21	Mongrel	Young	ovary-intact
22	Mongrel	Young	ovary-intact
23	Mongrel	Young	ovary-intact
24	Mongrel	Young	ovary-intact
25	Mongrel	Young	spayed

### Immunohistochemistry

The reaction was made using polyclonal anti-PSA primary antibody (Dako, Glostrup, Denmark). Briefly, the slides were dehydrated, antigen retrieval was made in microwave with citrate buffer pH 6,0, three times of 5 minutes each, in 750W. The slides were left to cool at room temperature and the peroxidase blockage was achieved by immersion in 3% solution of hydrogen peroxide for 20 minutes. Primary antibody was diluted in background reduction solution (Dako) 1:1000 for 2 hours at 37°C. Envision Dual Link System Peroxidase (Dako)

was applied for 1 hour at room temperature as the secondary antibody in a polymer system, then DAB (Dako) for 5 minutes and the slide was finally counterstained with Harris's haematoxylin.

Negative controls were performed for all antibodies by omitting the primary antibody and replacing it by Tris-buffered saline. Normal canine prostate was used as positive control for PSA expression

### Results and Discussion

The frequency of the PSA-positive paraurethral glands was of 32% (8/25), seven were from young animals (28% - 7/25), 17 from adults (68% - 17/25) and one from an old animal (4%-1/25), a small relative frequency in comparison to women (90%) or gerbils (80%) according to Zaviacic and Albin (2000) (15) and Santos and collaborators (2006) (12) respectively. Three animals were spayed (12% - 3/25), one was a Boxer dog, one a Poodle and one a Great Dane, twenty-two were mongrel dogs, the category overrepresented in our Veterinary Hospital.

Two animals had the gland in both sides of the urethral lumen and the other 6 in only one side; all of them were inserted in the urethral muscle. Only one was outside the muscle and it was very dilated (Figure 1), suggesting that it developed more than the others. If this gland responds similarly to hormones as does the male prostate (7, 8) and the female gerbil's prostate (12), this could be an indicative of hormonal imbalance.

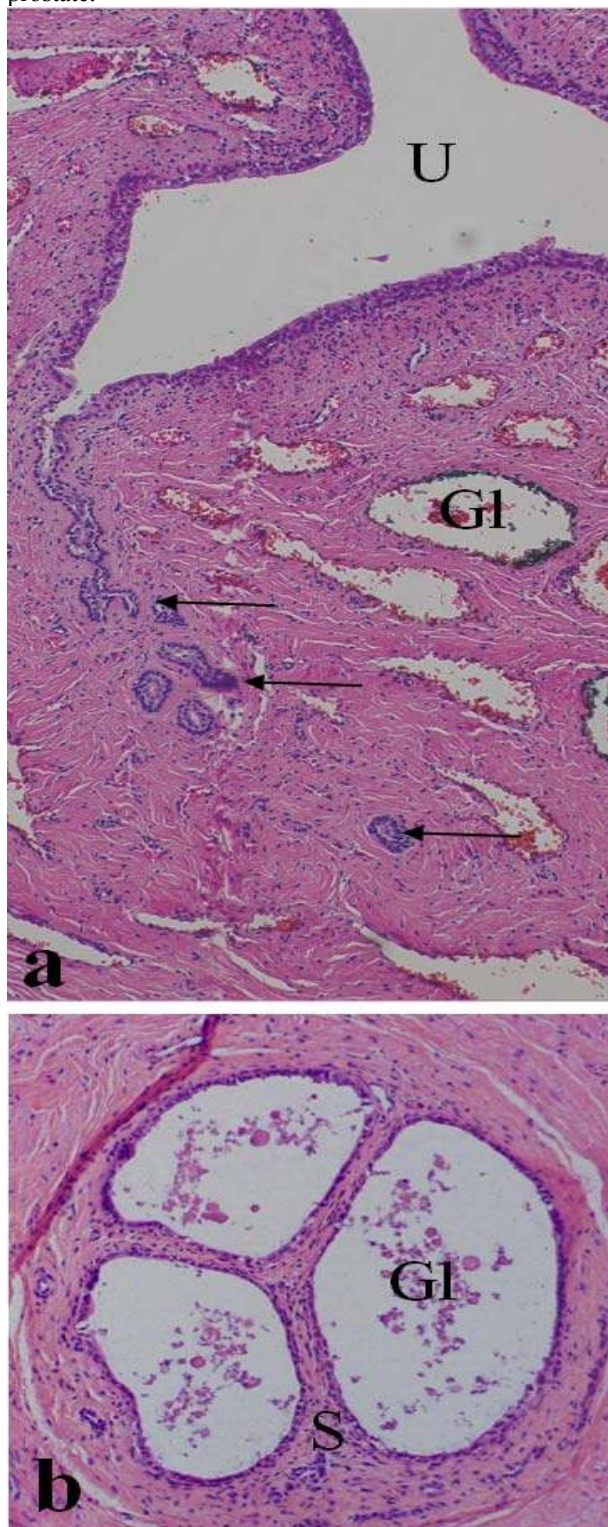
All paraurethral glands were positive for PSA (prostatic specific antigen) and it was possible to see the ducts communicating with the urethral lumen (Figure 2). The PSA staining was strong and observed in the lumen, epithelium and ducts.

Only three animals were spayed and two of them had paraurethral glands, which could suggest that the regression of this gland is influenced by female hormones in physiological conditions. Thus, the lack of oestrogen and progesterone could lead to an imbalance and relative increase of androgens, which could contribute to the paraurethral PSA-positive glands in these animals. It is known that all steroid hormones influence the development and growth of the human prostate, even though the mechanism is not yet clear (11). Such a mechanism should be confirmed in a higher number of animals. Furthermore, the population of dogs brought into our Veterinary Hospital is composed mainly of ovary-intact dogs and the spayed group investigated is too small to draw any conclusions.

The influence of hormones in the development of the PSA-positive paraurethral gland could not be proved nor discarded by this study because the only animal presenting macroscopic significant alteration, polycystic ovary, presented the gland with the same histological features as the others.

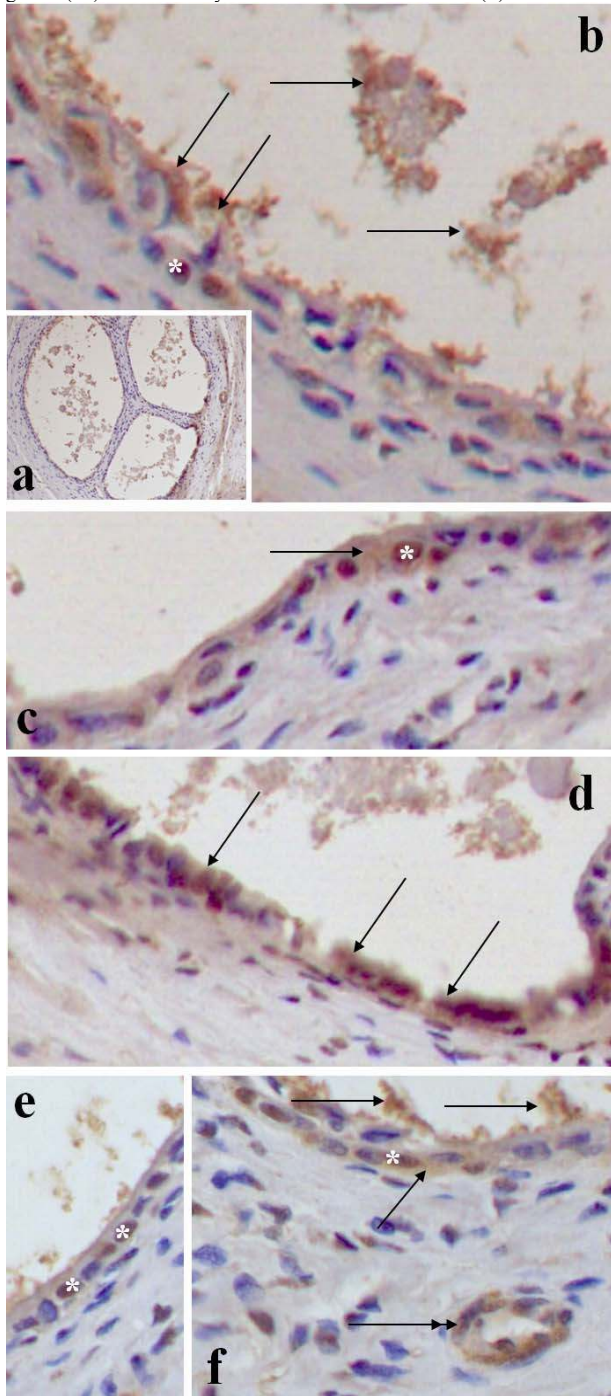
The structure of the paraurethral PSA-positive gland was acinar organized in buds, with secretory epithelium varying from cubic to columnar like in women

and rodents, eccentric nuclei with loose chromatin (Figure 1) and a layer of basal cells, very similar to the male prostate.



**Figure 1.** Micrographs of the dog "female prostate" (paraurethral glands) stained with HE. (a) Distribution of several ducts (arrows) and glands (Gl) in the paraurethral region, including in this image, the ductal communication with the urethra (U). 200X. (b) Detail of the "cluster" of

glands (GI) surrounded by a dense fibromuscular stroma (S). 300X.



**Figure 2.** Female prostate (paraurethral glands). Anti-PSA antibody IHC, Harris' hematoxylin counterstain. (a) General view of the glands cluster. 100X. (b-e) Some regions of the glands and ducts epithelial cells (arrows) stained positively with anti-PSA antibody. Some nuclei showed unspecific reaction (\*). (f) The double arrow indicates a strongly positive anti-PSA duct. 400X.

We have chosen to address the gland as PSA-positive paraurethral gland because, even though all suggests that it is a female version of the male prostate, PSA staining could be caused by kalikreins and/or

serinoproteases, since the antigen used was polyclonal (11). There are other substances produced by the human body that have similar structure to PSA and they are called human kallikreins (HK). Human kallikrein 2 (HK2) is active in seminal plasma, acting similarly to PSA, and HK1 is expressed in salivary glands and is stained by polyclonal anti-PSA (4).

### Conclusions

The finding of a PSA-positive paraurethral gland, very similar to the male prostate in female dogs suggests the presence of the female prostate in this species. This is an important finding, since it seems to be an active secreting gland, by the strong PSA staining and can be a site for many diseases, such as hyperplasia and cancer and even a possible primary metastatic tumour, so veterinarians should be aware of prostate gland as the primary site of metastasis of unknown origin in female dogs

### Acknowledgments

This work was supported by Sao Paulo State Research Foundation (FAPESP) – Proc. Nr. 07/56698-5 and by Brazilian Research Council (CNPq) – Research Fellowships to RLA (Proc. Nr. 307825/2008-6) and to SRT (Proc. Nr. 300163/2008-8).

### References

- ADDIEGO F., BELZER EG., COMOLLI Jr., MOGER W., PERRY JD., WHIPPLE B. Female ejaculation: A case study. *J. Sex Res.*, 1981, 17, 13-21.
- CUSTODIO AMG., GOES RM., TABOGA SR. Acid phosphatase activity in gerbil prostate: Comparative study in male and female during postnatal development. *Cell Biol. Int.*, 2004, 28, 335-344.
- CUSTODIO AMG., SANTOS FCA., CAMPOS SGP., VILAMAIOR PSL., GOES RM., TABOGA SR. Aging effects on the mongolian gerbil female prostate (Skene's Paraurethral Glands): Structural, ultrastructural, quantitative and hormonal evaluations. *Anatomical Rec.*, 2008, 291: 463-474.
- De ANGELIS G., RITTENHOUSE HG., MIKOLAJCZYK SD., BLAIR L., SEMJONOV A. Twenty years of PSA: From prostate antigen to tumor marker. *Rev. Urol.*, 2007; 9: 113-123.
- FLAMINI MA., BARBEIRO CG., GIMENO EJ., PORTIANSKY EL. Morphological characterization of the female prostate (Skene's gland or paraurethral gland) of *Lagostomus maximus maximus*. *Ann. Anat.* 2002, 184, 341-345.
- FOCHI RA., PEREZ APS., BIANCHI CV., ROCHEL SS., GOES RM. Hormonal oscillations during the estrous cycle influence the morphophysiology of the gerbil (*Meriones unguiculatus*) female prostate (Skene Paraurethral Glands). *Biol. Reprod.*, 2008, 79: 1084-1091.
- FONSECA-ALVES CE., FALEIRO MBR., LAUFER-AMORIM R., De MOURA VMBD. Prostatic histological evaluation in adult not castrated dogs. *Arq. Bras. Med. Vet. Zootec.*, 2010, 62: 596-602.
- FONSECA-ALVES CE., CORREA HL., SANTOS-JUNIOR AG., ELIAS F., COSTA S.S., De MOURA VMBD. Prostatic abscess in dogs: Report of 15 cases. *Semina Ciencias Agrarias*, 2012, 33, 1157-1164.
- FONSECA-ALVES CE, RODRIGUES MM., De MOURA VM., ROGATTO SR., LAUFER-AMORIM R. Alterations of C-MYC, NKX3.1, and E-cadherin expression in canine prostate carcinogenesis. *Microsc. Res. Tech.* 2013, 12, 1250-1256.
- GROSS S.A., DIDIO LJ. Comparative morphology of the prostate in adult male and female praomys (*Mastomys*) natalensis studied

- with electron microscopy. **J. Submicroscopic. Cytol.**, 1987, 19, 77-84.
11. PRINS G.S., HUANG L., BIRCH L., PU Y. The role of estrogens in normal and abnormal development of the prostate gland. **Ann. N. Y. Acad. Sci.**, 2006, 1089, 1-13.
  12. DOS SANTOS FCA., CARVALHO HF., GOES RM., TABOGA SR. Structure, histochemistry and ultrastructure of the epithelium and stroma in the gerbil (*Meriones unguiculatus*) female prostate. **Tissue Cell**, 2003, 35, 447-457.
  13. SHARIFI-AGHDAS F., GHADERIAN N. Female paraurethral cysts: experience of 25 cases. **BJU International**, 2004, 93, 353-356.
  14. SHEHATA R. Female prostate and urethral glands in the home rat, *Rattus norvegicus*. **Acta Anatomica**, 1980, 107, 286-288.
  15. ZAVIACIC MV., ALBIN RJ. The female prostate and prostate-specific antigen. Immunohistochemical localization, implications of this prostate marker in women and reasons for using the term "prostate" in the human female. **Hist. Histopath.**, 2000, 15, 131-142.
  16. ZAVIACIC MV., JAKUBOVSKA V., BELOSOVIC M., BREZA J. Ultrastructure of the normal adult human female prostate gland (Skene's gland). **Anat. Embryol.**, 2000, 201: 51-61.