



Case report

Testicular Teratoma in Gray Brocket Deer (*Mazama gouazoubira*)

Walter Javier Lértora¹, Javier Fernandez², Marcial Sánchez Negrette^{1*}

¹Cátedra de Patología General y Sistemática, Facultad de Ciencias Veterinarias, UNNE, Sargento Cabral 2139, (3400) Corrientes, Argentina.

²Reserva Experimental de Horco Molle, Facultad de Ciencias Naturales e Instituto Miguel Lillo, Universidad Nacional de Tucumán, Miguel Lillo 205, (4017) Tucumán, Argentina.

* Corresponding Author: E-mail: patgral@vet.unne.edu.ar

Submitted May 23th 2014, Accepted July 02nd 2014

Abstract

A 4-year-old gray brocket deer was submitted to bilateral orchiectomy for enlargement of the right testicle, which measured 10 x 7 x 6 cm. The testicular tumor consisted of multiple cysts containing pilosebaceous brown material and translucent mucin. Histologically, the cysts showed keratinized stratified squamous epithelium over dermal tissue with hair follicles, sebaceous and sweat glands; pseudostratified cylindrical ciliated epithelium with goblet cells, ciliated columnar epithelium and secretory columnar epithelium. Among cysts, disorganized areas of adipose tissue, arteries, nerves, neurons, smooth muscle, dense connective tissue and cartilage tissue were observed. Epithelial and mesenchymal tissues were found well differentiated. The macro and microscopic examination of the testis allowed the diagnosis of benign cystic teratoma.

Key words: wildlife diseases, gray brocket deer, benign cystic teratoma, testis.

Introduction

Teratomas are neoplasms derived from germ cells that have undergone somatic differentiation, producing mature but disorganized tissues of at least two, usually three, embryonic layers (8). Testicular teratomas are rare in domestic animals, being mostly reported in cryptorchid young horses (3). A few cases of teratomas have been reported in wild mammals. Ovarian teratomas have been reported in Père David's deer (*Elaphurus davidianus*) (16), in Iberian red deer (*Cervus elaphus hispanicus*) (5) and ferret (*Mustela putorius furo*) (15). Moreover, extra-gonadal teratomas have been reported in American black bear (*Ursus americanus*) (13), skunk (*Mephitis mephitis*) (12), sable antelope (*Sable niger*) (4) and giraffe (*Giraffa camelopardalis reticulata*) (14). To our knowledge, there are no documented cases of testicular teratoma in wild mammals of the family *Cervidae*. This paper describes the first known case of a testicular teratoma in a gray brocket deer (*Mazama gouazoubira*).

Case Report

In February 2012, a 4 year- old male gray brocket deer (*Mazama gouazoubira*) presented an increase in size of 10 x 7 x 6 cm of the right testis (Figure 1) without manifestation of pain or change in behavior.

The male had been on captivity since 2008 in the Experimental Reserve Horco Molle, Tucumán, Argentina, living together with a female with whom he fathered three offsprings. Bilateral orchiectomy was performed and the surgical specimen was fixed in 10% neutral-buffered formalin and sent to the Faculty of Veterinary Science, UNNE. Tissue samples were embedded in paraffin, sectioned at 4 µm and stained with HE for histopathological analysis. After bilateral orchiectomy, the deer recovered favorably without expressing recurrences until March of 2014.

The right testis showed an ovoid shape of 10 x 7 x 6 cm, nodular smooth surface, with areas of firm consistency and areas of soft and fluctuating consistency.

When cut, multiple cysts of 0.5 to 1 cm in diameter, some containing brown sebaceous material mixed with hairs and others with gelatinous translucent material (Figure 2) were observed. The left testis showed an ovoid shape, measured 6 cm on its long axis, 3 cm wide and had no macroscopic lesions.

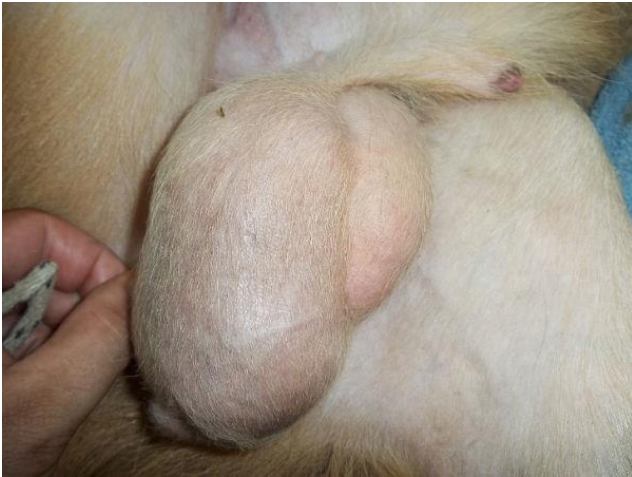

Figure 1. Testicular teratoma in gray brocket deer (*Mazama gouazoubira*). Enlargement of the right testicle, which measured 10 x 7 x 6 cm.

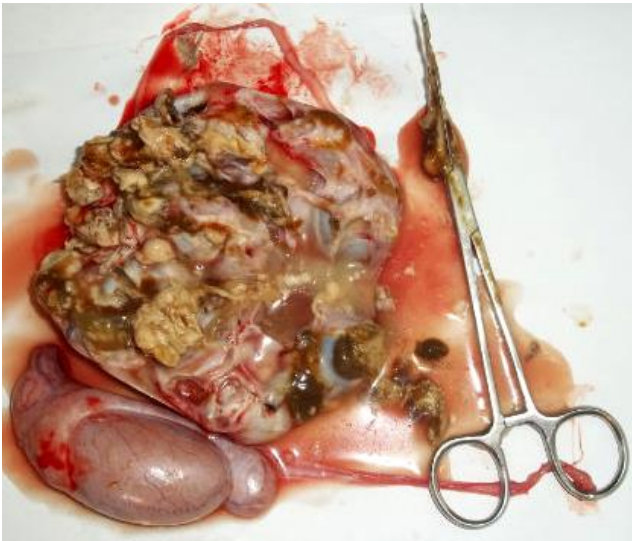


Figure 2. Testicular teratoma in gray brocket deer (*Mazama gouazoubira*). Multiple cysts filled with pilosebaceous brown material.

Microscopically, the right testis showed multiple cysts with abundant keratin lined by stratified squamous epithelium and dermal tissue composed of dense connective tissue with hair follicles, sebaceous and sweat glands (Figure 3). Other cysts contained amorphous eosinophilic material lined by pseudostratified cylindrical ciliated epithelium with goblet cells (Figure 4), simple ciliated columnar epithelium and columnar secretory epithelium. Among cysts, disorganized areas of adipose

tissue, arteries, dense connective tissue, smooth muscle, cartilage tissue (Figure 5), neurons, glial cells and nerves well delimited by perineurium were observed (Figure 6). All epithelial and mesenchymal tissues were found well differentiated. In a small area of the tumor atrophic seminiferous tubules epithelium were found, mainly composed of Sertoli cells. The left testis showed no microscopic lesions; seminiferous tubules presented normal spermatogenic epithelium with sperm normally differentiated.

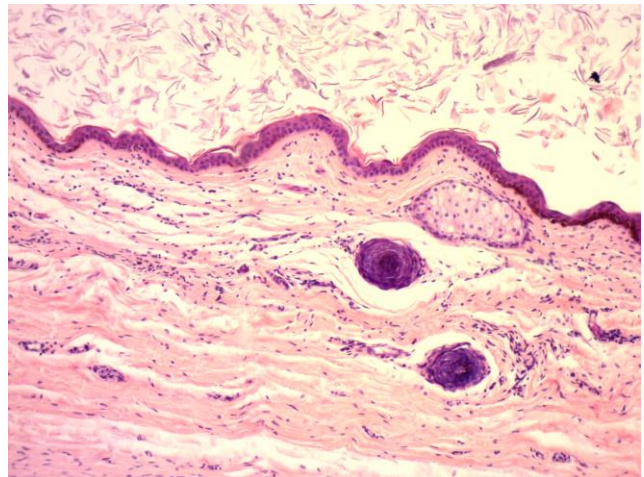


Figure 3. Testicular teratoma in gray brocket deer (*Mazama gouazoubira*). Cyst lined by epidermis and dermis with sebaceous gland and hair follicles (HE, 100x).

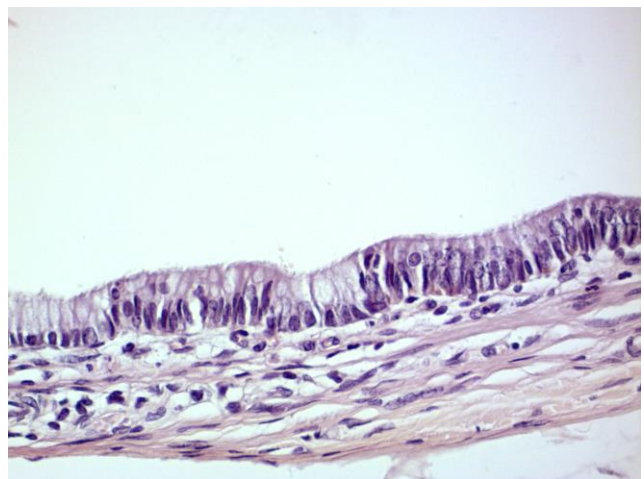


Figure 4. Testicular teratoma in gray brocket deer (*Mazama gouazoubira*). Cyst lined by respiratory epithelium (HE, 400x).

Discussion

Few cases of gonadal teratoma have been reported in wild animals (5, 15, 16). In gray brocket deer (*Mazama gouazoubira*) an ovarian mucinous cystadenoma has been reported (11) and, to our knowledge, there are no reports of

testicular teratoma in this species or other mammals of the *Cervidea* family.

The salient enlargement of the affected testicle was the only clinical sign associated with this neoplasm. Clinical signs of ovarian teratomas in wild mammals are minimal or mild (palpable mass in the abdominal cavity) (15), usually being incidental findings at necropsy (5, 16). In extra gonadal teratomas clinical signs associated with their location were reported. Also, atelectasis due to obstruction when located in the oropharynx (4); compression of the lungs and displacement of the heart when located in the mediastinum (13), an abnormal increase in amniotic fluid was reported in teratoma of the umbilical cord (14) and pelvic limb paralysis in the lumbosacral spinal cord teratoma (7).

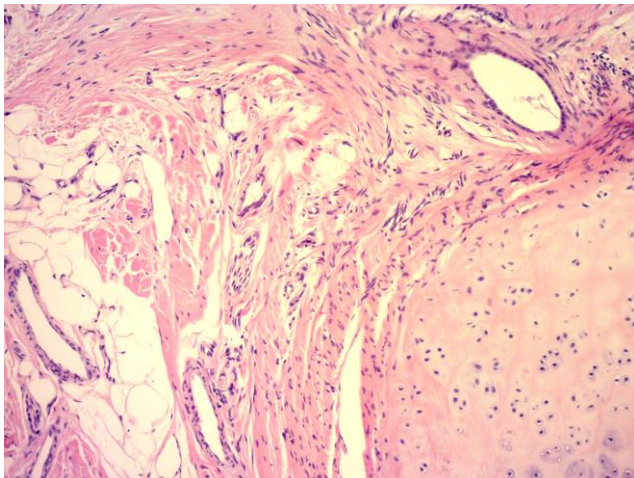


Figure 5. Testicular teratoma in gray brocket deer (*Mazama gouazoubira*). Disorganized mixture of cartilage, dense connective tissue, adipose tissue, arteries and nerves (HE, 100x).

The gross and microscopic lesions observed in the present case were similar to those described for gonadal teratomas in domestic and wild animals. The teratomas were solid, cystic or solid and cystic with pilosebaceous and mucous content. They were constituted by areas of skin tissue, glandular epithelium, fibrous connective tissue, fat, muscle, lymphatic tissue, nervous tissue, bone, cartilage, teeth, and choroid plexus. Most teratomas presented well differentiated but disorganized tissue (3, 8). Ovarian teratomas reported in wild mammals also caused an enlargement of the gonad with multiple cysts lined by well-differentiated squamous, respiratory and glandular epithelium and areas with nervous tissue, cartilage, adipose tissue and muscle (5, 15, 16).

As in this case, the gonads, final destination of germ cells, were the most common anatomic location of teratomas (9). In wild animals, extra-gonadal teratomas were also reported in the mediastinum (13), retroperitoneum (12) oropharynx (4) and vertebral canal (7).

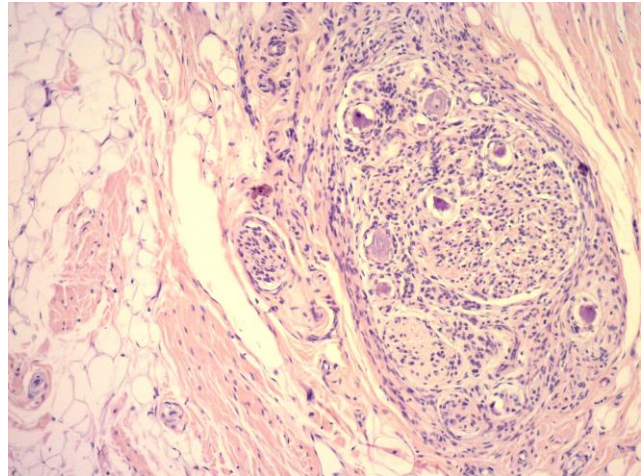


Figure 6. Testicular teratoma in gray brocket deer (*Mazama gouazoubira*). Nervous tissue composed of neurons, glial cells and nerve delimited by perineurium between adipose and dense connective tissues (HE, 100x).

Teratomas are classified as benign or malignant according to the degree of anaplasia or the presence of undifferentiated embryonic structures (10). In our case, the behaviour was benign; as determined by the histological composition of the tumor, its location, symptoms and the absence of recurrence after surgery. In pets, most teratomas were benign and of favourable prognosis (3, 8, 10). Ovarian teratomas reported in wild mammals were also benign (5, 15, 16). Extra gonadal teratomas reported in wild animals also had a benign histological composition; although their location and size could compress vital organs and have a malignant clinical behaviour (4, 13, 14).

Teratomas carcinogenesis is not fully established. They originate from primordial germ cells (gamete precursor stem cells) which undergo neoplastic change during early embryonic, fetal or postnatal life (2). Germ cells are the only known stem cells that hold the potential to develop into a complete organism through a complex mechanism of differentiation. During the life of an animal, the subjacent pluripotentiality of germ cells is suppressed, while undergoing differentiation to form male or female gametes, with highly specialized characteristics of sperm and oocytes. Despite its specialized differentiation pluripotency underlying germ cell is maintained and reactivated only when they unite to form a zygote. Testicular teratomas arise as a result of a disorder of the underlying mechanisms that repress pluripotency of germ cells during a critical point of differentiation. Failure to repress pluripotency may result from a cell autonomous programming error in a germ cell and/or an extracellular signaling interaction (1).

In the present case, it was not possible to determine predisposing factors for the development of testicular teratoma. There are several influences that predispose germ cell neoplasms: cryptorchidism, testicular dysgenesis and genetic factors (2). In young horses,

testicular teratomas are associated with cryptorchidism (3). Two hypotheses associated cryptorchidism with testicular neoplasms in man. One assumes that the testes with abnormal location exposed to environmental changes that influence their neoplastic transformation. This theory has low acceptance, because early orchidopexy does not guarantee the prevention of testicular tumors; also, clinical studies documented an increased risk of neoplasia in the contralateral descended testes of monorchidos men. The other hypothesis assumes a common etiologic factor for cryptorchidism and testicular neoplasia. An abnormal gene expression or increased levels of maternal estrogens during pregnancy would stimulate both pathologies in humans (6). Men with abnormal testicular development (testicular dysgenesis), including testicular feminization, have an increased risk of developing germ cell neoplasia. Racial predisposition also seems important in the human (2). As with any type of neoplasia, genomic changes are also implicated in the pathogenesis of testicular teratomas. Several genes were identified (Pten, DMTR1, Dnd1, KITLG) influencing the incidence of teratomas in mice. Deficient function of these genes promotes the pluripotency of the germ cell and development of teratomas (1).

The macro and histopathological study confirmed the presence of a benign cystic teratoma in the testis of a brocket deer (*Mazama gouazoubira*). The clinical and pathological presentation was similar to that reported in other mammals.

References

1. BUSTAMANTE-MARÍN X., GARNES JÁ., CAPEL B. Testicular teratomas: an intersection of pluripotency, differentiation and cancer biology. **Int. J. Dev. Biol.**, 2013, 57, 201-10.
2. EPSTEIN JI. Tracto urinario inferior y sistema genital masculino. KUMAR V., ABBAS AK., FAUSTO N. Eds. **Robins y Cotran patología estructural y funcional**. 7.ed. Madrid: Elsevier, 2005: 1043-4.
3. FOSTER RA., LADDS PW. Male genital system. MAXIE MG. Ed. **Jubb, Kennedy and Palmer's pathology of domestic animals**. 5.ed. v.3. Philadelphia: Saunders Elsevier, 2007: 598-600.
4. HAEFELE HJ., GUTHRIE A., TRUPKIEWICZ JG., GARNER MM. Oropharyngeal Teratoma in a Neonatal Sable Antelope (*Hippotragus niger*). **J. Zoo Wildl. Med.**, 2008, 39, 266-9.
5. HÖFLE U., VICENTE J., GORTAZAR C. Bilateral ovarian teratoma in a free-living Iberian red deer (*Cervus elaphus hispanicus*). **N. Z. Vet. J.**, 2004, 52, 44-5.
6. HUSMANN DA. Cryptorchidism and its relationship to testicular neoplasia and microlithiasis. **Urology**, 2005, 66, 424-6.
7. KELLER DL., SCHNEIDER LK., CHAMBERLIN T., ELLISON M., STEINBERG H. Intramedullary lumbosacral teratoma in a domestic ferret (*Mustela putorius furo*). **J. Vet. Diagn. Invest.**, 2012, 24, 621-4.
8. KENNEDY PC., CULLEN JM., EDWARDS JF., GOLDSCHMIDT MH., LARSEN S., MUNSON L., NIELSEN S. **Histological classification of tumors of the genital system of domestic animals**. 2 series. Washington: Armed Forces Institute of Pathology and American Registry of Pathology, 1998.
9. LOOIJENGA LHI., OOSTERHUIS JW. Pathogenesis of testicular germ cell tumours. **Rev. Reprod.**, 1999, 4, 90-100.
10. MACLACHLAN NJ., KENNEDY PC. Tumors of the genital systems. MEUTEN DJ. Ed. **Tumors in domestic animals**. 4.ed. Iowa: Blackwell Publishing, 2002: 565-6.
11. MONTEIRO LN., SALGADO BS., GRANDI F., FERNANDES TR., MIRANDA BS., TEIXEIRA CR., ROCHA RM., ROCHA NS. Ovarian mucinous cystadenoma in a gray brocket deer (*Mazama gouazoubira*). **J. Vet. Diagn. Invest.**, 2011, 23, 589-92.
12. MUNDAY JS., FAIRCHILD SE., BROWN CA. Retroperitoneal teratoma in a skunk (*Mephitis mephitis*). **J. Zoo Wildl. Med.**, 2004, 35, 406-8.
13. MUNK BA., TURNER C., KEEL K. Mediastinal teratoma in a free-ranging american black bear (*Ursus americanus*). **J. Zoo Wildl. Med.**, 2013, 44, 1120-2.
14. MURAI A., YANAI T., KATO M., YONEMARU K., SAKAI H., MASEGI T. Teratoma of the umbilical cord in a giraffe (*Giraffa camelopardalis reticulata*). **Vet. Pathol.**, 2007, 44, 204-6.
15. RODRÍGUEZ JL., MARTÍN DE LAS MULAS J., ESPINOSA DE LOS MONTEROS A., RODRÍGUEZ F., FERNÁNDEZ A. Ovarian teratoma in a ferret (*Mustela putorius furo*): A morphological and immunohistochemical study. **J. Zoo Wildl. Med.**, 1994, 25, 294-9.
16. YOON BI., KWEON OK., KWON SW., SHIN NS., SEO IB., KIM DY. Concurrent multicentric hemangiosarcoma and ovarian teratoma in an aged Père David's deer. **J. Zoo Wildl. Med.**, 1999, 30, 456-8.