



Case Report

Cytopathology in the Diagnosis of Oral Trichomoniasis in a Rock Pigeon (*Columba livia*)

Alexandre Arenales^{1*}, Ana Carolina Ortegal Almeida¹, Luiz Fernando Prado², Sérgio Garcia²,
Maria Cecília Rui Luvizotto¹

¹UNESP – Univ. Estadual Paulista, Araçatuba, Brazil, Setor de Patologia, Faculdade de Medicina Veterinária.

²UNESP – Univ. Estadual Paulista, Araçatuba, Brazil, Hospital Veterinário - Luiz Quintiliano de Oliveira, Faculdade de Medicina Veterinária.

* **Corresponding Author:** : UNESP/Araçatuba, Departamento de Clínica, Cirurgia e Reprodução Animal, Faculdade de Medicina Veterinária, Serviço de Patologia Veterinária, 793, 16050-680, Araçatuba, São Paulo, Brazil. E-mail: arenalestorres@gmail.com

Submitted June 11th 2014, Accepted July 11th 2014

Abstract

A Rock Pigeon (*Columba livia*) submitted for necropsy had an oral white-yellow mass with a friable surface and putrid odor. Impression smears were performed and tissue samples were collected for histopathology. Cytopathological analysis revealed numerous pyriform protozoa, compatible with *Trichomonas gallinae*. Protozoans were not evident within the lesions by histopathology after staining the samples with Hematoxylin and Eosin or Gomori methenamine silver (GMS) stain. We conclude that impression smears from avian oral trichomoniasis suspects, even during post-mortem evaluation, can be a useful technique for the diagnosis of this disease.

Key words: *Trichomonas gallinae*; avian pathology; cytopathology; *Columba livia*.

Introduction

Trichomonas gallinae is a flagellated protozoan capable of infecting various avian species, but it is especially prevalent in pigeons (*Columba livia*) and other columbiformes. *T. gallinae* typically infects the upper digestive tract, including oral cavity, esophagus and crop, with occasional spread to the conjunctiva and nasal sinuses. In addition, those lesions may extend into the skull and through the surrounding tissues of the neck (1, 2, 4, 5). Morphologically in culture plates, *T. gallinae* is distinguished by its ovoidal to pyriform shape, four flagella and characteristic fifth flagella attached to the surface, giving an aspect of an “undulating membrane” (1, 3).

Transmission of *T. gallinae* occurs through direct contact with contaminated birds or indirectly via contaminated fomites or water. The pathogenesis is related to protozoan attachment to superficial epithelium, release of hydrolytic enzymes that destroy cell junctions and

enable to invasion into deeper tissues, with consequent severe mixed inflammatory infiltrate of leukocytes (2, 4, 5). The classic gross lesion in the upper digestive tract is characterized by ulcerated mucosa, formation of large friable masses of caseous necrosis, yellow-tan and malodorous.

Microscopically there is an ulcerated epithelium with necrotic cellular debris and fibrino-heterophilic exudate admixed with *T. gallinae* and secondary bacteria colonies (1, 4).

Affected animals often become anorexic and recumbent, and die due starvation, predation or by opportunistic bacteria such as *E. coli*, leading to terminal septicemia (2, 4, 5).

Diagnosis is achieved by demonstration of the parasite within the necrotic lesions, mainly via wet mount; however to achieve a proper diagnostic, it needs to be performed using fresh tissues from live animals. Histopathologic analysis also requires timely specimen collection after death and factors such as poorly fixed or

autolyzed tissues and chronicity of the lesion make the interpretation difficult to impossible (1, 4, 5). Gomori methenamine silver staining is sometimes useful in identifying *T. gallinae* in histologic sections (1, 4).

Case Report

An adult, male Rock Pigeon (*Columba livia*) exhibiting signs of weakness and recumbence was found by a pedestrian in a city square and was referred to the Veterinary Hospital at Universidade Estadual Paulista (UNESP) in Araçatuba. The animal was in poor body condition and died during physical examination shortly after arrival at the hospital. At necropsy, a focally extensive, 2 cm in diameter, white-yellow mass with an irregularly roughened, friable surface and putrid odor was found on the mucosa of the hard palate and extending into the oropharynx (Figure 1). No significant gross lesions were found in any of the remaining organs

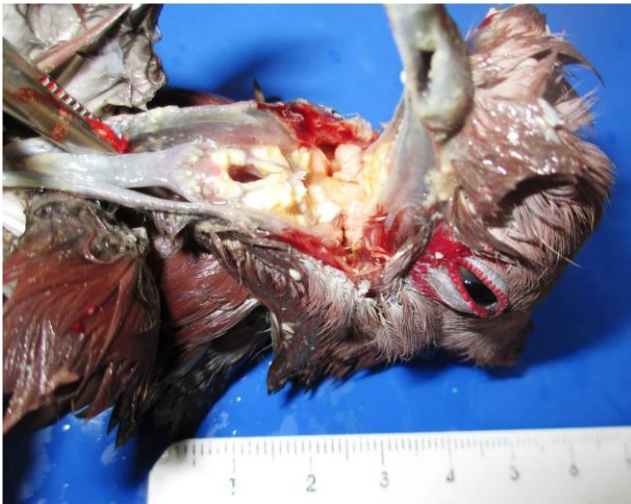

Figure 1. Rock Pigeon (*Columba livia*) exhibiting a focally extensive mass in the oral cavity.

Impression smears were taken from the surface of the oral mass and were routinely processed using Romanowsky stain (Diff-Quick) for cytological examination. The impression smears of the oral mass revealed numerous basophilic, 10 x 7 μm , elongated to pyriform protozoa with multiple flagella and a conspicuous undulating membrane, that were surrounded by a large amount of amorphous necrotic material, cellular debris, squamous epithelial cells and numerous coccobacilli (Figure 2). Morphology of the protozoa was compatible with *Trichomonas gallinae*, according to Mehlhorn et al. (3), allowing the diagnosis of oral trichomoniasis.

Tissues collected at necropsy were fixed in 10% neutral buffered formalin and were routinely embedded and stained with H&E. Histopathology revealed a large amount of fibrinoheterophilic exudate and necrosis extending full-thickness through the mucosa deeply into the underlying pharyngeal skeletal muscle. However,

protozoans were not easily evident within the chronic lesions in the Hematoxylin and Eosin or Gomori methenamine silver (GMS) stained sections.

Cytopathologic analysis was helpful for the definitive diagnosis and was the only method that demonstrated *T. gallinae* in the present case. Our findings indicate that obtaining impression smears from avian oral trichomoniasis suspects, even during post-mortem evaluation, can be valuable for the diagnosis of this disease.

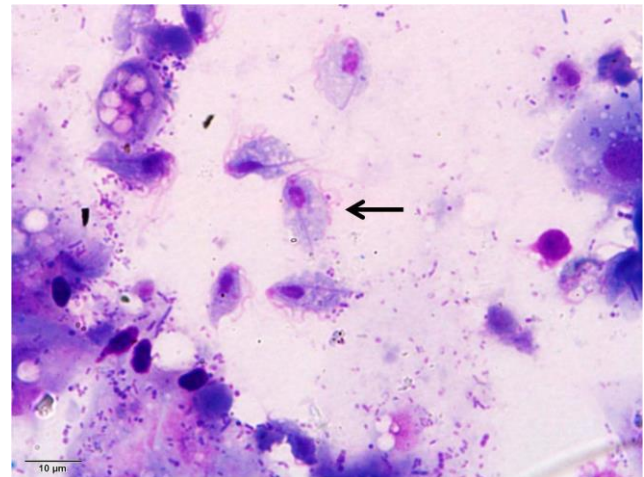


Figure 2. Impression smear from a mass within the oral cavity of an urban pigeon (*Columba livia*), showing numerous pyriform protozoa compatible with *Trichomonas gallinae* (arrow). Diff-Quick staining, 100x objective.

References

1. BORJI H., RAZMI GH., MOVASSAGHI AH., MOGHADDAS E., AZAD M. Prevalence and pathological lesions of *Trichomonas gallinae* in pigeons of Iran. **J. Parasit. Dis.**, 2011, 35, 186-9.
2. FLETCHER OJ., ABDUL-AZIZ T., BARNES HJ. Alimentary system. FLETCHER, OJ., ABDUL-AZIZ., T. MADISON, WI. Eds. **Avian histopathology**, 3 ed. American Association of Avian Pathologists-Omni Press, 2008: 164-201.
3. MEHLHORN H., AL-QURAI SHY, S., AZIZA, A., HESS, M. Fine structure of the bird parasites *Trichomonas gallinae* and *Tetratrichomonas gallinarum* from cultures. **Parasitol. Res.**, 2009, 105, 751-6.
4. NEIMANIS AS., HANDELAND K., ISOMURSU M., AGREN E., MATTSSON R., HAMNES IS., BERGSJO B., HIRVELA-KOSKI. First report of epizootic trichomoniasis in wild finches (Family Fringillidae) in Southern Fennoscandia. **Avian Dis.**, 2010, 54, 136-41.
5. WERTHER, K. 2007. Columbiformes (Pomba, Rolinha, Avoante, Juriti). CUBAS ZS., SILVA JCR., CATÃO-DIAS JL. **Tratado de animais selvagens – medicina veterinária**, Roca: São Paulo, 2008: 268-89.