



Case Report

Primary Cerebral Hemangiosarcoma in an Adult Labrador Retriever Dog

Adam W. Stern^{1*}

¹Veterinary Diagnostic Laboratory, University of Illinois, Urbana, USA

* Corresponding Author: E-mail: awstern@illinois.edu

Submitted October 10th 2014, Accepted October 15th 2014

Abstract

A 6-year-old, castrated male, Labrador Retriever dog presented to the referring veterinarian for acute onset of lethargy. Clinical examination revealed hyperesthesia of the face and blindness in the right eye. The animal died in the hospital and was submitted for postmortem examination. At postmortem examination, a dark red mass (2.0 cm x 1.8 cm x 1.6 cm) had infiltrated the right frontal lobe of the cerebrum. Microscopically, the tumor was composed of small caliber vascular channels lined by neoplastic endothelial cells. Immunohistochemical staining revealed widespread expression of CD31 and the absence of pan-cytokeratin expression in neoplastic cells. The diagnosis of primary cerebral hemangiosarcoma was made. The brain is a rare primary site for hemangiosarcoma in the dog.

Key words: neoplasia, hemangiosarcoma, dog, brain.

Introduction

Canine hemangiosarcoma is a commonly reported malignancy. Primary sites of hemangiosarcoma include the spleen, soft tissue of the trunk or extremities, liver, right atrium of the heart, lung and spleen (1, 10). Rare primary sites for hemangiosarcoma in the dog include the kidney and brain (4, 7). In the dog there are rare case reports of primary hemangiosarcoma in the brain including the cerebrum of a 6-week-old dog and a dog of unknown age and in the brain stem of an 11-year-old dog (3, 4). Hemangiosarcoma is often associated with metastatic disease with metastatic lesions being reported to the brain (9). This report described the clinical and pathologic findings of a rare case of primary cerebral hemangiosarcoma in an adult dog.

Case report

A 6-year-old, castrated male, Labrador Retriever dog presented to the referring veterinarian for acute onset lethargy. On clinical examination the dog was noted to

have hyperesthesia of the face, was blind in the right eye and had absent pupillary light reflexes both direct and consensual of the right eye. The remainder of the clinical examination was unremarkable. No known historical medical abnormalities such as previous mass removal were identified. A complete blood cell count revealed a normal white blood cell count (11.1×10^3 cells/ μL ; ref. range: $3.0\text{--}17.0 \times 10^3$ cells/ μL) with decreased numbers of lymphocytes (0.732×10^3 cells/ μL ; ref. range: $1\text{--}4.8 \times 10^3$) and eosinophils (0.055×10^3 cells/ μL ; ref. range: $0.1\text{--}1.0 \times 10^3$ cells/ μL). Erythrocyte parameters were within normal limits and included a hematocrit of 49.4% (ref. range: 35–52%). Serum biochemistry abnormalities included hyperphosphatemia (5.4 mg/dL; ref. range: 2.7–5.2 mg/dL), increased total alkaline phosphatase (127 U/L; ref. range: 7–92 U/L) and corticosteroid-induced alkaline phosphatase (93 U/L; ref. range: 0–40 U/L). A urinalysis was performed and was unremarkable. Chest radiographs and abdominal ultrasound were performed and no significant abnormalities were detected. The animal was reported to have had a seizure while in the hospital. During the overnight hours while being monitored the

patient went into cardiac arrest and died. The animal was submitted for postmortem examination.

At necropsy, the dog was in adequate nutritional condition. There are multiple small nodules within the cortex of the left and right adrenal glands (nodular hyperplasia). Intracranially, a dark red mass (2.0 cm x 1.8 cm x 1.6 cm) infiltrated the right frontal lobe of the cerebrum. On cut section there was accumulation of small friable strands of red material. The adjacent meninges had regions of hemorrhage. The cribriform plate and the nasal turbinates were not affected. No other significant pathologic lesions were observed.

Samples were collected from various organs including the brain; fixed in 10% neutral buffered formalin; and processed by routine methods (i.e., embedded in paraffin wax, sectioned at 4-5 μ m, and stained with hematoxylin and eosin). Immunohistochemistry was performed for pan-cytokeratin and CD31, according to the manufacturer's instructions (Table 1).

Microscopic examination revealed a locally extensive region of hemorrhage within the neuropil and an infiltrative and unencapsulated neoplasm within the regions of hemorrhage. Neoplastic cells formed blood filled vascular channels and were supported by a scant fibrous stroma (Figure 1). Neoplastic cells had indistinct cell margins, had an ovoid nucleus, stippled chromatin and 1-2 nucleoli. There was moderate anisocytosis and

anisokaryosis. There were 3 mitotic figures within 10 random 400x fields. There was multifocal fibrin accumulation and thrombosis of vascular channels within the neoplasm. Neutrophils, lymphocytes, plasma cells, and histiocytes infiltrated the adjacent subarachnoid space, gray matter, and white matter and there are associated regions of necrosis of the cerebrum. The neoplastic cells had extensive positive cytoplasmic immunoreactivity for CD31 (Figure 2). Pan-cytokeratin immunohistochemical staining was negative. The morphologic and immunohistologic profile of the neoplastic cells was most compatible with a mesenchymal neoplasm of vascular origin, leading to a final diagnosis of primary cerebral hemangiosarcoma based on the infiltrative nature of the neoplastic cells and cellular pleomorphism.

Clinical differential diagnoses for hyperesthesia of the face, blindness, and absent pupillary light reflexes include infectious disease such as blastomycosis and canine distemper virus infection, non-infectious diseases such as canine steroid responsive-meningoencephalitis, toxicities such as mercury intoxication and cocaine intoxication and neoplasia. Differential diagnoses for a mass within the brain include astrocytoma, meningioma, oligodendroglioma, ependymoma, and choroid plexus tumors (5). In the brain astrocytomas and meningiomas are the most commonly reported neoplasms with meningioma being the most common primary neoplasm in the dog brain (5).

Table 1: Primary antibodies, clonality, dilution, and immunohistochemical staining results of the primary cerebral hemangiosarcoma.

Antibody	Manufacturer	Clonality	Pretreatment and dilution	Tumor cells
Pan-cytokeratin	BioGenex	AE1/AE3	Predilute, antigen retrieval pH 6.0	-
CD31	Dako	JC70A	Protease, 1:100	+

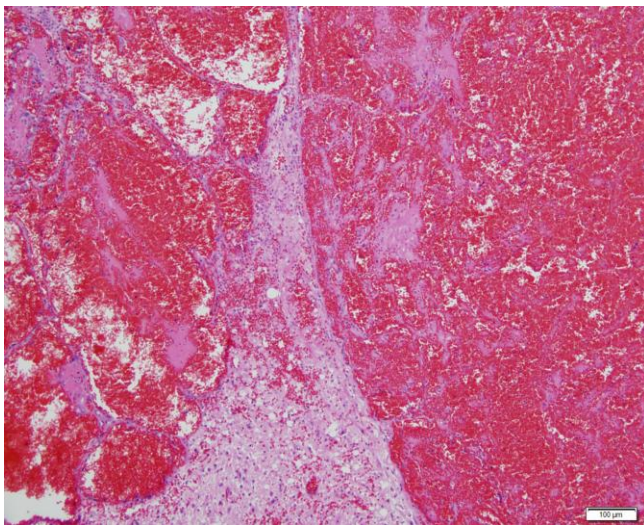


Figure 1. Histopathology of the cerebrum. Neoplastic cells form multiple blood filled vascular channels. Hematoxylin and eosin.

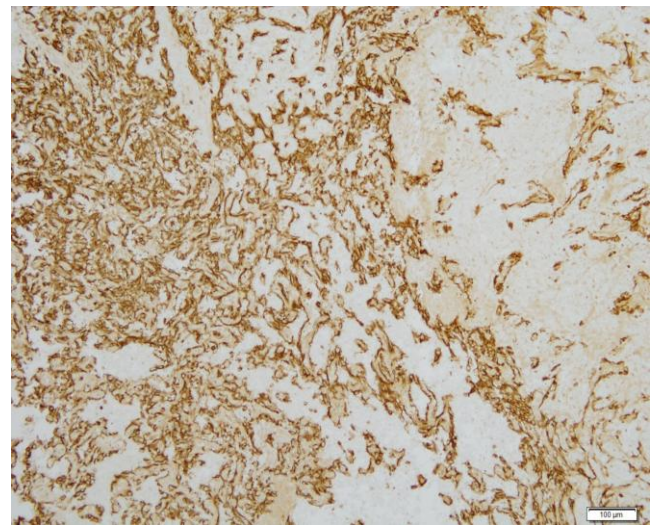


Figure 2. Immunohistochemistry of the cerebrum. Neoplastic cells are positive for CD31.

Vascular neoplasms in the dog are rarely reported as primary lesions within the brain. Metastatic brain lesions have been reported in cases of canine hemangiosarcoma (2, 8, 11). In one study, intracranial lesions in 85 dogs with hemangiosarcoma were reviewed and 12 dogs (14.2%) had metastatic lesions in the brain and dogs with metastatic lesions in the lungs were at a higher risk of having metastatic lesion in the brain (11). There is a variant of meningioma known as angiomatous meningioma which histologically differs from hemangiosarcoma, as this variant of meningioma contains numerous large and small blood vessels mixed with nests of meningeal cells (6). Angiomatous meningioma is rarely reported in the dog (6).

Primary intracranial hemangiosarcoma has rarely been reported in the veterinary literature. In these cases the sites of localization included rostral cerebrum and brain stem (3, 4). Metastatic hemangiosarcoma of the brain has been reported in a horse and a bull (10), but no reports in the literature of primary brain lesions have been reported in these species. A single case of a meningeal hemangiosarcoma was reported in a pig (10). This report shows that primary cerebral hemangiosarcoma, although extremely rare, should be on the differential list for cases of suspected intracranial neoplasia.

References

1. BROWN NO., PATNAIK AK., MACEWEN EG. Canine hemangiosarcoma: retrospective analysis of 104 cases. **J. Am. Vet. Med. Assoc.**, 1985, 186, 56-58.
2. CHERUBINI GB., MANTIS P., MARTINEZ TA., LAMB CR., CAPPELLO R. Utility of magnetic resonance imaging for distinguishing neoplastic from non-neoplastic brain lesions in dogs and cats. **Vet. Radiol. Ultrasound.**, 2005, 46, 384-387.
3. FOSTER ES., CARRILLO JM., PATNAIK AK. Clinical signs of tumors affecting the rostral cerebrum in 43 dogs. **J. Vet. Intern. Med.**, 1988, 2, 71-74.
4. GABOR LJ., VANDERSTICHEL RV. Primary cerebral Hemangiosarcoma in a 6-week-old dog. **Vet. Pathol.**, 2006, 43, 782-784.
5. KOESTNER A., BILZER T., FATZER R., SCHULMAN FY., SUMMERS BA., VAN WINKLE TJ. **Histological classification of tumors of the nervous system of domestic animals**. Washington DC: Armed Forces Institute of Pathology, 1999.
6. KOESTNER A., HIGGINS RJ. Tumors of the nervous system. MEUTEN DJ. (Ed). **Tumors in Domestic Animals**. 4.ed. Blackwell, Ames 2002: 697-738.
7. LOCKE JE., BARBER LG. Comparative aspects and clinical outcomes of canine renal hemangiosarcoma. **J. Vet. Intern. Med.**, 2006, 20, 962-967.
8. LOWRIE M., DE RISIO L., DENNIS R., LLABRÉS-DÍAZ F., GAROSI L. Concurrent medical conditions and long-term outcome in dogs with nontraumatic intracranial hemorrhage. **Vet. Radiol. Ultrasound.**, 2012, 53, 381-388.
9. SNYDER JM., LIPITZ L, SKORUPSKI KA, SHOFER FS, VAN WINKLE TJ. Secondary intracranial neoplasia in the dog: 177 cases (1986-2003). **J. Vet. Intern. Med.**, 2008, 22, 172-177.
10. SPITZBARTH I., PETERS M., STAN AC., WOHLSEIN P. Primary meningeal hemangiosarcoma in a grower pig. **J. Vet. Diagn. Invest.**, 2011, 23, 162-167.
11. WATERS DJ., HAYDEN DW., WALTER PA. Intracranial lesions in dogs with hemangiosarcoma. **J. Vet. Intern. Med.**, 1989, 3, 222-230.