BJVP
Brazilian Journal of Veterinary Pathology
ISSN 1983-0246

Case Report

Synchronous Multicentric Osteosarcoma in the Canine Axial Skeleton: a Report of Two Cases

Matheus V. L. Moreira[1], Juneo F. Silva[1], Jankerle N. Boeloni[1], Natalia M. Ocarino[1], Rogéria Serakides[1*]

[1]Departamento de Clínica e Cirurgia Veterinárias, Escola de Veterinária, Universidade Federal de Minas Gerais, Belo Horizonte, MG, Brazil.
*** Corresponding Author:** Rogéria Serakides, Departamento de Clínica e Cirurgia Veterinárias, Escola de Veterinária, UFMG, Universidade Federal de Minas Gerais, Av. Presidente Antônio Carlos, 6627 – CEP: 30.161-970, Belo Horizonte, MG, Brazil. E-mail: serakidesufmg@gmail.com

Submitted September 28th 2014, Accepted November 08th 2014

Abstract

Two cases of axial synchronous multicentric osteosarcoma are described in male dogs 11 and 13 years of age. In both cases, the necropsy revealed multiple tumor nodules or masses in the thoracic vertebrae and ribs. The microscopic features indicated that the masses were osteoblastic osteosarcoma for all bone sites with immunohistochemical expression of vimentin and osteocalcin and the absence of cytokeratin. In both cases, multicentric osteosarcoma was considered to be present simultaneously in various bone sites of the axial skeleton, to be of the same histological type and to exhibit the same immunohistochemical characteristics in all bone sites, with no macroscopic or microscopic metastases to the lungs or any other soft tissue.

Key-words: osteosarcoma, axial skeleton, multicentric, dog.

Introduction

Osteosarcoma is the most common malignant mesenchymal tumor of the appendicular skeleton of dogs, with a high potential to generate metastases, especially to the lungs (8, 9). Approximately 80% of primary bone neoplasms in dogs are osteosarcomas, affecting animals with greater frequency between 7.5 and 8 years old. With respect to osteosarcoma of the appendicular skeleton, males are more often affected than females. In the axial skeleton, the incidence of osteosarcoma is three to four-fold that of the appendicular skeleton (4, 9). Approximately 50% of cases of axial osteosarcoma involve the bones of the head, and the remaining 50% involve the ribs, vertebrae and pelvis (9).

Osteosarcoma is considered multicentric or multifocal when there is simultaneous involvement of two or more sites without metastases in soft tissues, mainly in the lungs (5). This presentation is rare in humans (1, 2, 10) and has not been described in animals. In humans, multicenter osteosarcoma can be synchronous or metachronous (5). The disease is considered synchronous when there are concurrent neoplasias over a bone site at diagnosis (1, 5). However, if only new bone tumors arise after treatment of primary bone neoplasia, osteosarcoma is classified as metachronous multicentric (2, 5). The purpose of this article is to describe two cases of synchronous multicentric osteosarcoma in canine axial skeleton.

Cases report

In the first case, a 13-year-old male Rottweiler was referred to the Veterinary Hospital at the *Universidade Federal de Minas Gerais* (UFMG), Brazil, for necropsy. According to the owner, the animal could not stay stationary, and in light of radiological suspicion of a vertebral bone tumor, the animal was euthanized. No surgical resection or chemotherapy was performed before euthanasia.

At necropsy, nodules were observed in the 4th, 5th, 6th and 7th left ribs and in the 4th, 7th and 9th right ribs. The nodules ranged in size from 1.2 to 2.0 cm in

 All rights reserved 2007.

diameter and were whitish, some friable and some firm, and were associated with focal fragility bone. Some nodules occluded the entire medullary canal of the rib and extended to the cortex with slight protrusion into the thoracic cavity (Fig. 1A). In the body of the T3, T4 and T5 thoracic vertebrae, there were nodules ranging from 1.0 to 2.0 cm in diameter; the nodules were whitish, with some firm and friable areas (Fig. 1B). In the spinous process of the T4 vertebra, there was a nodule 1.5 cm in diameter with similar characteristics to the other nodules. Between the third and fourth thoracic vertebrae, ankylosing spondylitis was also observed. The other vertebrae, skull, bones of the pelvis and long bones were sawed and analyzed, but no significant change was observed. Fragments of the bones and organs of the abdominal and thoracic cavities, including lymph nodes, were collected and fixed in 10% neutral phosphate-buffered formalin, embedded in paraffin, and cut into 5-µm sections. The sections were stained with hematoxylin and eosin.

Microscopically, the nodules of the ribs and vertebrae exhibited similar characteristics. The nodules were formed by the proliferation of mesenchymal neoplastic cells that were poorly defined, unencapsulated and invasive. The tumor invaded the cortical bone in some areas and extended to the periosteum. The neoplastic cells were organized in a solid pattern and were polygonal or spindle-shaped, with eosinophilic cytoplasm and poorly defined cytoplasmic limits. The nuclei were oval or elongated, with loose chromatin and multiple prominent nucleoli. In some areas, the neoplastic cells surrounded or were within a homogeneous and eosinophilic matrix (osteoid matrix), which was sometimes mineralized. Moreover, there was intense anisocytosis and anisokaryosis, multinucleated giant cells, and rare mitotic figures per field in the 40x objective (Fig. 1C). Multifocal to coalescing areas of necrosis and hemorrhage were also observed. In the periosteal region, adjacent to the area of neoplastic invasion, focally extensive areas of reactive bone formation were observed with fibroplasia and lymphocytic inflammatory infiltration discreet. The other organs exhibited no significant microscopic changes.

The second case, an 11-year-old male Akita was referred to the Veterinary Hospital at the *Universidade Federal de Minas Gerais* (UFMG), Brazil, for necropsy. According to the owner, the animal was euthanized after developing hind limb paralysis and a tumor mass involving the ribs on the right side. No surgical resection or chemotherapy was performed before euthanasia.

At necropsy, the animal exhibited poor nutritional status, moderate pallor of the ocular and oral mucosa and moderate atrophy of the muscles of the pelvic limbs. A whitish mass 16 x 10 x 8 cm was located between the 1st and 8th right ribs and was characterized by a smooth surface and was interspersed with soft and firm areas that jutted out and into the chest cavity. When cut, the mass exhibited whitish yellow mass with cavities of varying diameters filled with blood interspersed with harsh creaking cutting areas (Fig. 2A).

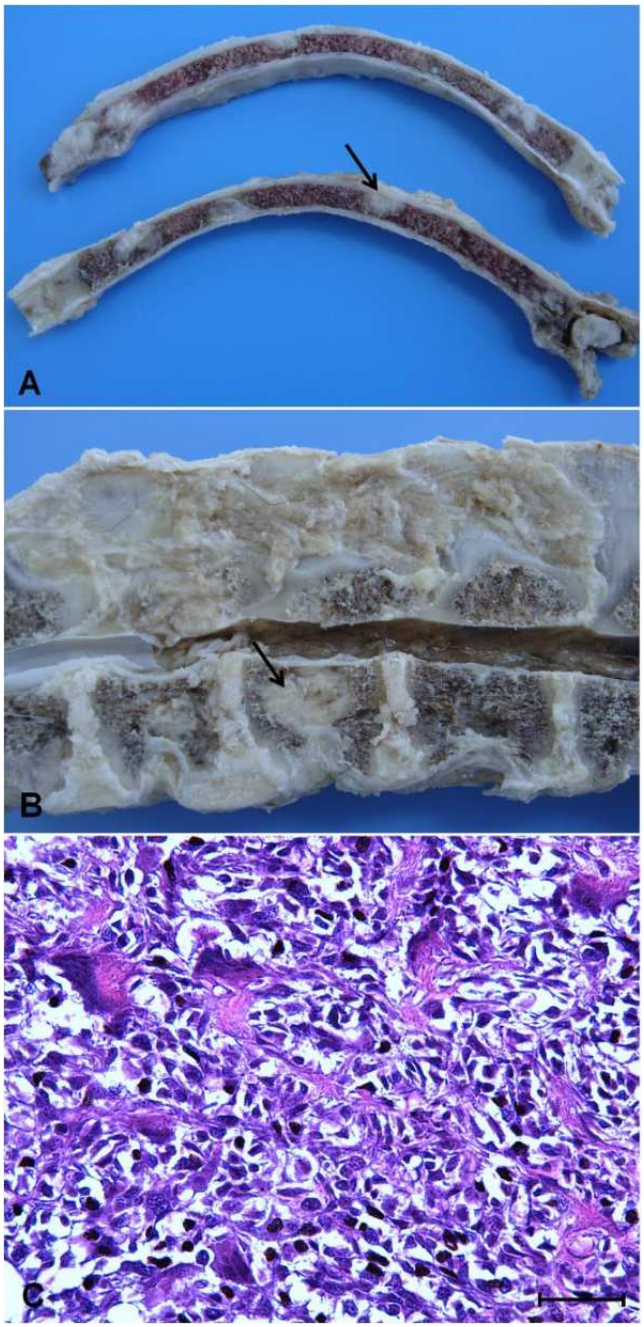

Figure 1. Axial multicentric osteosarcoma in a dog. A) Ribs containing multifocal whitish nodules varying from 1.2 to 2.0 cm in diameter in the medullary canal. Some nodules extended into the cortex (arrow). B) Vertebral body of the T3, T4 and T5 vertebrae with whitish nodules 1.0 to 2.0 cm in diameter (arrow). C) Photomicrograph of B demonstrating neoplastic proliferation of mesenchymal cells, polyhedral to fusiform, with multinucleated giant cells surrounding eosinophilic and homogeneous material (osteoid matrix). HE. Bar = 32 µm.

The 2nd and 3rd ribs on the right side exhibited spontaneous complete and closed fractures. Nodules were identified in the T1, T2, T3, T7, T8 and T9 vertebral bodies that were poorly demarcated, reddish white, measuring 1.0 to 1.5 cm in diameter with a friable center (Fig. 2B). Some of these nodules protruded into the canal with spinal cord compression. There was intense compressive atelectasis of the right cranial lobe. The other vertebrae, skull, pelvis and long bones were sawed and analyzed, but no significant change was observed. Fragments of the bones and organs of the abdominal and thoracic cavities, including lymph nodes, were collected and fixed in 10% neutral phosphate-buffered formalin, embedded in paraffin, and cut into 5-µm sections. The sections were stained with hematoxylin and eosin.

Microscopically, the neoplasms of the ribs and vertebrae exhibited proliferation of mesenchymal neoplastic cells and poorly defined limits and were unencapsulated and invasive. The neoplastic cells were arranged in a solid pattern and were polygonal or spindle-shaped, with eosinophilic cytoplasm and poorly defined cytoplasmic limits. The nuclei were oval or elongated, with loose chromatin and multiple prominent nucleoli. In some areas, the neoplastic cells surrounded or were within a homogeneous and eosinophilic matrix (osteoid matrix), which was sometimes mineralized. Moreover, there was intense anisocytosis and anisokaryosis, multinucleated giant cells and rare mitotic figures per field at 40x objective (Fig. 2C). Multifocal to coalescing necrosis, hemorrhage and discrete areas of lymphohistiocytic inflammatory infiltrate were observed. The other organs exhibited no significant microscopic changes.

In both cases, immunohistochemistry for vimentin (1:100) (V9, Dako, CA, USA), cytokeratin AE1/AE3 (1:200) (Clone AE1-AE3, Dako, St Louis, MO, USA), and osteocalcin (1:30) (AB13418, Abcam, Cambridge, UK) were also performed using the streptavidin-biotin-peroxidase technique (Streptavidin Peroxidase, Lab Vision Corp., Fremont, CA, USA). Histological sections were incubated overnight in a humid chamber with primary antibody and endogenous peroxidase was blocking by incubation in blocking serum (Ultra Vision Block, Lab Vision Corp., Fremont, CA, USA) and streptavidin peroxidase for 30 minutes. Incubation with the secondary antibody (goat biotin, Lab Vision Corp., Fremont, CA. USA) was performed for 45 minutes. The chromogen utilized was diaminobenzidine (DAB substrate system, Lab Vision Corp., Fremont, CA. USA). Sections were counterstained with Harris hematoxylin. A negative control was obtained by replacing the primary antibodies with IgG (31235, Thermo Scientific, Waltham, USA). Fragments of bone neoplasms in both cases were strongly and diffusely positive for vimentin (Fig. 3A and B), focally positive for osteocalcin (Fig. 3C) and negative for cytokeratin.

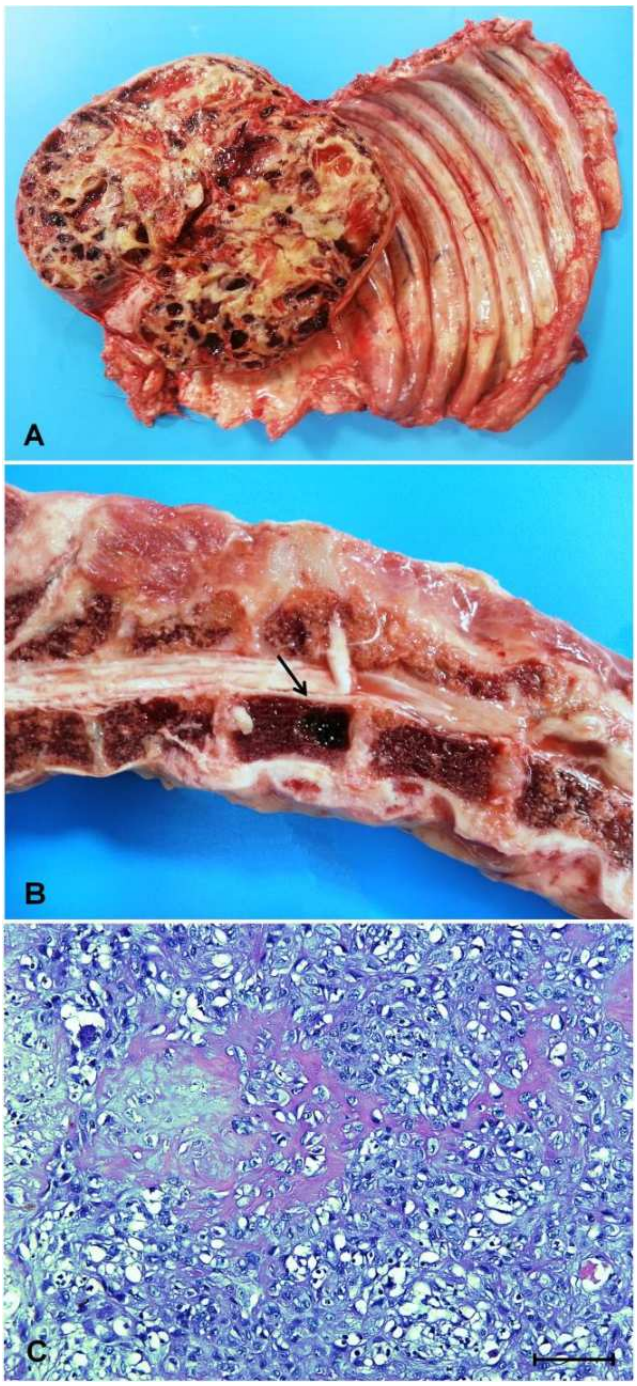

Figure 2. Axial multicentric osteosarcoma in a dog. A) Cutting surface mass of 16x10x8 cm between the 1st and 8th right ribs revealing cavitary areas filled with blood interspersed. B) Vertebral body of a thoracic vertebra with a poorly defined reddish area 1.5 cm in diameter with a friable center (arrow). C) Photomicrograph of a revealing neoplastic proliferation of mesenchymal cells, polyhedral to fusiform, with multinucleated giant cells surrounding eosinophilic and homogeneous material (osteoid matrix). HE. Bar = 32 µm.

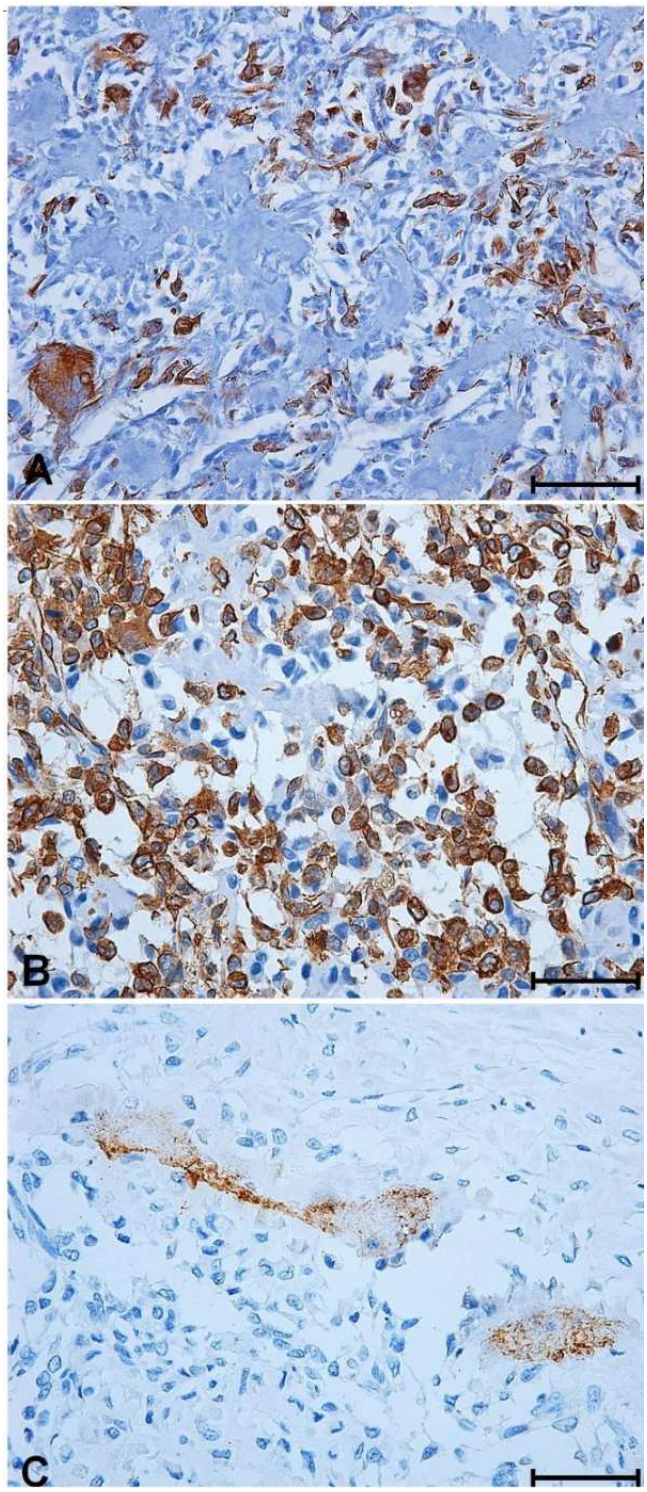

Figure 3. Axial multicentric osteosarcoma in two dogs. A) Immunostaining for vimentin positive in the cytoplasm of neoplastic cells of the nodule from the vertebral body. B) Immunostaining for vimentin positive in the cytoplasm of neoplastic cells of the thoracic mass. C) Immunostaining for osteocalcin positive in the osteoid matrix of the thoracic mass. Streptavidin-biotin-peroxidase, Harris hematoxylin, scale bar = 32 µm.

Based on the gross and microscopic findings in both cases, the diagnosis of osteoblastic osteosarcoma synchronous multicentric in axial skeleton was confirmed.

There is significant debate in the literature concerning whether this tumor represents multiple primary tumors or metastatic disease (1, 5, 6, 7). However, osteosarcoma bone metastases in the absence of involved soft tissues are rare (8). Therefore, to be considered multicenter osteosarcoma, certain requirements must be met, including the absence of metastases in the lungs and other soft tissue (2) and similar histological characteristics in all coexisting bone neoplasms (3). In both cases, the osteosarcoma was considered multicentric and to have affected the thoracic vertebrae and ribs. The osteosarcoma was of the osteoblastic type, with the same immunohistochemical characteristics in all bone sites and without macro- or microscopic metastases to the lungs or any other soft tissue. In one case, the neoplasm of ribs was much larger than that of the vertebrae. However, multicenter human osteosarcoma may manifest as a symmetrical neoplasia, with similar sizes, or may exhibit one asymmetric neoplasm larger than the others (6), as observed in the first and second case, respectively.

In addition to its multicentric nature, these cases of osteosarcoma were considered synchronous because the bone tumors were observed prior to any surgery or chemotherapy treatment, unlike metachronous neoplasia, where new bone tumors may arise after treatment of the primary site (2, 5).

The present study is the first report of multicentric osteosarcoma in dogs. However, it is important to recognize that a proper diagnosis requires a clinical examination and thorough necropsy of the entire skeleton. It is important to note that in the first case, the ribs exhibited discreet bumps along the periosteum and that neoplastic nodules were detected only in longitudinal sections.

References

1. BACCI G., FABBRI N., BALLADELLI A., FORNI C., PALMERINI E., PICCI P. Treatment and prognosis for synchronous multifocal osteosarcoma in 42 patients. **J. Bone Joint Surg.**, 2006, 88-B, 1071-1075.
2. BELUFFI G., PAZZAGLIA U., MORA R. Synchronous multicentric osteosarcoma. **Pediatr. Radiol.**, 1983,13, 292-293.
3. BUZZONI R., TORRE SD., CORTINOVIS D., CATENA L. Case report of synchronous multicentric osteosarcoma and review of the literature: the importance of autopsy for diagnosis. **Tumori**, 2005, 91, 90-92.
4. CAVALCANTI JN., AMSTALDEN EMI., GUERRA JL., MAGNA LC. Osteosarcoma in dogs: clinical-morphological study and prognostic correlation. **Braz. J. Vet. Res. Anim Sci.**, 2004, 41, 299-305.

5. CURRALL VA., DIXON JH. Synchronous Multifocal Osteosarcoma: Case Report and Literature Review. **Sarcoma**, 2006: 53901, 1-3.
6. DAFFNERRH., KENNEDY SL., FOX KR., CROWLEY JJ., SAUSER DD., COOPERSTEIN LA. Synchronous multicentric osteosarcoma: the case for metastasis. **Skeletal Radiol.**, 1997, 26, 569-578.
7. HAMEED S., VIJAYAN S., NAIK M., RAO S. Multicentric osteossarcoma. **Singapore Med. J.**, 2012, 53, 10, 214-217.
8. THOMPSON KG., POOL RR. Tumors of Bones. In: MEUTEN DJ. **Tumors in Domestic Animals**. 4.ed. Iowa: Iowa State Press, p.266-283, 2002.
9. THOMPSON K. Bones and Joints. In: JUBB KVF., KENNEDY PC., PALMER NC. **Pathology of domestic animals**. 5.ed. Philadelphia: Elsevier, v.1, p.112-118, 2007.
10. YAMAMOTO T., FUJITA I. A boy with bilateral hip pain. **Br. J. Radiol.**, 2002, 75, 898, 853-854.

 All rights reserved 2007.