BJVP
Brazilian Journal of Veterinary Pathology
ISSN 1983-0246

Case Report

Congenital Cerebellar Vermis Aplasia Associated with Hydrocephalus in a Foal

Matheus V. L. Moreira, Iolanda G. Kassem, Maristela S. Palhares, Renata P. A. Maranhão, Roselene Ecco*

Department of Veterinary Clinic and Surgery, Veterinary School, Universidade Federal de Minas Gerais, Belo Horizonte, MG, Brazil.
***Corresponding author:** Roselene Ecco, Departamento de Clínica e Cirurgia Veterinárias, Escola de Veterinária, Universidade Federal de Minas Gerais (UFMG), 30123-970 Belo Horizonte, MG, Brazil. Tel.: +55 31 3409-2261. E-mail: eccoro.ufmg@gmail.com

Submitted November 22nd 2014, Accepted December 23rd 2014

Abstract

A 2-day-old Mangalarga Marchador colt was presented with clinical signs of severe mental depression, unable to stand, and lacking a suckling reflex. Despite intensive medical care, there was no improvement and the colt died 30 hours later. Gross lesions were characterized by aplasia of the cerebellar vermis, cystic dilatation of the fourth ventricle, communicant hydrocephalus involving all ventricles and villous hyperplasia of the choroid plexus in the fourth ventricle. The cerebral parenchyma adjacent to lateral ventricles was markedly reduced. In addition, there was aspiration pneumonia. Aplasia of the cerebellar vermis and cystic dilatation of the fourth ventricle could be compared to the Dandy-Walker-syndrome (DWS). Nevertheless, congenital cerebellar anomalies combined with villous hyperplasia of the choroid plexus in the fourth ventricle and hydrocephalus are describing for the first time in animals, alerting clinicians and pathologists for future investigations about the incidence and etiology of the condition.

Key words: colt, cerebellar vermis aplasia, choroid plexus hyperplasia, hydrocephalus.

Introduction

Cerebellar defects have been described in several animal species and are among the more important anomalies of the central nervous system. The most common congenital malformations include hypoplasia, abiotrophy (atrophy) and dysplasia. In the Arabian foal, cerebellar abiotrophy is the most reported and studied congenital malformation and is believed to be a hereditary genetic mutation (4). Congenital hydrocephalus is reported in many animal species and is characterized by abnormal accumulation of cerebrospinal fluid (CSF) within the ventricles (internal or obstructive), in the arachnoid space (external or non-obstructive) or in both locations (communicating) (4). Dandy Walker Syndrome (DWS) is a condition in children where the defects consist of partial or complete absence of cerebellar vermis, together with a cystic dilatation of the roof of the four ventricle, and communicating hydrocephalus (8). In children (2) and colt (9) agenesis of corpus callosum has also been associated with this syndrome. Diffuse villous hyperplasia of the both lateral choroid plexus (DVHCP) has been described in children, and has been associated with hydrocephalus (8). This report describes a case of congenital cerebellar malformation associated with villous hyperplasia of the choroid plexus in the fourth ventricle and hydrocephalus in a colt.

Case report

A 2-days-old male Mangalarga Marchador foal was presented to the Veterinary Hospital at Universidade Federal de Minas Gerais. The colt was the third born to a seven-year-old mare with no history of previous diseases or the use of medications during this pregnancy. The mare was fed with two to three kg of wheat bran twice daily and *Brachiaria* spp. The owners original complaint was that the foal lacked a suckling reflex, would not take colostrum

 All rights reserved 2007.

at birth, had yellow diarrhea, and was depressed, apathetic, weak and unable to rise. On clinical examination at the veterinary treatment facility, the colt was depressed, in lateral decumbency, unable to either become sternal or stand and lacked a suckling reflex. Rectal temperature was 37.6ºC, heart rate was 120 beats/min and respiratory rate was 40 breaths/min. Hematologic and biochemical analysis from blood collected at the time of admission showed no significant abnormalities. The arterial blood gas analysis revealed slight metabolic acidosis (pH 7.014; reference range, 7.32-7.44 and HCO_3^- 12.6 mEq/L; reference range, 24-30). The treatment included fluids (lactated Ringer's solution and NaCl 0.9%); and equine plasma (800 mL IV once), ceftiofur (3.0 mg/kg IM q24h), oxygen therapy, equine milk (200 mL q2h) plus 50% diluted bovine milk with oat and honey (290 mL, q2h). After feeding via nasoesophageal tube, the colt was manually maintained in sternal position. Despite of the intensive care, the animal regurgitated milk 12 hours after feeding. At this time, the colt was administered bromopride (10 mg IVq 12h). Approximately six hours after admission, the animal showed episodes of excitement, myoclonic paddling movements of legs, alternated with moments of significant mental depression. Precise assessment of proprioception and postural reactions was not possible, because the animal could not stand or ambulate. Despite feeding and medication, there was no clinical improvement. Clinical signs progressed with severe tachycardia and pulmonary crepitation, lethargy, and hypothermia. The colt died 30 hours after admission. A complete necropsy was performed.

At necropsy, relevant findings were observed in the lungs and brain. The cerebral hemispheres were mildly increased in size with several of the cerebral gyri flattened. When touched, the cerebrum had a soft fluctuating feel of a fluid retaining vessel. When the skull was totally removed, a thin membrane adhered to the dura-mater was disrupted allowing abundant cerebral spinal fluid (CSF) to flow out and exposing a markedly dilated fourth ventricle and the absence of the cerebellar vermis. The choroid plexus of the fourth ventricle was significantly enlarged, showing multiple fronds expanded from most part of the floor of this ventricle (Fig. 1). The entire brain was collected and fixed in 10% neutral buffered formaldehyde. Afterward, serial coronal sections (1 to 2 cm thick) were made from the cranial part of the cervical spinal cord through the medulla to the frontal lobe. The lateral ventricles, third ventricle, mesencephalic aqueduct and fourth ventricle were markedly dilated. The cerebral parenchyma adjacent to the lateral ventricles was significantly reduced (atrophied) with the white matter (particularly in the left hemisphere) showing the most significant change (Fig. 2).

The non-collapsed lungs were heavy and wet. Multifocal consolidated dark-red areas in the cranioventral pulmonary regions were observed. On the cut surface, marked firm dark-red areas were interspersed with firm and dry yellowish-white areas with irregular contours. Edema and viscous yellow exudate oozed from the airways including trachea.



Figure 1. Brain; colt. Both hemispheres are depressed with centrally circumvolutions flattened. Also, there is lack of cerebellar vermis exposing a dilated fourth ventricle containing a wide hyperplastic villus choroid plexus.



Figure 2. Serial coronal sections on brain shown in Fig. 1. Note the ventricles and aqueduct markedly distended adjacent to an atrophied parenchyma. Choroid plexus enlarged, showing multiples fronds expanded on the floor of 4th ventricle.

Additional findings in tissues examined at necropsy were the following: cortical adrenal glands had multifocal hemorrhagic areas (petechiae and ecchymosis); the stomach content was creamy white consistent with milk; the intestinal content was liquid and yellowish.

In addition to the brain, a complete set of tissues (heart, lungs, liver, kidney, spleen, adrenal glands, stomach, small, and large intestines) were collected and

fixed in 10% neutral buffered formalin. Tissues were trimmed and embedded into paraffin, sectioned at 5 microns, and stained with hematoxylin and eosin using standard histological procedures.

Analysis of serial sections of the brain from the cranial portions of the cervical spinal cord to the frontal lobe did not have inflammatory changes. The internal surface of all ventricles and aqueduct was composed of attenuated ependymal cells. Vacuolization of the neuropil was present in all areas adjacent to ventricles and aqueduct accompanied with loss of neurons, nerve fibers and glial cells. Remnants of hippocampus were visualized. Small capillaries in the affected areas were observed in the adventitia and media layer in some large blood vessels (Fig. 3). No abnormalities in the lateral cerebellar hemispheres were identified, however, a small remnant of the cerebellar vermis was present at the level of the medullary canal. This portion of the cerebellum showed moderate reduction of neurons in the granular layer. The enlarged choroid plexus was characterized by numerous long villous/papillary projections lined by a single layer of cuboidal cells anchored on a basement membrane and fibrovascular stromal (Fig. 4). The cuboidal cells lining the villous projections were identical to normal choroidal projections and it was interpreted as hyperplasia.

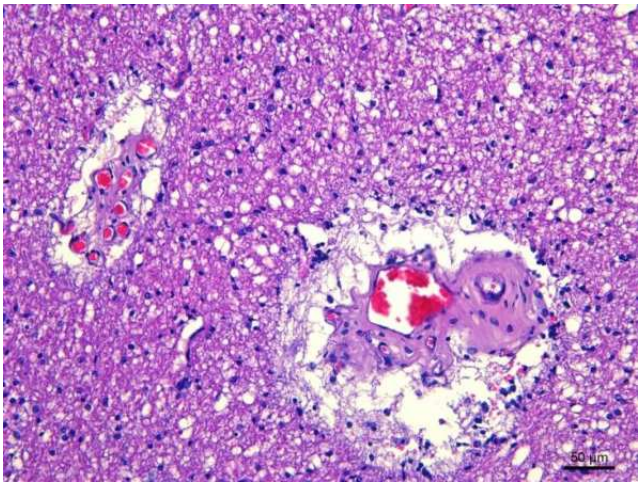

Figure 3. White matter of cerebellum adjacent to the fourth ventricle. There are small capillaries in the adventitia and media layer in some large blood vessels. Hematoxylin and eosin. Bar = 50 µm.

On histological examination, lung lesions were characterized by marked multifocal neutrophilic infiltrates associated with variably sized eosinophilic dropplets (milk) within bronchial and bronchiolar lumen and extending to the adjacent alveoli. These areas often contained abundant necrosis of both bronchioles and parenchyma and were associated with debris, fibrin and large numbers of mixed bacterial colonies associated with the neutrophils. Scattered thrombosis of vessels was observed throughout the affected parenchyma.

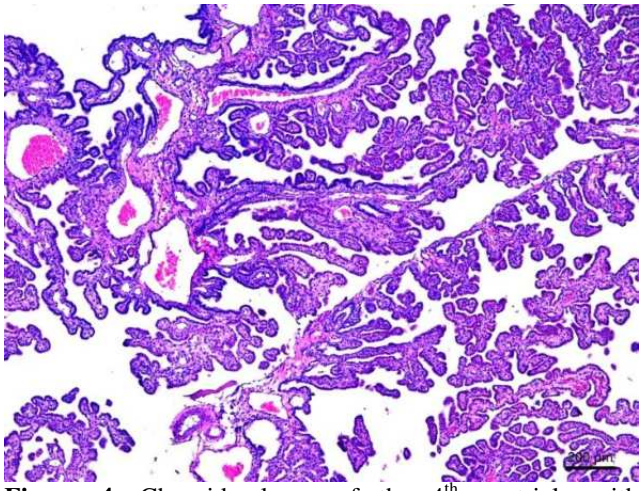

Figure 4. Choroid plexus of the 4th ventricle with numerous elongated villi lined by a single epithelial layer supported on a fibrovascular stroma. Hematoxylin and eosin. Bar = 200 µm.

Discussion

Gross and histopathological findings favored the diagnosis of aplasia of the cerebellar vermis, and villous hyperplasia of the choroid plexus in the fourth ventricle combined with communicating hydrocephalus. These findings can be compared to DWS seen in children, where the primary defect is the partial or total absence of cerebellar vermis associated with cystic dilation of the fourth ventricle (7). Dandy Walker-like syndromes have been described in different animal species including the foal (2, 9), calf (3), lamb (6), and dogs (5). Some theories about the DWS origin, such as infectious agents, toxins and genetic variables have been proposed (9). A likely cause of cerebellar and cerebral malformation could be a primary teratogenic lesion in the alar plate involving the 4th ventricle and the rhombic lips (the future cerebellar hemispheres) (4). Classic DWS in children is often associated with other encephalic (agenesis of the corpus callosum, ectopic cerebellar tissue) or systemic anomalies (heart defect or facial malformations) (7). A few reports in animals also described absence of the corpus callosum and polymicrogyria in a foal (9), and communicating hydrocephalus in a dog associate with absence of the cerebellar vermis (5). However, no other systemic anomalies associated with encephalic anomalies were found in animals. According to Spennato et al. (7), hydrocephalus in DWS is observed in more than 80% of cases in children and generally is absent at birth. Magnetic resonance imaging (MRI) studying the CSF flow dynamics could improve the comprehension of the pathogenesis; detecting persistent cystic arachnoid communicating or not communicating with the forth ventricle; and drainage impediment to the arachnoid space due to the lack of an open foramen (partial or complete) of the fourth ventricle. MRI imagery was not made in the animal of the present report; however, the hydrocephalus could be related to the

hyperplasia in the choroid plexus of the fourth ventricle. However, the stenosis or absence of the foramina between fourth ventricle and subarachnoid space cannot to be excluded. Overproduction of CSF has been associated with hydrocephalus in children (or neonates) with lateral DVHCP (8). Papilloma of the choroid plexus involving the third and fourth ventricles has also been described in association with hydrocephaly, from CSF outflow overproduction and/or obstruction. For congenital cases, plexus-related hydrocephalus is caused by villous hyperplasia and not by neoplasms (8). A study involving 608 fetuses and newborn foals reported the occurrence of 3% of hydrocephalus; however, there is no information about pathophysiology (1). The small capillaries observed in the adventitia and media layer of blood vessels in the affected areas could be a compensatory change, because of the high fluid pressure in the ventricle.

Cerebellar changes (particularly hypoplasia) have been linked with in uterus or early infection in cats, dogs, sheep, bovine and swine with feline panleukopenia virus, canine parvovirus, border disease virus, bovine viral diarrhea virus and classical swine fever virus. However, no infectious agents related to congenital encephalic malformations in foals have been found (4). In sheep, there appears to be a genetic change because three lambs from the same ram were similarly affected (6). Clinical signs related to DWS included abnormal head movements, dysmetria-hypermetria, circling, tremors, respiratory distress and difficulty or inability to stand (2, 9). In the present animal, the aspiration pneumonia was probably associated with the absence or decreased suckling reflex. This defective suckling reflex was possibly related to the lesions of the nuclei of cranial nerves (4).

The present report is the first case in a foal associating congenital aplasia of cerebellar vermis, villous hyperplasia of choroid plexus of the fourth ventricle and communicating hydrocephalus. The condition should be included in differential diagnosis of neurological neonatal conditions in foals and considered for future investigations about the incidence and etiology.

References

1. CROWE MW., SWERCZEK TW. Equine congenital defects. **Am. J. Vet. Res.**, 1985, 46, 2, 353-358.
2. CUDD TA., MAYHEW IG., COTTRILL CM. Agenesis of the corpus callosum with cerebellar vermian hypoplasia in a foal resembling the Dandy-Walker syndrome: pre-mortem diagnosis by clinical evaluation and CT scanning. **Eq. Vet. J.**, 1989, 21, 5, 378-381.
3. JEFFREY M., PREECE BE., HOLLIMAN A. Dandy-Walker malformation in two calves. **Vet. Rec.**, 1990, 126, 20, 499-501.
4. MAXIE MG., YOUSSEF S. Nervous system. MAXIE MG. (Ed). **Jubb, Kennedy, and Palmer's Pathology of domestic animals**. 5 ed., vol. 1. Saunders Elsevier, Philadelphia 2007: 281-458.
5. NOUREDDINE C., HARDER R., OLBY NJ., SPAULDING K., BROWN T. Ultrasonographic appearance of Dandy Walker-like Syndrome in a Boston Terrier. **Vet. Radiol. Ultrasound.**, 2004, 45, 4, 336-339.
6. PRITCHARD GC., JEFFREY M., WELCHMAN DB., WINDSOR RS., MORGAN G. Multiple cases of Dandy-Walker malformation in three sheep flocks. **Vet. Rec.**, 1994, 135, 7, 163-164.
7. SPENNATO P., MIRONE G., NASTRO A., BUONOCORE MC., RUGGIERO C., TRISCHITTA V., ALIBERTI F., CINALLI G. Hydrocephalus in Dandy–Walker malformation **Childs Nerv. Syst.**, 2011, 27, 10, 1665-1681.
8. WARREN DT., HENDSON G., COCHRANE DD. Bilateral choroid plexus hyperplasia: a case report and management strategies. **Childs Nerv. Syst.**, 2009, 25, 12, 1617-1622.
9. WONG D., WINTER M., HAYNES J., SPONSELLER B., SCHLEINING J. Dandy-Walker–Like Syndrome in a Quarter Horse Colt. **J. Vet. Intern. Med.**, 2007, 21, 5, 1130-1134.

 All rights reserved 2007.