BJVP
Brazilian Journal of Veterinary Pathology
ISSN 1983-0246

Case report

Osteosarcoma in the Skull of a Holstein Heifer

Juan F. Micheloud[1], María G. Guidi[2], Eduardo J. Gimeno[2*]

[1]Grupo de Trabajo de Patología, Epidemiología e Investigación Diagnóstica. Área de Investigación de Sanidad Animal-IIACs Leales/CIAP/INTA-Salta. RN 68, km 72- Salta, Argentina. RN 68, km 72- Salta, Argentina.
[2]Catedra de Patología General, Facultad de Ciencias Veterinarias, Universidad Nacional de La Plata, La Plata, Argentina.
***Corresponding Author:** E.J.Gimeno, Facultad de Ciencias Veterinarias, Universidad Nacional de La Plata**,**
Calles 60 y 118, (1900) La Plata, Argentina**.** E-mail: ejgimeno@fcv.unlp.edu.ar

Submitted August 23rd 2014, Accepted December 22nd 2014

Abstract

A-2-year-old heifer showed a mass on the frontal part of the skull. Cytological analysis displayed pleomorphic, polyedric and fusiform cells with extracellular hyaline material. Histologically, the excised mass showed proliferation of spindle-to-polyhedral cells that exhibited anisocytosis and anisocaryosis. Osteoid substance was demonstrated by Masson´s thricromic stain. Tumoral cells and osteoid expressed osteocalcin. This case report communicates a very rare osteosarcoma in the corneal process of a young heifer. As the heifer was previously dehorned, it is possible that this procedure was a predisposing factor for malignant growth.

Key words: cattle, corneal process, osteosarcoma, immunohistochemistry.

Introduction

Osteosarcomas are bone malignant tumors of osteoblastic origin which always produce bone tissue and osteoid (16, 19). They are frequent in dogs and cats but unusual in other domestic animals (4, 19) and rare in cattle (6, 7, 10, 13). The aim of this study was to describe a singular case of osteosarcoma in a heifer.

Case report

The SDVE-INTA-Salta (Specialized Veterinary Diagnostic Service-National Institute of Agricultural Technology) was called to a dairy farm in San Agustín, Salta in Northwestern Argentina. A 2-years-old Holstein heifer presented a cranial deformation. Fine needle aspiration of the mass was conducted, samples fixed in alcohol and stained with 10% Giemsa. The animal was euthanized and a completed necropsy was performed. Tumor samples were fixed in 10% neutral buffered formalin, embedded in paraffin wax, and sectioned at 3 µm. The sections were stained with Hematoxylin and Eosin, and Masson´s trichrome stain. Immunohistochemistry was performed by a two-step technique based on the dextran polymer system (EnVision®, Dako Cytomation, Carpinteria, CA, USA). The primary specific antibody was the monoclonal against osteocalcin (clone #OC 1, Biodesign International, Kennebunk, ME, USA).

The tumoral mass grew in around 60 to 90 days. It extended in the temporo-frontal area reaching the eye orbit and producing exophthalmos (Fig. 1). The neoplastic tissue showed soft necrotic and hemorrhagic areas. The mass extended until the internal plate of temporal and frontal bones. It invaded the cranial cavity compressing the brain (Fig. 2). Cytology displayed solitary or clamped pleomorphic, polyedric or fusiform cells. Anisokaryosis, hyperchromasia and atypical mitosis were presented. Pinkish-violet material consistent with osteoid matrix was abundant between the cells (Fig. 3). Histologically, this mass showed areas of osteolisis, hemorrhagic and inflammation. The proliferating cells were spindle to-polyhedral cells with the production of neoplastic osteoid and mineralization. Nuclei were spindle-to-plump shaped, and nucleoli were clear.

 All rights reserved 2007.



Figure 1. Osteosarcoma in a heifer. Tumor in the right temporo-frontal region.

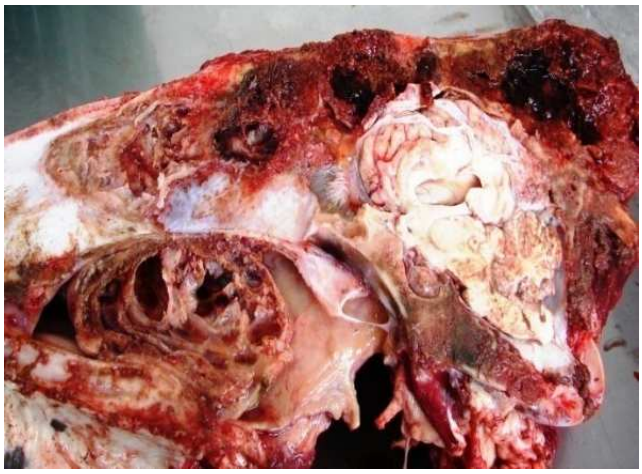

Figure 2. Osteosarcoma in a heifer. Sagittal plane section showing that neoplastic tissue occupied the frontal and nasal sinuses reaching the palatine bone.

Pleomorphism and atypia of cytoplasm and nuclei were prominent. Bizarre mitoses were also observed (Fig. 4). The histological pattern was heterogeneous and osteoid was stained green by the M-T only in restricted areas (Fig. 5). Tumoral cells were strongly immunolabeled for osteocalcin (Fig. 6). The labeling to osteoid was weak. Metastases were not found on the lungs or any other soft tissue.

Discussion

Osteosarcomas are infrequent in cattle. From a total of 372 tumors in cattle from years 1955 to 1968, only one case was observed in a Hereford cow (13). Naghshineh *et al.,* (7) found one osteoma and one osteosarcoma among 1,980 bovine tumors recorded on a 25 year period and Lucena *et al.* (6) found one nasal osteosarcoma among 586 neoplasias.

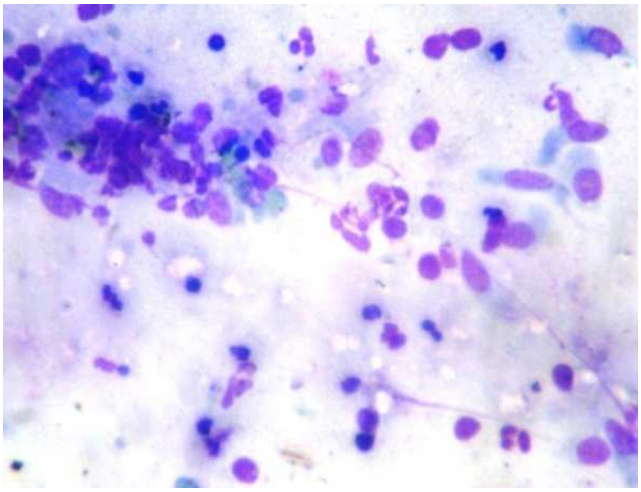

Figure 3. Osteosarcoma in a heifer. Pleomorphic cells with intercellular material consistent with osteoid matrix. Cytology. Giemsa stain.

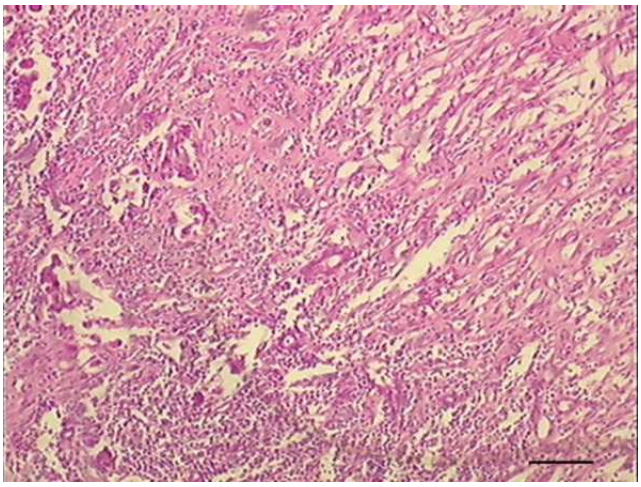

Figure 4. Osteosarcoma in a heifer. Proliferation of spindle-to-polyhedral cells is seen with random foci of osteroid in a haphazard arrangement. HE. Bar = 20 µm.

The histological composition is highly variable but the production of osteoid is a constant feature. Even in the so called non-productive osteosarcomas a scarce amount of osteoid is always present (19). The here reported case was classified as a productive osteoblastic osteosarcoma (16). Osteoid substance was observed at cytological examination, HE-stained sections and stand out by Masson´s trichrome stain (18). Because neoplastic cells and osteoid were immunostained for osteocalcin, we considered that these cells were derived from osteoblasts (18).

Osteosarcoma is a common tumor in the appendicular skeleton of dogs and cats, mainly in the metaphysis of long bones (19); this is also the case in other animal species (4). They are extremely rare in the limbs` bones of cattle (12, 14). An extraskeletal osteosarcoma have been reported in a cow (1).

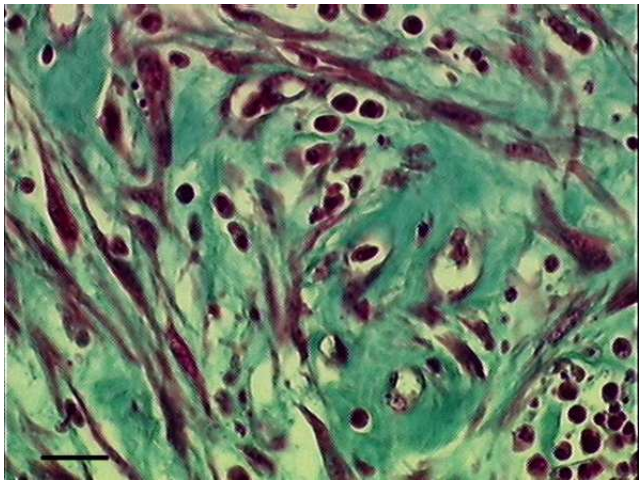

Figure 5. Osteosarcoma in a heifer. Proliferation of spindle-to-polyhedral cells, abundant osteoid is stained green. Masson´s trichrome stain. Bar = 20 µm.

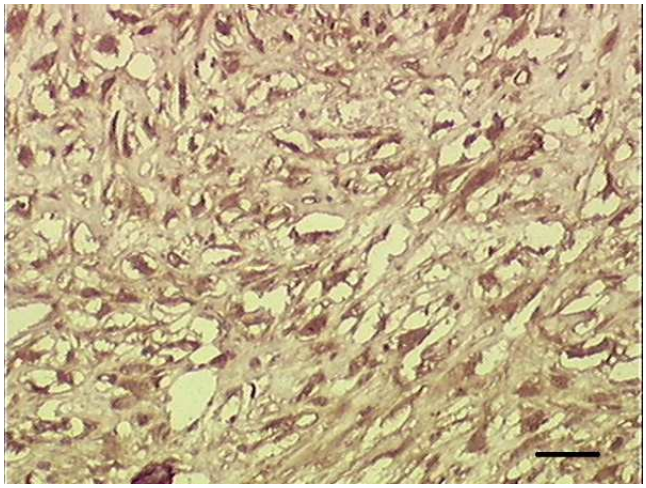

Figure 6. Osteosarcoma in a heifer. Neoplastic cells are positive to anti-osteocalcin antibody. IHC, Bar = 50 µm.

In production animals, the heath is the most frequent location (19). Usually maxillary bones and jaws are the affected organs (2, 8, 9, 10, 17). Endemic ethmoidal tumors have been characterized as epithelial or mesenchymal blastomas, including osteosarcomas (11). Another neoplasia that should be considered in the differential diagnosis is the horn cancer which is frequent in Zebu cattle in India, Sumatra and other Asian countries but they are squamous cell carcinomas (5, 20).

The present case probably aroused from the corneal process. The heifer was dehorned which can be a predisposing factor for malignant growth. Trauma and chronic inflammation have been considered as possible predisposing factors for development of this neoplasia (15). As far as we know, this is the second report of an osteosarcoma from that origin (3).

Acknowledgements

This work was supported by a grant from INTA number PN 1115054 and PRET 1232102. EJG is a Research Career Member of the National Scientific Research Council (CONICET) of Argentina.

References

1. BRAUN U., SYDLER T., IRMER M., GAUTSCHI A., KAMBER R., GERSPACH C., POUGER M. Ultraschall befunde bei einer Kuh mit extraskelettalem chondroblastischem Osteosarkom am Hals. **Schweiz. Arch. Tierheilkd.**, 2010, 152, 379-383.
2. BUSH JM., FREDRICKSON RL., EHRHART EJ. Equine osteosarcoma: a series of 8 cases. **Vet. Pathol.**, 2007, 44, 247-249.
3. GRÜNDER HD. Osteosarkom des Hornzapfens. DIRKSEN G, GRÜNDER HD, STÖBER M Eds. **Innere Medizin und Chirugie des Rindes**. 5. Aufl., Verlag Paul Parey: Berlín., 2006, pp 122.
4. KONDO H, SHIKAWA I, MAEDA H, ONUMA M, MASUDA M, SHIBUYA H, KOIE H, SATO T. Spontaneous osteosarcoma in a rabbit (*Oryctolagus cuniculus*). **Vet. Pathol.**, 2007, 44, 691-694.
5. KORINGA PG., JAKHESARA SJ., BHATT VD., MESHRAM CP., PATEL AK., FEFAR DT., JOSHI CG. Comprehensive transcriptome profiling of squamous cell carcinoma of horn in *Bos indicus*. **Vet. Comp. Oncol.**, 2013. Dec 6. doi: 10.1111/vco.12079. [Epubahead of print]
6. LUCENA RB., RISSI DR., KOMMERS GD., PIEREZAN F., OLIVEIRA-FILHO JC., MACÊDO JTSA., FLORES MM., BARROS CSL. A retrospective study of 586 tumours in Brazilian cattle. **J. Comp. Pathol.**, 2011, 145, 20-24.
7. NAGHSHINEH R., HAGDOOST IS., MOKHBER-DEZFULI MR. A retrospective study of the incidence of bovine neoplasms in Iran**. J. Comp. Pathol.**, 1991, 105, 235-239.
8. PIRIE RS., DIXON PM. Mandibular tumours in the horse: a review of the literature and 7 case reports. **Equine Vet. Educ.**, 1993, 5, 287-294.
9. PLUMLEE KH., HAYNES JS., THOMPSON JR. Osteosarcoma in a cow. **J. Am. Vet. Med. Assoc.**, 1993, 202, 95-96.
10. PRINS DGJ., WITTEK T., BARRETT DC. Maxillary osteosarcoma in a beef suckler cow. **Ir. Vet. J.**, 2012, 65, 15.
11. POSPISCHIL A., WEILAND F., VON SANDERSLEBEN J., HÄNICHEN T., SCHÄFFLER H. Endemic ethmoidal tumours in cattle: sarcomas and carcinosarcomas. A light and electron microscopic study. **Zentralbl Veterinarmed A.**, 1982, 29, 628-636.
12. ROSENBERGER G. Osteosarkom zwischen Brustwand und Oberarm einer Kuh. **Deut. Tierärztl. Woch.**, 1975, 82, 244-244.
13. SHORTRIDGE EH., CORDES DO. Neoplasms in cattle: a survey of 372 neoplasms examined at the Ruakura veterinary diagnostic station. **N. Z. Vet. J.**, 1971, 19, 5-11.
14. SALI G. Osteosarcoma osteogenetico falangeo in una bovina. **Clin. Vet.**, 1969, 92, 159-165.
15. SARTIN EA., HUDSON JA., HERRERA GA., DICKSON AM., WOLFE DF. Invasive malignant fibrous histiocytoma in a cow. **J. Am. Vet. Med. Assoc.**, 1996, 208, 1709-1710.

 All rights reserved 2007.

16. SLAYTER MV., BOOSINGER TR., POOL RR., DÄMMRICH K., MISDORP W., LARSEN S. Malignant tumors. In: **Histological Classification of Bone and Joint Tumors of Domestic Animals**. 2nd Series, vol. 1. Armed Forces Institute of Pathology Ed, Washington, DC., 1994, 7-13
17. STEINBERG H., GEORGE C. Fracture-associated osteogenic sarcoma and a mandibular osteoma in two goats. **J. Comp. Pathol.**, 1989, 100, 453-457.
18. TAMAIZUMI H., KONDO H., SHIBUYA H., ONUMA M., SATO T.Tail root osteosarcoma in a chipmunk (*Tamias sibiricus*). **Vet. Pathol.**, 2007, 44, 392-394.
19. THOMPSON K. Osteosarcoma. In: Jubb, Kennedy, and Palmer's. **Pathology of Domestic Animals**, 5 ed., vol. 1, MG MAXIE, Ed., Elsevier Saunders, Philadelphia, 2007, 112-118.
20. ZUBAIDY SJ. Horn cancer in cattle in Iraq. **Vet. Pathol.**, 1976, 13, 453-454.

 All rights reserved 2007.