



Case Report

Infiltrative Lipomatosis in the Neck and Colon of a Spanish Pure Breed Horse

A. Morales Briceño*, A. Méndez Sanchez, J. Perez Arevalo

Department of Anatomy and Comparative Anatomic Pathology, College of Veterinary Medicine. University of Cordoba, Spain.

*Corresponding author: Abelardo Morales Briceño, Edifício de Sanidad Animal, Campus de Rabanales Ctra. de Madrid km 396, 14071, Córdoba, Spain.
Tel.: +0034619307223. Email: aamorales13@gmail.com

Submitted December 08th 2014, Accepted January 29th 2015

Abstract

The aim of this study was to report a case of infiltrative lipomatosis in the neck and colon in a horse. A 12-year-old male Spanish Pure Breed Horse with deformation of dorsal neck, weighing 650 kg, with a history of acute colic for approximately 24 hours. Euthanasia was undertaken. A necropsy revealed general excessive lipid accumulation in subcutaneous tissue in the dorsal neck. The pelvic flexure of the large colon was found to be displaced into the right cranial abdomen. A large multinodular and multifocal infiltrative fatty mass coalescing was present in a 1.5 m segment of colon with severed lipomatosis; the small intestine proximal to this lesion was moderately distended with fluid. Lipomatosis in the dorsal neck was observed, characterized by diffuse thickening of the subcutis by mature adipose tissue. In conclusion we report a case of severed infiltrative lipomatosis intestinal in large colon and neck.

Key words: horses, neck, lipomatosis, pathology.

Introduction

Excessive fat deposits adversely affect horses in a variety of ways (10). While some body fat is essential as an energy source during prolonged exercise, excess reduces the horse stamina (10). Obesity in horses is associated with abnormal glucose regulation (10). Obesity is well recognized as having a significant effect on human morbidity and mortality and there is increasing awareness of the potential pathological effects of adipose tissue in horses, including horses affected by colic (9). Similarly, regional adiposity in horses and ponies, especially adipose tissue deposited more heavily along the crest of the neck ('cresty neck'), has been suggested to be associated with altered metabolic states, including insulin resistance, and an increased risk for laminitis (2). Deformation dorsal neck is reported in Spain purebred horses and has a great impact (clinical and economic) on production (12) and has been reported in donkeys (8). Lipomatosis refers to the multicentric proliferation of architecturally normal adipose tissue. Lipomatosis has been reported in various

anatomical locations in numerous species, including subcutaneous/musculoskeletal tissues (1, 3), the epidural space (4), salivary glands, liver, mesentery/gastrointestinal tract (6, 11, 7) and the myocardium/mediastinum (3). The pathogenesis of this unencapsulated, infiltrative lesion is unknown. It has been hypothesized to perhaps result from congenital abnormalities in younger animals, while in older animals it may represent a post differentiation genetic aberration of the normal adipocyte karyotype (3). Lipomatosis is rare in horses has been described in a mare 25 years with persistent signs of colic and as lipomatosis necropsy finding in mesojejunum (5). Another case has been described in a Quarter Horse mare with persistent history of acute colic 18 hours. The necropsy result was an atypical infiltrative lipomatosis (7). Benign lipomas are a common incidental finding in the horse, and will sometimes cause strangulation of intestinal structures if they are pedunculated and may undergo torsion involving an intestinal segment (5). Infiltrative lipomas are uncommon neoplasms which have been reported to occur in the subcutaneous and muscular tissues of dogs and other

species (5). They are considered to be benign histologically, but they often cause massive tissue invasion as they grow by infiltration and expansion, and generally carry a poor prognosis (5). The aim of this study was to report a case of infiltrative lipomatosis in neck and colon in a Spanish Purebred horse.

Case report

A 12-year-old male Spanish Pure Breed Horse (Extremadura, Badajoz, Spain), with deformation of dorsal neck (Score 3, Protocol describe by Carter, et al., 2009) (Fig. 1), weighing 650 kg, presented with a history of acute colic for approximately 24 hours. Over the previous month, the male had experienced several episodes of mild recurrent colic. The episode of colic persisted for 24 hours and the pain became unresponsive to analgesic therapy. Euthanasia was undertaken.



Figure 1. Spanish Pure Breed Horse with deformation of dorsal neck (Cresty neck Score 3).

A necropsy was performed immediately after euthanasia. The necropsy revealed a general mucosa pale, excessive lipid accumulation in subcutaneous tissue and lipomatosis in the cresty neck (Fig. 2). The pelvic flexure of the large colon was found to be displaced into the right cranial abdomen. A large multinodular and multifocal infiltrative fatty mass coalescing was present in a 1m segment of large colon with severed lipomatosis (Fig. 3, 4); the small intestine proximal to this lesion was moderately distended with fluid. Tissue samples were fixed in 10% neutral buffered formalin embedded in paraffin wax and sectioned (4 µm).

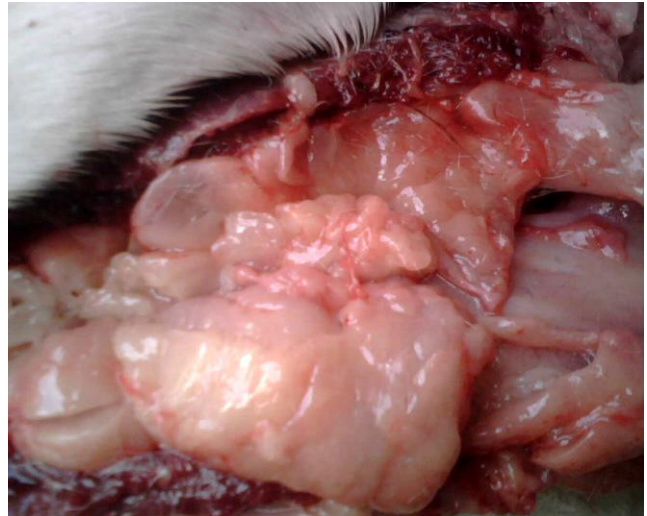

Figure 2. Lipomatosis lobular infiltrative in dorsal neck (cresty neck) in subcutaneous tissue and muscles dorsal.

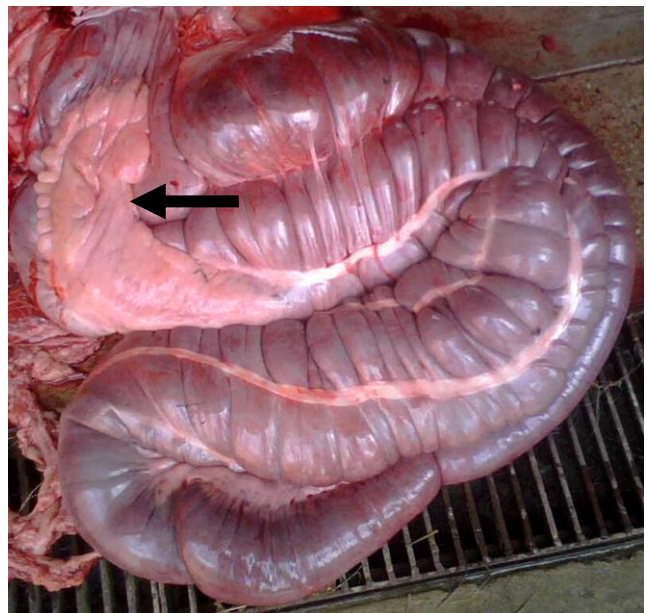


Figure 3. Lipomatosis lobular and infiltrative in the large colon (arrow).

For histopathological examination, sections were stained with haematoxylin and eosin (HE). In the sections of large colon there was mild infiltration of the lamina propria by lymphocytes and plasma cells and multinodular proliferations of well-differentiated adipocytes associated with connective tissue stalks had invaded and effaced the longitudinal layer of tunica muscularis of the large colon. The adipocytes intersected muscle layers and formed cellular aggregates that expanded against, and compressed, the myofibers of the longitudinal layer of the tunica muscularis. The serosa was slightly edematous. The associated adipose tissue of the mesentery was composed predominantly of adipocytes of normal appearance; however, areas of necrosis, hemorrhage, fibrin, and neutrophil infiltration were present throughout the adipose

nodules. Lipomatosis in the cresty neck was observed, characterized by diffuse thickening of the subcutis by mature adipose tissue. The overlying epidermis and dermis were mildly atrophic. The subcutaneous fat showed a normal complement of fibrous septa, blood vessel and nerves. The interlobular septa showed mild mucin deposition. The lipocytes were normal and a small number of primitive mesenchymal cells and lipoblasts were present around blood vessel (Fig. 5).

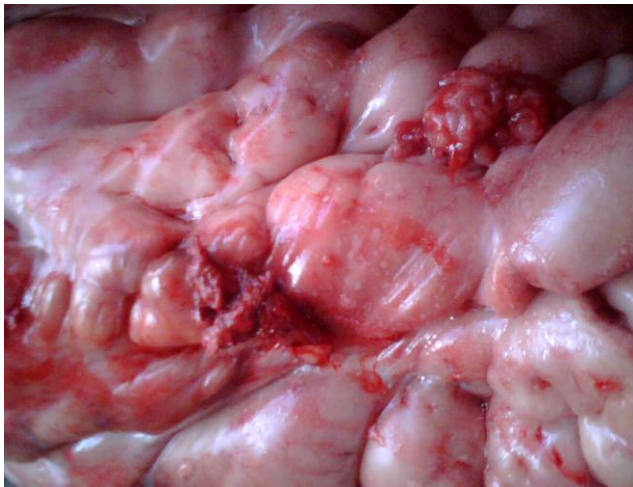


Figure 4. Lipomatosis lobular infiltrative in large colon with aspect lobular and multinodular and necrosis areas.

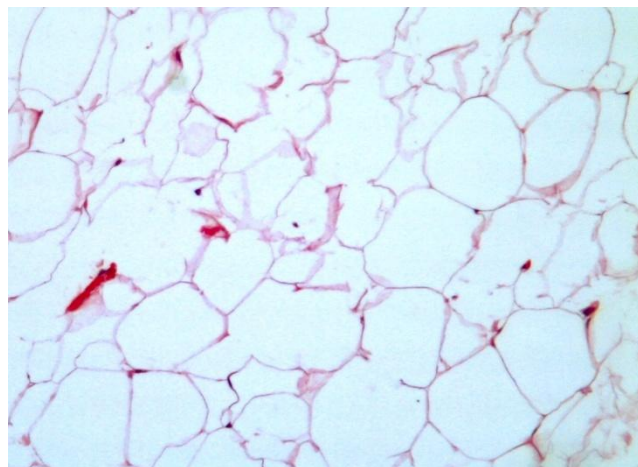


Figure 5. Intestinal lipomatosis; normal lipocytes and a small number of primitive mesenchymal cells and lipoblasts around blood vessel (HE, 20x).

Discussion

Lipomatosis is defined as excessive accumulation of fat in the body or organ that is not encapsulated or limited by tissue planes and pathologically differs from the behavior of benign lipomas. We describe lipomatosis in the dorsal cresty neck and lipomatosis intestinal of large colon in Spanish Purebred horses with colic. The integrity of tunica muscularis of the small and transverse colon was

partially destroyed by the invasive adipocytes. The lesions in this case were most consistent with those of an infiltrative intestinal lipomatosis. There are currently four case reports of lipomatosis of the equine gastrointestinal tract, both of which were associated with the ascending or descending colon (6, 11, 7). Not described simultaneously in previous reports were infiltrative lipomatosis in the dorsal neck muscles and intestinal infiltrative lipomatosis in horses. This case can be considered as similar to the human disease described in multicentric lipomatosis. Possibly this condition is associated with obesity and diet quality subsequently complicated with equine metabolic syndrome and results in recurrent colic that are complicated and result in animal euthanasia or death. Benign lipomas, which originate from mesenteric fat, are well known to occur in horses (5). In conclusion we report a case of severe infiltrative lipomatosis intestinal in large colon and in dorsal neck muscle with deformation of dorsal neck and colic in a Spanish Pure Breed Horse. Future studies are needed to elucidate the pathogenesis of lipomatosis in equine as well as its etiology considering the similarity between the observed clinical signs in humans.

References

1. BRISTOL D., FUBINI S. External lipomas in three horses. *J. Am. Vet. Med. Assoc.*, 1984, 185, 791-792.
2. CARTER RA., GEOR RJ., STANIAR WB., CUBITT TA., HARRIS PA. Apparent adiposity assessed by Standardised scoring systems and morphometric measurements in horses and ponies. *Vet. J.*, 2009, 179, 2, 204-210.
3. ERKERT R., MOLL H., MACALLISTER C., CONFER A., RITCHEY J. Infiltrative lipoma in an American Quarter Horse. *Eq. Vet. Educ.*, 2007, 19, 380-383.
4. FLISBERG P., THOMAS O., GEIJER B. SCHOTT U. Epidural lipomatosis and congenital small spinal canal in spinal anesthesia: a case report and review of the literature. *J. Med. Case Rep.*, 2009, 3, 128.
5. GERELYN AH., BEHZAD Y. Equine colonic lipomatosis. *J. Vet. Diagn. Invest.*, 1995, 7, 578-580.
6. HENRY GA., YAMINI B. Equine colonic lipomatosis. *J. Vet. Diagn. Invest.*, 1995, 7, 4, 578-580.
7. LINNENKOHL W., MAIR T., FEWS D. Case report of atypical infiltrative lipomatosis of the equine mesojejunum. *Eq. Vet. Educ.*, 2013, 25, 5, 237-240.
8. MORALES A., MÉNDEZA., PÉREZ J., LAMPREA A., GARCÍA A., DÍAZ M. Estudio clínico patológico de la deformación del borde dorsal del cuello en burros (*Equus asinus*) de raza Andaluza. *Revista Complutense de Ciencias Veterinarias*, 2014, 8, 1, 1-9.
9. PACKER M., GERMAN A., HUNTER L., TRAYHURN P., PROUDMAN C. Adipose tissue-derived adiponectin expression is significantly

associated with increased post operative mortality in horses undergoing emergency abdominal surgery. **Eq. Vet. J.**, Suppl., 2011, 39, 26-33.

10. RALSTON S. **Maintenance of the “Easy Keeper” Horse.** Rutgers Cooperative Extension, New Jersey Agricultural Experiment Station, Rutgers, The State University of New Jersey, 2001.
11. RILEY E., MARTINDALE A., MARAN B., MOCHAL C., COOLEY J., LINFORD R., READ R., RASHMIR-RAVEN A. Small colon lipomatosis resulting in refractory small colon impaction in a Tennessee Walking Horse. **Eq. Vet. Educ.**, 2007, 19, 484-487.
12. RUIZ LÓPEZ I., ARMENGOU L., CHAMIZO V., VALDÉS M., LÓPEZ RIVERO J. Deformación del borde dorsal del cuello en caballos de pura raza española: incidencia y aspectos clínicos. **Equinus**, **X**, 2010, 26, 24-34.