BJVP
Brazilian Journal of Veterinary Pathology
ISSN 1983-0246

Case report

Papillary Urothelial Neoplasm of Low Malignant Potential (PUNLMP) in a Dog Based on the WHO/ISUP Consensus Classification with Urine Cytology Discrepancy

Zahra Nikousefat[1], Mohammad Hashemnia[2]*, Moosa Javdani[3]

[1]Department of Clinical Science[1] and Pathobiology[2], Veterinary Faculty of Razi University, Kermanshah, Iran.
[3]Department of Veterinary Surgery and Radiology, School of Veterinary Medicine, Shahrekord University, Shahrekord, Iran.
***Corresponding author:** Mohammad Hashemnia, Department of Pathology, School of Veterinary Medicine, Razi University, P.O. Box: 67156-85414, Kermanshah, Iran. Tel.: +98-831-8322599-8329540. Email: m.hashemnia@razi.ac.ir

Submitted January 2nd 2015, Accepted January 26th 2015

Abstract

In the present study, a case of papillary urothelial neoplasm of low malignant potential (PUNLMP) is described in a 7-year-old male terrier dog based on the WHO/ISUP consensus classification with cytologic description in urine sample. Cytological findings including the presence of cell clusters and multi nucleated umbrella cells, increased nucleus/cytoplasm (N/C) ratio, cytoplasmic homogeneity, nuclear eccentricity, nuclear molding, anisokaryosis, and anisonucleosis were compatible with low grade papillary urothelial carcinoma. Histopathologically, cells within papillae were well arranged, and minimal nuclear atypical was observed. Significant mitotic activity and pleomorphism were not found. The thickness of the epithelium varied from normal to much thicker and umbrella cells were prominent. Based on these criteria, the final diagnosis was papillary urothelial neoplasm of low malignant potential (PUNLMP). These findings are important for following research on the treatment of canine urothelial tumors and will encourage the use of such tumors as a model for human disease.

Key words: dog, papillary urothelial neoplasm, cytology, histopathology.

Introduction

Transitional Cell Carcinoma (TCC) is the epithelial type of urothelial proliferation lesion in dogs that accounts for approximately 50-75% incidence of bladder tumors (7, 18).

The similarity of TCC in clinical signs with benign lesions and nonproliferative process such as urolithiasis, often preclude the definitive diagnosis. Furthermore, the recurrent and invasive nature of the disease deteriorates the situation until the time of diagnosis (14).

However, accurate classification of urothelial proliferation lesions and histological grades of urothelial carcinoma is central to earlier detection of the disease and may enhance the treatment outcome for dogs affected with TCC (20).

For human patients, the World Health Organization/International Society of Urologic Pathology (WHO/ISUP) consensus classification of urothelial neoplasms was published in 1998 and updated in 2004. In multiple studies, the WHO/ISUP consensus classification system has been demonstrated to be significantly associated with clinical outcome.

The potential use of the WHO/ISUP consensus classification system in classifying canine bladder tumors was examined previously and it seems that this system is appropriate for the classification of canine bladder tumors (14). Also, recent studies on human invasive urinary bladder cancer have been based on canine urothelial

 All rights reserved 2007.

neoplasm as an effective model, especially in relation to chemotherapy (14).

Urine cytology is an established method for bladder cancer screening that detects exfoliated malignant cells microscopically in urine sediment up to 30% of cases, with a specificity of >90% for TCC. Nevertheless, urine cytology produces false positive results in 1-12% of cases, and distinction between neoplastic and reactive cells may be difficult. Additionally, subjective variation among pathologists results in considerable inter-observer variation in interpretation, particularly with low-grade lesions (15).

The aim of this study is to report a case of papillary urothelial neoplasm of low malignant potential (PUNLMP) in a dog based on the WHO/ISUP consensus classification with cytologic description in urine sample.

Case presentation

A 7-year-old castrated male terrier dog was presented to the Veterinary Teaching Hospital, Razi University, with a history of primary complaint of difficult urination, lethargy, and loss of appetite for approximately one week. The initial physical exam revealed that the animal was mildly dehydrated and had a large, painful bladder. No significant abnormalities were found in prostate upon rectal examination. A urinary catheter was placed and the urine collected for cytological evaluation. Smears of the sediment were stained with MGG (May Grunwald Giemsa) for routine examination.

A blood sample was obtained from the jugular vein for hematologic assessment by using the Sysmex KX21N.

There was no evidence of metastasis to the chest wall or bones in the chest and abdominal radiographs. A Tru-Cut biopsy was performed upon open surgery from a papillary lesion measuring 1×0.5×0.5 cm in the bladder neck and H&E stained tissue sections were prepared.

This study was performed under the approval of the state committee on animal ethics, Razi University, Kermanshah, Iran. In addition, recommendations of European Council Directive (86/609/EC) of November 24, 1986, regarding the protection of animals used for experimental purposes were considered.

Hematological and biochemical findings

Laboratory Findings-Screening blood work revealed mild dehydration (Table 1 and 2). Urine analysis showed evidence of hematuria, proteinuria, and inflammation, but no overt infection; a urine culture revealed no bacterial growth in the urine (Table 3).

Cytological findings

Mild cellularity was observed in a few smears made from catheterized urine sediment. Epithelial cells were present in small aggregates and also individually (Fig. 1a and 1b). Cells were round to polygonal with a round to slightly oval often eccentrically located nucleus, mild clumped to lacy chromatin and abundant amount of amphophilic cytoplasm (Fig. 1b).

Table 1. Hematological findings in a terrier dog with papillary urothelial neoplasm of low malignant potential (PUNLMP).

Test	Result	Reference Range	Units
Red Blood Cells	9.13	(5.83-8.87)	x 10^6 /ul
Hemoglobin	19.9	(13.3-20.5)	g/dl
Hematocrit	57.0	(40.3-60.3)	%
PCV	59		%
MCV	62.4	(62.7-75.5)	fl
MCH	21.8	(22.5-26.9)	pg
MCHC	35.0	(32.2-36.3)	g/dl
RDW	15.3	(13.2-17.4)	%
Platelets	493	(177-398)	x 10^3 /ul
MPV	9.66	(7.37-14.2)	fl
White Blood cells	7.75	(5.3-19.8)	x 10^3 /ul
Seg. neutrophils	6.67	(3.1-14.4)	x 10^3 /ul
Lymphocytes	0.62	(0.9-5.5)	x 10^3 /ul
Monocytes	0.39	(0.1-1.4)	x 10^3 /ul
Eosinophils	0.08	(0.0-1.6)	x 10^3 /ul
Platelet Morphology	Platelet Adequate		
RBC Poikilocytosis	No abnormality noted		
WBC Morphology	No abnormality noted		

SD of hematological and biochemical values

Table 2. Biochemical findings in a terrier dog with papillary urothelial neoplasm of low malignant potential (PUNLMP).

Test	Results	Reference Ranges	Units
Glucose	127	(65-112)	mg/dl
BUN	10	(5-30)	mg/dl
Creatinine	0.7	(0.7-1.8)	mg/dl
BUN/Creatinine Ratio	14.9	(9-33)	
Phosphorus	5.4	(2.8-6.1)	mg/dl
Calcium	10.8	(9.8-11.7)	mg/dl
Sodium	150	(140-150)	Mmol/L
Potassium	4.6	(3.9-4.9)	Mmol/L
Chloride	112	(109-120)	Mmol/L
Carbon Dioxide	29	(17-28)	Mmol/L
Total Protein	7.7	(5.4-7.1)	g/dl
Albumin	3.4	(2.5-3.7)	g/dl
Globulin	4.3	(2.4-4.0)	g/dl
A/G Ratio	0.8	(0.7-1.5)	
ALT	46	(16-91)	U/L
AST	36	(23-65)	U/L
ALP	71	(20-155)	U/L
GGT	6	(7-24)	U/L
Total Bilirubin	0.2	(0.3-0.9)	mg/dl
Cholesterol	180	(128-317)	mg/dl
Anion Gap	9	(8-21)	Mmol/L
Calculated Osmolality	290	(264-292)	mOsm/kg
Magnesium	2.3	(1.6-2.5)	mg/dl

Table 3. Urine analysis of a terrier dog with papillary urothelial neoplasm of low malignant potential (PUNLMP).

Method of collection	Catheterized urine
Urine Color	Yellow
Urine Appearance	Slightly Cloudy
Urine Glucose	Negative
Urine Bilirubin	1+
Urine Ketones	Negative
Urine Specific Gravity	1.019
Urine Blood	3+
Urine pH	7.0
Urine Protein	2+
Urine Albumin test	1+
Urine Urobilinogen	0.2
Urine Nitrite	Negative
RBC/hpf	Too Numerous to Count
WBC/hpf	6-10 per HPF
Urine Sediment cell(s)	Moderate Epithelial Cells
Urine Sediment Crystals	Rare Sodium Urate
Other Sediment Findings	Light Amorphous Material,Scant Fat Droplets

Cells displayed a mild amount of anisokaryosis, anisocytosis (Fig. 1c), occasional binucleation (Fig. 1d) and rare multinucleation (Fig. 1c) and nuclear molding (Fig. 1e). Few neutrophils and erythrocytes were evident in a proteinaceous background. The cytological features were compatible with malignant cells.

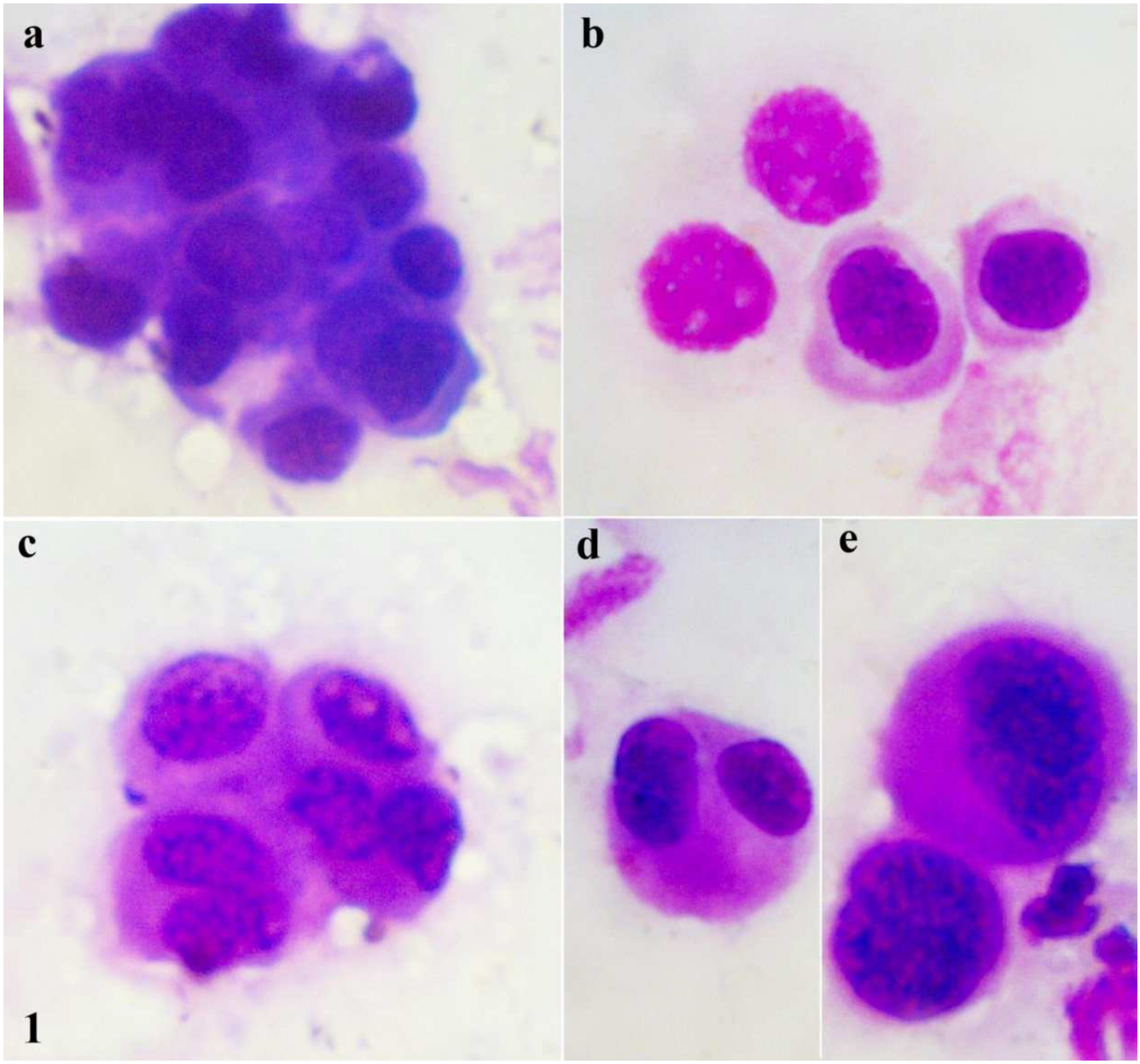

Figure 1. Urine cytology specimen from a case of papillary urothelial neoplasm of low malignant potential (PUNLMP). A: aggregated carcinoma cells; B: round to polygonal cells with a round to slightly oval often eccentrically located nucleus and coarse chromatin; C: mild amount of anisokaryosis, anisocytosis and multinucleation; D: binucleation; E: nuclear molding (MGG staining, 3000x).

Histopathological findings

Histological examination of the sections revealed a papillary neoplasm displaying uniformity with no significant atypia, mitotic activity, and pleomorphism. Cells were organized and with normal polarity (Fig. 2a). Invasion of the lamina propria was not observed. Few fused papillae were evident (Fig. 2b). The thickness of the epithelium varied from normal to much thicker than papillomas (Fig. 2c). The nuclear size was uniformly enlarged with fine chromatin and inconspicuous nucleoli. Umbrella cells were present (Fig. 2d). The diagnosis was PUNLMP.

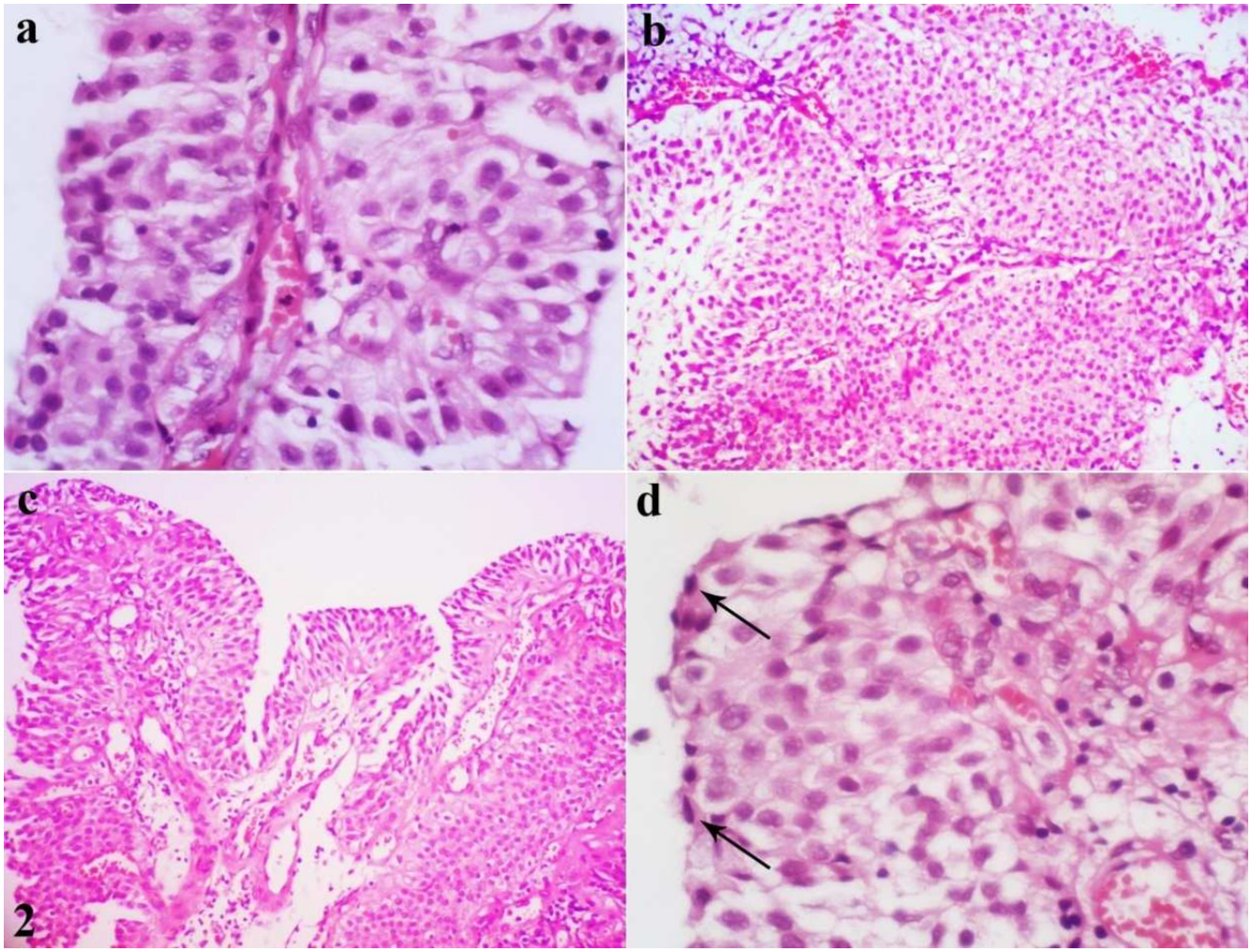

Figure 2. Papillary urothelial neoplasm of low malignant potential (PUNLMP); dog. A: neoplastic cells are well organized within papillae and have a normal Polarity (H&E; 1800x); B: Few fused papillae are observed (H&E; 750x); C: The thickness of the epithelium is varied from normal to much thicker (H&E; 750x); D: umbrella cells (arrows) (H&E; 1800x).

Discussion

Prevalence of bladder cancer in dogs has a tendency to increase in recent years (3). In a retrospective study, Norris et al. (12) found TCC as the most common tumor of epithelial origin among urothelial lesions in dogs (12). However, a low grade form of TCC is rare in dogs and it is not well documented (11). Urine cytology in the context of the 1998 WHO/ISUP classification appears to be useful as a screening tool for early diagnosis of TCC (21). This system claims to provide the most useful tool for predicting survival time, between PUNLMP and high grade papillary urothelial carcinomas (HGUC) (13).

According to previous studies, increased N/C ratio, irregular nuclear borders, cytoplasmic homogeneity, and presence of several cell clusters are the prominent features of the low grade papillary urothelial (LGUC) (22,16). In the lower grade lesion, the first clue is observing nuclear crowing (19).

Certain features like necrosis, apoptosis, nuclear and chromatin changes were more frequent or more severe in high grade lesions (2). Conversely, diffuse cellular atypia and markedly hyperchromatic or India ink nuclei are the most cytological features in HGUC (9).

Upon these criteria, our observation including increased N/C ratio, cytoplasmic homogeneity, irregular nuclear borders, nuclear eccentricity, nuclear molding, anisonucleosis, hyperchromatic nuclear chromatin, absent cytoplasmic collar, granular nuclear chromatin, cell clusters and multi nucleated umbrella cells are compatible with low grade papillary urothelial carcinoma.

Furthermore, the presence of a superficial layer composed of large, multinucleated urothelial cells measuring from 20 to 50 µm in this case was recognized as umbrella cells. According to the literature, the mechanism of nuclear multinucleation is unknown (8).

Histological grading provides powerful prognostic information to predict tumor behavior and selective treatment in canine urinary neoplasms. Significant

correlation was reported between tumor grading and survival time based on Mostofi classification for human urinary bladder tumors (20).

As there is similarity between human and canine TCC, the human classification is appropriate for using in canine tumor classification. However, according to Meuten (10), this classification was modified by considering the size and branching of the lesion as well as cellular atypia (10).

Mutsaers et al. (11) also classified canine TCC based on the system developed by Mostofi and found that papillary infiltrated TCC of intermediate to high grade were predominant in the studied cases (11).

In the recent study, some researchers suggested to use this classification by considering the pattern of growth, nuclear atypia and degree of infiltration into the urinary bladder wall (20).

Our histopathological diagnosis was made according to WHO/ISUP consensus classification (5). As the cells within papillae were well arranged and minimal nuclear atypia were observed, the diagnosis of PUNLMP was made.

To differentiate between papilloma and low grade urothelial neoplasm, we considered the urothelium layer thickness and nuclear shape. This layer was much thicker in PUNLMP compared to papillomas and the nuclei were uniformly enlarged, elongated, hyperchromatic, round-oval in shape, with absent to inconspicuous nucleoli. Mitotic figures were not observed.

Based on our observation, histopathological findings were inconsistent with cytological features in grading. Similarly, other studies also have been reported that there was a controversy between the potential of discrimination in tumor grades in cytology and histopathologic findings. It seems that this system is unsuccessful in distinguishing PUNLMP effectively with low grade papillary urothelial carcinoma (LGUC) (21).

Poor inter and intra-observer agreement in grading urothelial carcinoma on urine samples have been reported previously (17). According to different descriptions mentioned by Rosenthal and Raab (19), to discriminate PUNLMP from LGUC, the presence of elongated nuclear shapes in PUNLMP should be considered, while definite increase N/C ratio and homogenous cytoplasm were not observed in this type of tumor (19).

Since significant percentage of the reclassified low grade lesions have a poor positive cytological correlation, it seemed the sensitivity of urinary cytology for low grade lesions did not improve in this classification (4). Meanwhile, Flezar (6) reported that the sensitivity of urine cytology for the detection of low grade papillary tumors is varied ranging from 0-73% (6).

Many researchers revealed that late stage tumors are more common in canine urinary neoplasm, hence more studies about the correlation between cytology findings and histopathology results in tumor grading are required (14).

In the contrary, discrepancies between cytology reports and histopathological findings is not a false diagnosis, because urine cytology is known to pick up carcinoma *in situ* and the cytology results may not reflect the pathological state of the urothelium at the time of biopsy (1). Also, it has been proved that catheterization would provide higher cellularity and better preservation of specimens compared to voided urine. Moreover, instrumentation artifact and infection in catheterization may change the cells appearance (8). Consequently, in accordance with most authors, the diagnosis of low grade urothelial lesions is difficult, because the spectrum of changes varied from benign urothelium to malignant changes as neoplasia (19). Although the specificity of urine cytology in grading the tumor is low, high sensitivity shows that it is still a valuable tool in the diagnosis of bladder carcinoma (1)

Conclusion

To our knowledge, this report is the second reported case in the dog as a papillary urothelial neoplasm of low malignant potential (PUNLMP) with a cytological characterization. The first one was reported by Patrick et al. in 2006 (14).

In this report, we also tried to demonstrate that adopting the WHO/ISUP human classification system to canine urothelial neoplasm will be valuable to future researches since they have similarity in histopathologic pattern.

In this case, in co-ordinate with other authors, urine cytology appears to be a sensitive tool in detecting abnormal cells in canine urothelial neoplasms but it was not able to differentiate PUNLMP from LGUC. These findings will encourage further ancillary tests on large numbers of canine urothelial tumors.

Acknowledgments

We thank the authorities of Veterinary School, Razi University for their cooperation. This work was supported, in part, by grants from Vice Chancellor for Research at Razi University (Grant No. 56837).

References

1. ABDULLAH LS. The value of urine cytology in the diagnosis of bladder cancer. Cytopathological correlation. **Saudi Med. J.**, 2013, 34, 9, 937-941.
2. BHATIA A., DEY P., KAKKAR N., SRINIVASAN R., NIJHAWAN, R. Malignant atypical cell in urine cytology: a diagnostic dilemma. **CytoJournal**, 2006, 3, 1, 28.

3. CASWELL M. Transitional cell carcinoma of the urinary bladder in a 14-year-old dog. **Can. Vet. J.**, 2011, 52, 6, 673.
4. CURRY JL., WOJCIK, EM. The effects of the current World Health Organization/International Society of Urologic Pathologists bladder neoplasm classification system on urine cytology results. **Cancer**, 2002, 96, 3, 140-145.
5. EPSTEIN JI. Diagnosis and classification of flat, papillary, and invasive urothelial carcinoma: the WHO/ISUP consensus. **Int. J. Surg. Pathol.**, 2010, 18, 3, 106S-111S.
6. FLEZAR M. Urine and bladder washing cytology for detection of urothelial carcinoma: standard test with new possibilities. **Radiol. Oncol.**, 2010, 44, 4, 207-214.
7. HENRY CJ., TYLER JW., MCENTEE MC., STOKOL T., ROGERS KS., CHUN R., STOKES PK. Evaluation of a bladder tumor antigen test as a screening test for transitional cell carcinoma of the lower urinary tract in dogs. **Am. J. Vet. Res.**, 2003, 64, 8, 1017-1020.
8. KOSS LG., HODA RS. **Koss's Cytology of the Urinary Tract with Histopathologic Correlations**. Springer. Chapter 4. p. 21-26, 38, 2012.
9. MORENCY E., ANTIC T. Atypical urine cytology and the Johns Hopkins Hospital template: the University of Chicago experience. **J. Am. Soc. Cytopathol.**, 2014, 3, 6, 295-302.
10. MEUTEN DJ. **Tumours in Domestic Animals**. 4th ed, Iowa State University. Press: A Black Well Publishing Company, 2002.
11. MUTSAERS AJ., WIDMER WR.,KNAPP, DW. Canine transitional cell carcinoma. **J. Vet. Intern. Med.**, 2003, 17, 2, 136-144.
12. NORRIS AM., LAING EJ., VALLI VE., WITHROW SJ., MACYDW., OGILVIE GK., JACOBS RM. Canine bladder and urethral tumors: a retrospective study of 115 cases (1980–1985). **J. Vet. Intern. Med.**, 1992, 6, 3, 145-153.
13. OOSTERHUI, JWA., SCHAPERS RFM., JANSSEN-HEIJNEN MLG., PAUWELS RPE., NEWLING DW., TEN KATE F. Histological grading of papillary urothelial carcinoma of the bladder: prognostic value of the 1998 WHO/ISUP classification system and comparison with conventional grading systems. **J. Clin. Pathol.**, 2002, 55, 12, 900-905.
14. PATRICK DJ., FITZGERALD SD., SESTERHENN IA., DAVIS CJ., KIUPEL M. Classification of canine urinary bladder urothelial tumours based on the World Health Organization/International Society of Urological Pathology consensus classification. **J. Comp. Path.**, 2006, 135, 4, 190-199.
15. PATTARI SK., DEY P. Urine: beyond cytology for detection of malignancy. **Diagn. Cytopathol.**, 2002, 27, 3, 139-142.
16. RAAB SS., LENEL JC., COHEN MB. Low grade transitional cell carcinoma of the bladder. Cytologic diagnosis by key features as identified by logistic regression analysis. **Cancer**, 1994, 74, 5, 1621-1626.
17. REID MD., OSUNKOYA AO., SIDDIQUI MT., LOONEY SW. Accuracy of grading of urothelial carcinoma on urine cytology: an analysis of interobserver and intraobserver agreement. **Int. J. Clin. Exp. Pathol.**, 2012, 5, 9, 882.
18. ROCHA TA., MAULDIN GN., PATNAIK AK., BERGMAN PJ. Prognostic factors in dogs with urinary bladder carcinoma. **J. Vet. Intern. Med.**, 2000, 14, 5, 486-490.
19. ROSENTHAL DL., RAAB SS. **Cytologic detection of urothelial lesions**. Springer New York. pp: 59-62, 2006.
20. SLEDGE DG., PATRICK DJ., FITZGERALD SD., XIE Y., KIUPEL M. Differences in Expression of Uroplakin III, Cytokeratin 7, and Cyclooxygenase-2 in Canine Proliferative Urothelial Lesions of the Urinary Bladder. **Vet. Pathol.**, 2014, DOI: 0300985814522819.
21. WHISNANT RE., BASTACKY SI., OHORI NP. Cytologic diagnosis of low-grade papillary urothelial neoplasms (low malignant potential and low-grade carcinoma) in the context of the 1998 WHO/ISUP classification. **Diagn. Cytopathol.**, 2003, 28, 4, 186-190.
22. XIN W., RAAB, SS., MICHAEL CW. Low-grade urothelial carcinoma: Reappraisal of the cytologic criteria on ThinPrep®. **Diagn. Cytopathol.**, 2003, 29, 3, 125-129.