BJVP
Brazilian Journal of Veterinary Pathology
ISSN 1983-0246

Case report

Medulloblastoma in a Calf: Case Report

Rafael J. Silva[1], José Augusto B. Afonso[1], Carla L. Mendonça[1], Alexandre C. Dantas[2], Janaína A. Guimarães[2], Antônio F. Dantas[3], Marcia B. A. M. Torres[4], Glaucia D. Kommers[5*]

[1]Unidade Acadêmica de Garanhuns/Clínica de Bovinos, Universidade Federal Rural de Pernambuco, Garanhuns-PE, Brazil.
[2]Departamento de Medicina Veterinária, Campus Recife, Universidade Federal Rural de Pernambuco, Recife, Pernambuco, Brazil.
[3]Hospital Veterinário, CSTR, Universidade Federal de Campina Grande, Campus de Patos, Paraíba, Brazil.
[4]Departamento de Medicina Veterinária, Universidade Federal Rural de Pernambuco, Garanhuns-PE, Brazil.
[5]Departamento de Patologia, Universidade Federal de Santa Maria, Santa Maria, Rio Grande do Sul, Brazil.
***Corresponding author:** Rafael José da Silva, Universidade Federal Rural de Pernambuco, Garanhuns-PE, Brazil. E-mail: rafaeljs15@hotmail.com

Submitted June 25th 2014, Accepted December 23rd 2014

Abstract

A two-month-old calf was presented to the Bovine Clinic of the *Universidade Federal Rural de Pernambuco*, Campus Garanhuns (Brazil), with a history of lack of motor coordination in the hind limbs, progressing toward laterally inclined ambulation and imbalance since birth. The recent onset of daily seizures left the calf unable to stand. The animal exhibited pedaling movements and salivation. During the clinical exam, the calf was in lateral recumbency, with hyperextension of the fore and hind limbs, myoclonus, intention tremors (mainly of the head), opisthotonus and nystagmus. The signs were exacerbated upon stimulation. Anus and tail reflexes were diminished. The blood count findings were non-specific. The necropsy revealed a whitish, friable mass with an irregular contour affecting the surface and interior of the cerebellum and brain stem, with the left cerebellar hemisphere more affected. The lateral ventricles (mainly the left ventricle) were dilated and herniation of the cerebellum through the magnum foramen was observed. The diagnosis of medulloblastoma was performed based on the anatomical location and histopathological characteristics of the tumor.

Key words: primary neoplasm, cerebellum, bovine.

Introduction

Primary tumors of the central nervous system are extremely rare in livestock animals (14) and may be the result of multiple environmental factors and/or genetic predisposition (5). Medulloblastoma is a malignant primary neoplasm that occurs in the cerebellum (1, 11, 12, 13, 16), being common in children and can also occur in young animals (17). The cell of origin has not been definitively determined, but it is thought that this neoplasm may develop from primitive cells from the neuroepithelial roof of the fourth ventricle that give rise to the external granular cell layer of the cerebellum (18).

The present paper describes the clinical and anatomopathological findings of a calf with a medulloblastoma.

Case report and discussion

A two-month-old Girolanda male calf was presented to the Bovine Clinic of the *Universidade Federal Rural de Pernambuco*, Campus Garanhuns (Brazil) in April 2011. The calf had a history of dysmetria, characterized by lack of motor coordination in the hind limbs, progressing toward laterally inclined ambulation and imbalance since birth. Fifteen days prior to admission, the onset of daily seizures had left the calf unable to stand. The animal exhibited pedaling movements and salivation, but continued to eat and defecate normally. The calf had been raised under a semi-intensive system and feed on native grass, balanced feed, milk, and mineral mixture.

During the physical exam, the calf was in the lateral recumbency, but was able to achieve sternolateral recumbency when assisted. The animal exhibited

 All rights reserved 2007.

depression, around 10% dehydration, recumbency sores adjacent to bone protuberances, tachycardia, tachypnea, anorexia, bruxism, nystagmus, opisthotonus, hyperextension of the forelimbs and intention tremors, especially of the head. When agitated, the opisthotonus, hyperextension of the forelimbs and nystagmus were exacerbated. Anus and tail reflexes were diminished.

Cases of medulloblastoma occasionally occur in young cattle and dogs and have sporadically been observed in pigs and cats. In calves, signs of cerebellar dysfunction are evident in the first weeks of life (3, 17), as described in calves aged six weeks, two months and four months (6), in two twin four-month-old calves (3), as well as in the case described in the present study. However, there are reports of medulloblastoma in a two-year-old cat (10) and a four-year-old dog (16).

The calf described herein had clinical signs of compression of the brain stem in the cerebello-pontine angle, which corroborates findings described in previous reports (3, 6, 10, 16). In such cases, the neurological structures that often become denervated include nuclei of the 5th, 7th and 8th cranial nerves and the cerebellum (15).

Feces were yellowish, fetid and with soft consistency, with diminished digestibility, the presence of mucus and an *Eimeria* spp. oocyst count of 9,200 was established by parasitologic exam. Other laboratory exams demonstrated neutrophilia and hyperfibrinogenemia were observed, which may be explained by a response to the inflammatory process and mild hypoproteinemia, likely caused by the reduction in food intake and the eimeriosis (4). No abnormalities in the blood count or biochemical profile have been found in a cat with medulloblastoma (7).

Due to the severity of the clinical condition, the calf was submitted to euthanasia. During the necropsy, the most important finding was a whitish, friable mass with an irregular contour affecting the surface and interior of the cerebellum and brainstem, being the left cerebellar hemisphere the most affected (Fig. 1 and 2). The lateral ventricles (mainly the left ventricle) were dilated (Fig. 2) and herniation of the cerebellum through the magnum foramen was observed. These findings are compatible with other cases of medulloblastoma described in cattle, dogs and cats (6, 10, 16, 18). Moreover, the tumor can compress the fourth ventricle and cause obstructive hydrocephalus. It can also infiltrate adjacent structures, including the leptomeninges, and in some cases give rise to metastases through the cerebrospinal fluid in the ventricles or subarachnoid space (18).

Tissue samples were collected, fixed in 10% buffered formalin, embedded in paraffin, cut in 5 µm sections and stained with hematoxylin-eosin (HE) for histopathologic analysis. Tissue sections were processed for immunohistochemical analysis utilizing an anti-glial fibrillary acidic protein (GFAP) primary antibody.

The mass was densely cellular, with areas of more intense cellular clustering, with cells forming bands or circles (Fig. 3), with scarce cytoplasm. The nuclei were of different sizes and shapes (round, oval or elongated).



Figure 1. Medulloblastoma in a calf. Brain. Whitish tumoral mass in the cerebellum.

Some nuclei were dark and others were light, in which a variable number of nucleoli were visible. A moderate amount of blood vessels was observed as part of the tumor stroma (Fig. 4). Was also identified moderate amount of mitotic figures (Fig. 4). These findings are similar to those reported in the literature (6, 17, 18). Considering the classification of this tumor in humans, according to the modified Chang et al. (2) system, through radiology, this case can be classified as T4 stage (tumor larger than 3 cm, extending through the foramen magnum), and M2 (gross nodular structure with extension to other locations such as the brainstem) (1, 2).

Differential diagnoses includes ependymoma, a tumor that is usually slow growth in young and adults, originating in the wall of the ventricles or spinal cord, and composed of neoplastic ependymal cells; and neuroblastoma, which has microscopic appearance very similar to medulloblastoma (9, 13).

Immunohistochemical analysis of GFAP in this case revealed the presence of scarce astrocytes within the tumor, which is a finding commonly observed in medulloblastomas (8).

 All rights reserved 2007.

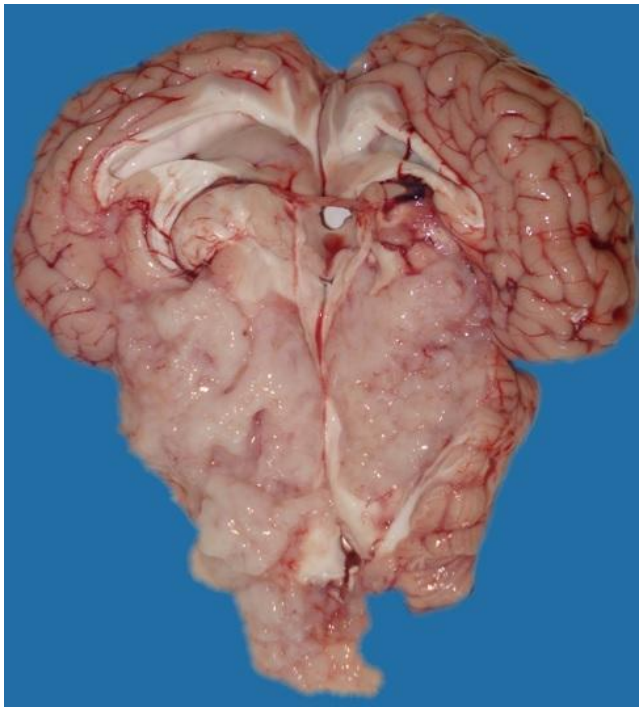

Figure 2. Medulloblastoma in a calf. Sagital section of brain. Most part of cerebellum and mesencephalon are replaced by neoplasic mass of left cerebellar hemisphere and mild dilation of left lateral ventricle.

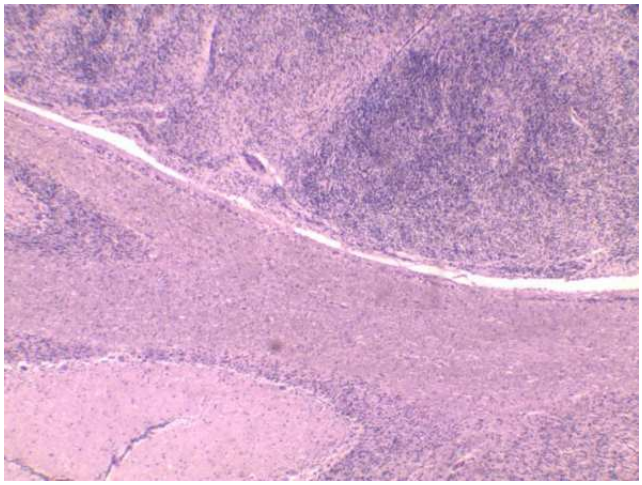

Figure 3. Medulloblastoma in a calf. Lower portion showing normal cerebellar tissue and the upper portion with densely cellular neoplastic tissue, with cells forming bands or circles. HE. (10x).

Primary tumors of the central nervous system are rare in ruminants, although it is not clear whether these tumors are underdiagnosed in ruminants. There is no treatment for this malignant neoplasm in cattle, and the diagnosis is usually defined at necropsy.

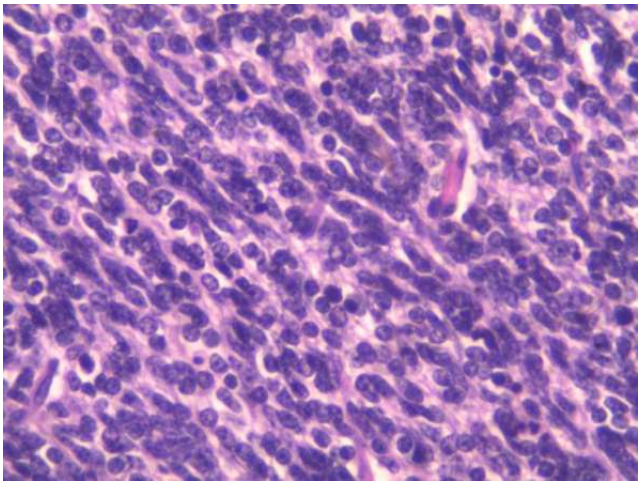

Figure 4. Medulloblastoma in a calf. Higher magnification of neoplasic proliferation. Nuclei with variable size and shape, vascularization, and mitotic figures. HE. (40x).

References

1. BARTLETT F.; KORTMANN R.; SARAN F. Medulloblastoma. **Clin. Oncol.**, 2013, 25, 36-45.
2. CHANG CH.; HOUSEPIAN EM.; HERBERT Jr C. An operative staging system and a megavoltage radiotherapeutic technique for cerebellar medulloblastomas. **Radiology**, 1969, 93, 6, 1351-1359.
3. FANKHAUSER R.; FATZER R.; HERMANN M. Medulloblastome bei verschiedengeschlechtigen Zwillingskälbern. **Schweiz. Arch. Tierheilkd.**, 1982, 124, 363-367.
4. FELDMAN BF., ZINKL JG., JAIN NC. **Schalm's Veterinary Hematology**. Philadelphia, PE: Lippincott Williams & Wilkins, 2000.
5. GRAÇA DL., ALESSI AC., ECCO R., VIOTT AM. Patologia do sistema nervoso. SANTOS RL., ALESSI AC. Eds. **Patologia Veterinária**. 1.ed. São Paulo, SP: Roca, 2011, 525-610.
6. JOLLY RD., ALLEY MR. Medulloblastoma in calves. A report of three cases. **Pathol. Vet.**, 1969, 6, 463-468.
7. KITAGAWA M., KOIE H., KANAYAMA K., SAKAI T. Medulloblastoma in a cat: clinical and MRI findings. **J. Small Anim. Pract.**, 2003, 139-142.
8. KOESTER A. & HIGGINGS RJ. Tumors of the nervous system. MEUTEN DJ. Ed. **Tumors in domestic animals**. 4.ed. Iowa: Iowa State Press. 2002, 697-738.
9. KOESTNER A.; JONES TC. Nervous System. JONES TC.; HUNT RD.; KING NW. Eds. **Veterinary Pathology**. 6.ed. Barueri, SP: Manole, 2000, 1281-1320.
10. KUWABARA M., KITAGAWA TS., OHBA S., TSUBOKAWA T. Early diagnosis of feline medulloblastoma in the vermis. **Vet. Rec.**, 2002, 150, 488-489.

11. LV SQ.; KIM YH.; GIULIO F.; SHALABY T.; NOBUSAWA S.; YANG H.; ZHOU Z.; GROTZER M.; OHGAKI H. Genetic alterations in microRNAs in Medulloblastomas. **Brain Pathol.**, 2012, 22, 230-239.
12. MANDRIOLI L.; BISERNI R.; PANARESE S.; MORINI M.; GANDINI G.; BETTINI G. Immunohistochemical profiling and telomerase activity of a canine medulloblastoma. **Vet. Pathol.**, 2011, 48, 4, 814-816.
13. OHGAKI H.; KIM Y.; STEINBACH J. P. Nervous systems tumors associated with familial tumor syndromes. **Curr. Opin. Neurol.**, 2010, 23, 583-591.
14. RADOSTITS OM., GAY CC., HINCHCLIFF KW., CONSTABLE PD. **Veterinary Medicine**. London, UK: Saunders, 2007.
15. SMITH MO. Nervous System Diseases. SMITH BP. Ed. **Large Animal Internal Medicine**. 3.ed. São Paulo, SP: Manole, 2006, 873-1018.
16. STEINBERG H., GALBREATH EJ. Cerebellar medulloblastoma with multiple differentiation in a dog. **Vet Pathol.**, 1998, 35, 543-546.
17. SUMMERS BA., CUMMINGS JF., LAHUNTA A. **Veterinary Neuropathology**. St. Louis, MI: Mosby, 1995.
18. ZACHARY JF. Nervous System. McGAVIN MD., ZACHARY JF. Eds. **Bases of Veterinary Pathology**. 4.ed. São Paulo, SP: Elsevier, 2009, 833-971.

 All rights reserved 2007.