



## Case Report

# Congenital Torsion of a Herniated Accessory Liver Lobe in a Lamb

Alireza Raayat Jahromi<sup>1</sup>, Younes Kamali<sup>2\*</sup>, Nasrollah Ahmadi<sup>3</sup>, Hesam Savadkoohi<sup>1</sup>

<sup>1</sup>Department of Clinical Sciences, School of Veterinary Medicine, Shiraz University, Shiraz, Iran

<sup>2</sup>Department of Basic Sciences, School of Veterinary Medicine, Shiraz University, Shiraz, Iran

<sup>3</sup>Department of Pathobiology, School of Veterinary Medicine, Shiraz University, Shiraz, Iran

\*Corresponding Author: Younes Kamali. Tel.: +989157878617, E-mail: youn.kamali@gmail.com

Submitted February 11<sup>th</sup> 2015, Accepted March 19<sup>th</sup> 2015

---

## Abstract

Accessory liver lobe (ALL) is an extremely rare anomaly, which can potentially undergo torsion and ischemia. A case with a herniated and twisted ALL originating from the umbilical fissure in conjunction with liver proper and lung abnormalities in a 2-day-old lamb is presented. The primitive presentation of the case was umbilical hernia that underwent herniorrhaphy and expired because of multiple anomalies. ALL seems to be caused by extra-embryonic entrapment of a portion of the liver as a result of high intra-abdominal pressure.

**Key words:** accessory liver lobe, liver lobe torsion, hepatic diseases, sheep diseases.

---

## Introduction

Congenital defects of the liver are uncommon. Among the abnormalities of the liver, accessory liver lobes (ALLs) are extremely rare. The cause of this anomaly is not clear, but omphalocele may play a role in its embryological development (6). Accessory liver lobe may be found in regions other than their normal position, however still in connection with the liver, including hepatic ligament, adrenal glands, gallbladder, umbilicus, pancreas, esophagus, thorax, omphalocele, retroperitoneum and splenic capsule as well as in the lesser and greater omentum and elsewhere on the surface of the peritoneum (10).

This report presents a case of a lamb with twisted ALL that was herniated in umbilical region with concurrent liver proper and lung abnormalities.

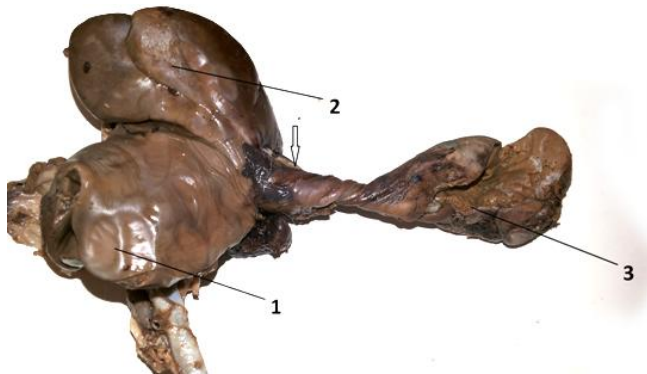
## Case report

A 2-day-old male lamb was referred to the Veterinary Teaching Hospital of the veterinary college of Shiraz University, Iran, with a solid mass in the fetal end of the umbilical cord. The deliverance was spontaneous and

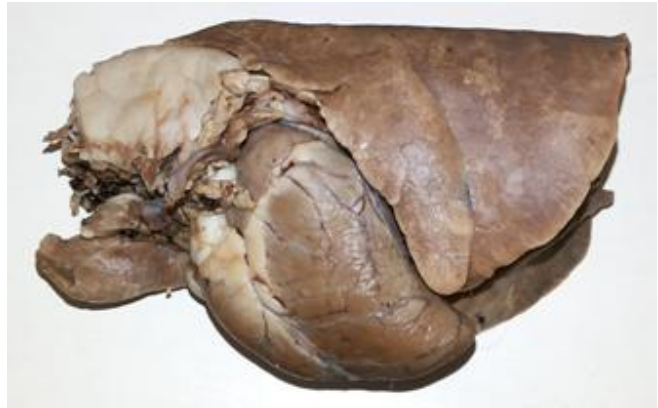natural. At a first glance the umbilical mass of the newborn seemed like an omphalocele and a tentative diagnosis of umbilical hernia was made. Ultrasound revealed an echogenicity consistent with hepatic tissue inside the umbilicus. The lamb underwent a herniorrhaphy under local anesthesia. After excision of the hernial sac, exposure of the mass revealed a large fusiform accessory liver lobe with a 180° clockwise torsion, measuring 6×3×2 cm and connected to the liver proper through a twisted long pedicle (Fig. 1). The twisted pedicle was not plastic and reversible. Hence, the blood supply and drainage of the ALL was impaired, resulting in a dark red consistent liver tissue mass. The lamb died shortly before the onset of tentative lobectomy.

At necropsy, the liver was malformed, so the left lobe was slightly retroflexed toward the diaphragmatic surface. A few impressions on the latter surface of the right lobe were also observed. Similarly, the adipose capsule overlying the right kidney showed the impressions. The visceral surface of the liver was deeply concave (Fig. 2). The pedicle with 4 cm in length and 1 cm in width originated from the umbilical fissure and contained the scarring left umbilical vein, hepatic artery and vein, bile

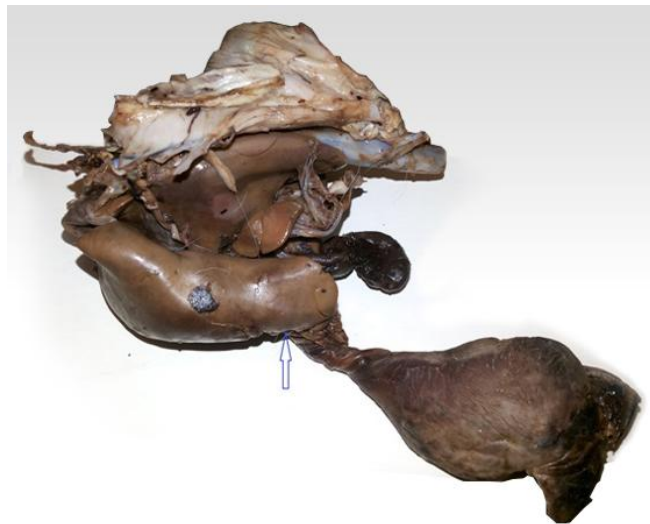duct, portal vein and a narrow strip of hepatic parenchyma (Fig. 1).



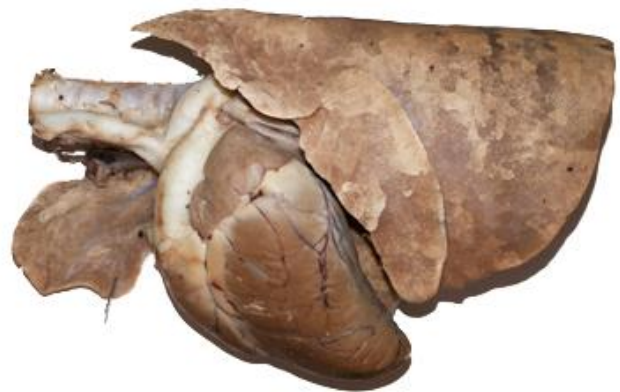**Figure 1.** Diaphragmatic surface of the liver proper. The tip of the arrow indicates the scarring umbilical vein. (1) abnormal impressions on the right lobe; (2) attachment site of the falciform ligament; (3) accessory liver lobe.



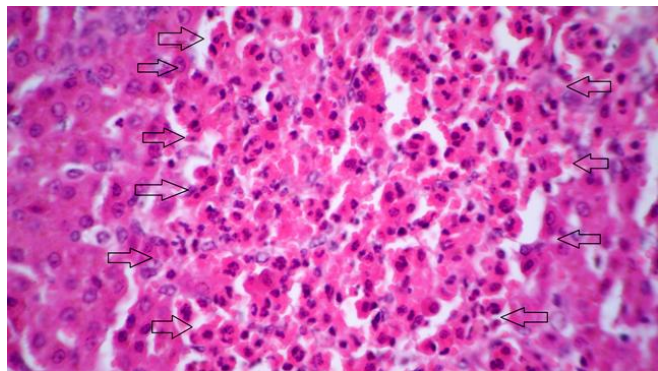
**Figure 3.** Lateral aspect of the left lung showing the replaced adipose tissue instead of the apical lobe.



**Figure 2.** Visceral surface of the liver proper. Note to a severe concavity of this surface. The arrow indicates the umbilical fissure.



**Figure 4.** Left lateral view showing agenesis of the apical lobe after removing the replaced adipose tissue.



**Figure 5.** The arrows show one focus of neutrophil accumulation with necrotic tissue debris in the ALL (HE, Obj. 100x).

Inside the thoracic cavity, the apical lobe of the left lung was not formed and replaced by a mass of well formed adipose tissue (Fig. 3 and 4). Dissection of the organs in thorax and abdomen revealed no other abnormality.

Histopathological examination of the liver showed severe congestion without any infiltration of the inflammatory cells. There was congestion, marked edema and hemorrhages in the submucosal and serosal layers of the gallbladder. Microscopically, the tissue sections of the ALL revealed multiple and randomly distributed foci of neutrophil aggregates (microabscesses) with necrotic tissue debris throughout the liver parenchyma (Fig. 5). Severe hemorrhage and infiltration of neutrophils in the subcapsular region and increased thickening of the connective tissue beneath the hepatic capsule was evident. There were no histopathological changes in the pedicle and lung.

## Discussion

In veterinary medicine, liver lobe torsion has most commonly been described in dogs but, even in this species, it is considered rare. Liver lobe torsions have also been described in laboratory animals (rats, rabbits, and mice), cats, pigs, two horses, and an otter. In all these mentioned

reports, one of the lobes of liver proper itself, but not an accessory liver lobe due to acquired unknown reasons was twisted (2, 4, 6, 9, 12, 13, 14). A handful of reports are available describing liver lobe torsions in humans, most of which involve accessory liver lobes (7). Congenitally, an accessory liver lobe without any torsion has been reported only in a calf (1). A review of the veterinary literature shows that the present report is the first case with an ALL that was twisted prior to birth.

Abnormally positioned liver tissue can be broadly divided into three main types: 1) an accessory liver lobe, attached to the liver via a stalk; 2) a small accessory liver lobe that is attached directly to the liver without a stalk, which is thought to be the most common of the three types; and 3) ectopic liver, which is situated outside the liver with no connection to the liver (3). ALLs have been found to originate from the left, right, caudate lobe or even the gallbladder. As noted above, in our case the origin of the accessory liver lobe was umbilical fissure, between the left lobe and the quadrate lobe. ALLs may be a possible cause of the small omphalocele, in addition to loops of intestine. There is no apparent reason why the ALLs or ectopic liver occur in associated with omphalocele. According to the opinion of some authors, the ALL is caused by extra-embryonic entrapment of a portion of the liver as a result of high intra-abdominal pressure (8, 11). In this situation, subsequent traction by the weight of the liver proper on the part of the liver embedded in the amniotic sac would result in an elongated pedicle (6). At a phase of development, the haematopoietic liver occupies most of the abdominal cavity. Hence, contributes in physiological umbilical herniation. During this process, the growing intestinal loop rotates 180° clockwise around a dorso-ventral axis with the cranial mesenteric artery located in the axis (5). Accordingly, the authors propose that at this stage of development, the twisting of the pedicle around its longitudinal axis is not unexpected.

### Acknowledgement

The authors thank Dr. Mohammad Salehi (an anatomic pathologist, private diagnostic laboratory, Shiraz, Iran) for his helpful discussion.

### References

1. ATASEVER A., BEYAZ L., ARICAN M. Accessory liver lobe anomaly in the abdominal region of a calf. **Rev. Med. Vet.**, 2004, 155, 6, 321-323.
2. BENTZ KJ., BURGESS BA., LOHMANN KL. Hepatic lobe torsion in a horse. **Can. Vet. J.**, 2009, 50, 283-286.
3. CHAMPETIER J., YVER R., LETOUBLON C., VIGNEAU B. A general review of anomalies of hepatic morphology and their clinical implications. **Anat. Clin.**, 1985, 7, 285-99.
4. HAMIR AN. Torsion of the liver in a sow. **Vet. Rec.**, 1980, 106, 362-363.
5. HYTTEL P., SINOWATZ F., VEJLSTED M. Development of the Liver. In: Betteridge K. **Essentials of Domestic Animal Embryology**. Saunders Elsevier, 2010, British, 239-242.
6. ITO F., ANDO H., WATANABE Y., SEO T., MURAHASHI O., HARADA T. An accessory lobe of the liver disturbing closure of the umbilical ring. **Pediatr. Surg. Int.**, 1999, 15, 394-396.
7. KHAN AM., HUNDAL R., MANZOOR K. Accessory liver lobes: a diagnostic and therapeutic challenge of their torsions. **Scand. J. Gastroenterol.**, 2006, 41, 125-130.
8. KLEINHAUS S., KAUFER N., BOLEY SJ. Partial hepatectomy in omphalocele repair. **Surgery**, 1968, 64, 484-486.
9. MORIN M., SAUVAGEAU R., PHANEUF JB. Torsion of abdominal organs in sows: a report of 36 cases. **Can. Vet. J.**, 1984 25, 440-442.
10. PARK WH., CHOI SO., LEE SS., RANDOLPH JG. Ectopic umbilical liver in conjunction with biliary atresia: uncommon association. **J. Pediatr. Surg.**, 1991, 26, 219-222.
11. SHAW A., PIEROG S. Ectopic liver in the umbilicus: an unusual focus of infections in a newborn infant. **Pediatrics**, 1969, 44, 448-450.
12. TURNER TA., BROWN CA., WILSON JH. Hepatic lobe torsion as a cause of colic in a horse. **Can. Vet. Surg.**, 1993, 22, 301-304.
13. WARNS-PETIT ES. Liver lobe torsion in an Oriental small-clawed otter (*Aonyx cinerea*). **Vet. Rec.**, 2001, 148, 212-213.
14. WILSON RB., HOLSCHER MA., SLY DL. Liver lobe torsion in a rabbit. **Lab. Anim. Sci.**, 1987, 37, 506-507.