



Case Report

Co-occurrence of an osteogenesis imperfecta-like phenotype and congenital diaphragmatic hernia in a kitten

Juneo F. Silva, Rubens A. Carneiro, Rogéria Serakides, Ana Patrícia C. Silva,
Guilherme C. Martins, Silvia T. Pereira, Natália M. Ocarino*

Departamento de Clínica e Cirurgia Veterinárias, Escola de Veterinária da Universidade Federal de Minas Gerais (UFMG), Avenida Presidente Antônio Carlos, 6627, CEP: 30.161-970, Belo Horizonte, Minas Gerais, Brazil.

*Corresponding author: Natália M. Ocarino, Setor de Patologia Veterinária do Departamento de Clínica e Cirurgia Veterinárias, Escola de Veterinária da Universidade Federal de Minas Gerais, Avenida Presidente Antônio Carlos, 6627 – CEP: 30.161-970, Belo Horizonte, Minas Gerais (Brazil). Email: nataliaocarino@gmail.com. Phone: 55 31 3409 22 29, Fax: 55 31 3409 22 30.

Submitted April 29th 2015, Accepted June 24th 2015

Abstract

A rare case of the co-occurrence of an osteogenesis imperfecta-like phenotype and congenital diaphragmatic hernia is reported in a male, mixed-breed kitten with a clinical history of dyspnea, dehydration, sternal recumbency and stupor. The animal presented moderate bone deformity of the fore and hind limbs, muscle atrophy, and cervical and thoracic lordosis. The radiological examination and necropsy revealed diffuse and intense radiolucency throughout the skeleton, curved or fractured bones, very thin cortical long bones, an intensely extended medullary canal and left diaphragmatic hernia with an aperture without bleeding or scarring. Microscopically, some long bones and vertebral bodies had less-differentiated cartilaginous epiphysis, predominantly attached to the epiphyseal plate and with absence of secondary ossification centers or incipient formation. The trabeculae were thin, few, surrounded by abundant cartilaginous tissue and coated with a layer of bulky cuboidal osteoblasts. The cortical long bones, vertebrae, skull and ribs were thin and discontinuous. Based on the clinical, radiological, macroscopic and microscopic findings, a diagnosis of osteogenesis imperfecta and congenital diaphragmatic hernia was confirmed. To the best of our knowledge, this report is the first case of OI associated with congenital diaphragmatic hernia in an animal.

Key words: bone disease osteogenesis imperfecta, congenital diaphragmatic hernia, *Felis catus*.

Introduction

Osteogenesis imperfecta (OI) is a genetic bone disease characterized by postnatal bone fragility and intrauterine fractures. In most cases, it is caused by a failure of synthesis and maturation of type 1 collagen (22) due to mutations in the COL1A1 or COL1A2 gene (4-5). Thus, several extra-skeletal manifestations may be associated with OI because type 1 collagen is present in many tissues and organs. These extra-skeletal manifestations occur variably among individuals with OI. These individuals have been diagnosed with dentinogenesis imperfecta, blue sclera, hyperlaxity of the ligaments and skin (22) and less often, umbilical and

inguinal hernias (9, 26). However, few cases of congenital diaphragmatic hernia associated with OI have been described in humans (9, 26), and no cases have been described in animals.

Although OI is rare in animals, it has been diagnosed in cattle (1), sheep (2), dogs (10, 25) and cats (6, 7, 11, 19). However, to our knowledge, this report describes the first case in animals in which OI was associated with congenital diaphragmatic hernia.

This study reports the co-occurrence of an osteogenesis imperfecta-like phenotype and congenital diaphragmatic hernia in a kitten.

Case report

A male, mixed breed cat approximately 60 days old with a body weight of 250 grams was forwarded to the Emergency Unit of the Veterinary Hospital of the Universidade Federal de Minas Gerais (UFMG) with a history of difficulty in mobility and breathing. According to the owner, the animal had been abandoned by his mother and had been fed for the first 30 days of life via bottle with cow's milk and mineral and vitamin supplementation (Cal-D-Mix®, Vetnil, São Paulo, BR) at a dose of 1 mL/Kg/day. After the 30 days, the animal began to receive food substitute milk for cats (Pet Milk®, Vetnil, São Paulo, BR) at 4 g of feed per 100 g of body weight four times/day. According to the owner, at birth, the animal had difficulty breathing, could not maintain station, and crawled to move, supported by the elbows. Prior to the veterinary medical consultation, the animal was unable to move, and breathing worsened. There was no history of trauma, and no drugs were used.

On physical examination, the animal was dyspneic, dehydrated, and in sternal recumbency and stupor. The fore and hind limbs had moderate bone deformity and muscle atrophy. The spine showed lordosis of the cervical and thoracic vertebrae. The animal was submitted to radiological examination of the whole skeleton and thoracic and abdominal cavity but died prior to other complementary tests. The cat was referred for necropsy and histopathology.

Ante- and post-mortem radiological examination was performed on the entire skeleton. The bones of the fore and hind limbs showed diffuse and intense radiolucency and were curved or fractured. The diffuse and intense bone radiolucency was observed in the entire skeleton. The cortical long bones were very thin and sometimes non-existent, and the medullary canal was intensely extended. The first ribs were curved (Fig. 1A and 1B). A diagnosis of left diaphragmatic hernia was indicated at radiological imaging ante-mortem.

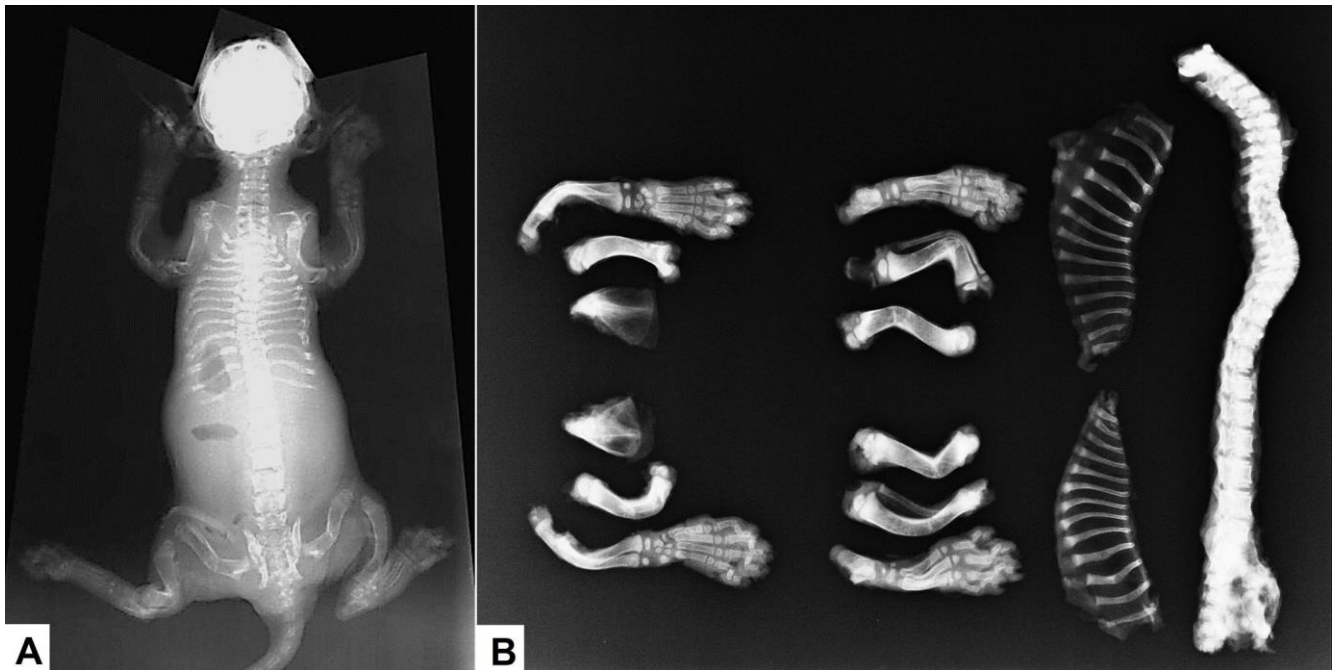


Figure 1. Co-occurrence of osteogenesis imperfecta-like phenotype and congenital diaphragmatic hernia in a kitten. (A and B) Radiograph showing diffuse and intense radiolucency throughout the skeleton, curved or fractured bones, very thin cortical long bones and an intensely extended medullary canal.

At necropsy, the animal had bad nutritional status and moderately pale oral and ocular mucosa. Femurs, tibias (Fig. 2A) and humerus of the right and left sides and the left scapula were curved in the diaphyseal region (Fig. 2B). Discrete bone callus formation was observed in the right and left femur, tibia and humerus. The cervical and thoracic vertebrae were curved dorsal-ventral (Fig. 2C). All bones had decreased resistance, characterized by cutting with a knife. The stomach was insinuated into the thoracic cavity through an aperture in the left dorsolateral

region of the diaphragm (Fig. 2D). The aperture was approximately 7 cm in diameter with smooth edges and no bleeding or scarring. The left lung had moderate atelectasis, characterized by moderate reduction of volume, an intense red color and rubberized consistency. The other organs and tissues, including the skin, eyes, teeth, thyroid and parathyroid, had no significant gross lesions. Trauma lesions were not observed.

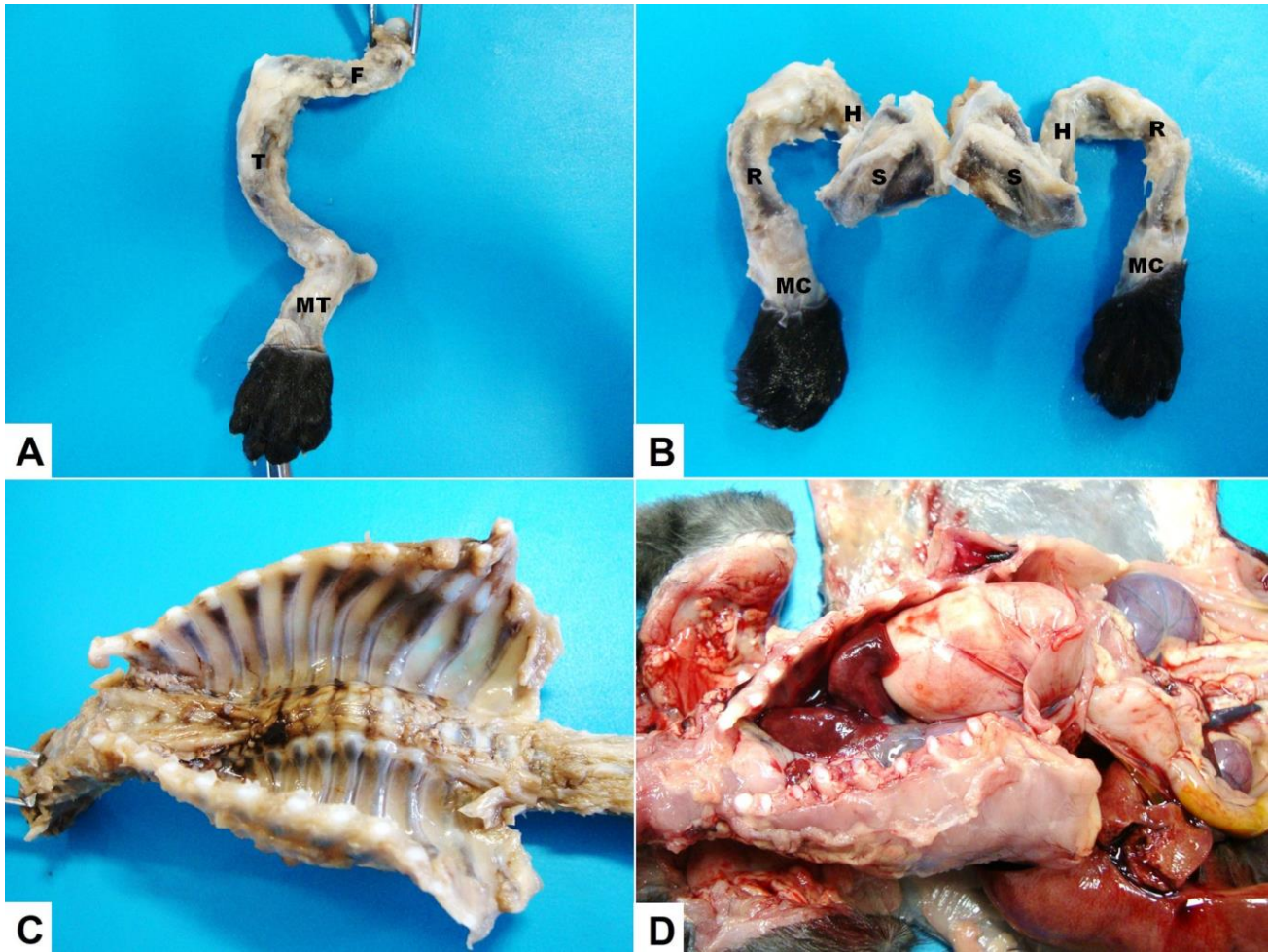


Figure 2. Co-occurrence of osteogenesis imperfecta-like phenotype and congenital diaphragmatic hernia in a kitten. (A) Left femur (F) and tibia (T) curved in the diaphyseal region. (B) Humerus (H) and radius (R) of the right and left sides and the left scapula (S) curved in the diaphyseal region. (MT: metatarsus; MC: metacarpus) (C) Cervical and thoracic vertebrae curved dorsal-ventral. (D) Stomach descended into the thoracic cavity through an aperture on the left dorsolateral region of the diaphragm.

The bones, teeth and fragments of all organs and tissues with and without visible lesions were fixed in 10% neutral phosphate-buffered formalin for histopathological analysis. The bones were dissected, radiographed and then decalcified in formic acid solution. The teeth were also decalcified according to the same procedure as the bones. The decalcified bones, teeth and soft tissues were embedded in paraffin, cut at 5 μ m, and stained with hematoxylin-eosin (HE).

The bones, teeth and soft tissues of a cat of the same age and with similar weight that came to death during surgery for anal atresia correction were processed similarly to the abnormal cat bones and used as control for histopathological analysis.

Microscopically, some long bones and vertebral bodies still had cartilaginous epiphysis predominantly attached to the epiphyseal plate with absence of secondary ossification centers or incipient formation. The bones with ossification center were in early stages of formation, and

the trabecular bones were thin and few and surrounded by abundant cartilaginous tissue (Fig. 3A), unlike the control cat bones, which had the cartilaginous epiphysis entirely replaced by trabecular bone (Fig. 3B).

The epiphyseal plates in some bones remained attached to the cartilaginous epiphysis and were less differentiated compared with the control animal. Further, the hypertrophic zone was thick and without vascular invasion (Fig. 3A and 3B). In the long bones and vertebrae, the trabecular bone tissue had intensely thin trabeculae and no connection between bones (Fig. 3C). The long bones and vertebrae were coated with a layer of bulky cuboidal osteoblasts. The osteocytes within the trabecular had the small core with a narrow lacune, or the core was bulky with an enlarged lacune. Rare osteoclasts were observed. In contrast, the control cat had thick trabecular bones that were connected to each other (Fig. 3D). However, the bone cell characteristics were similar to those of the abnormal cat.

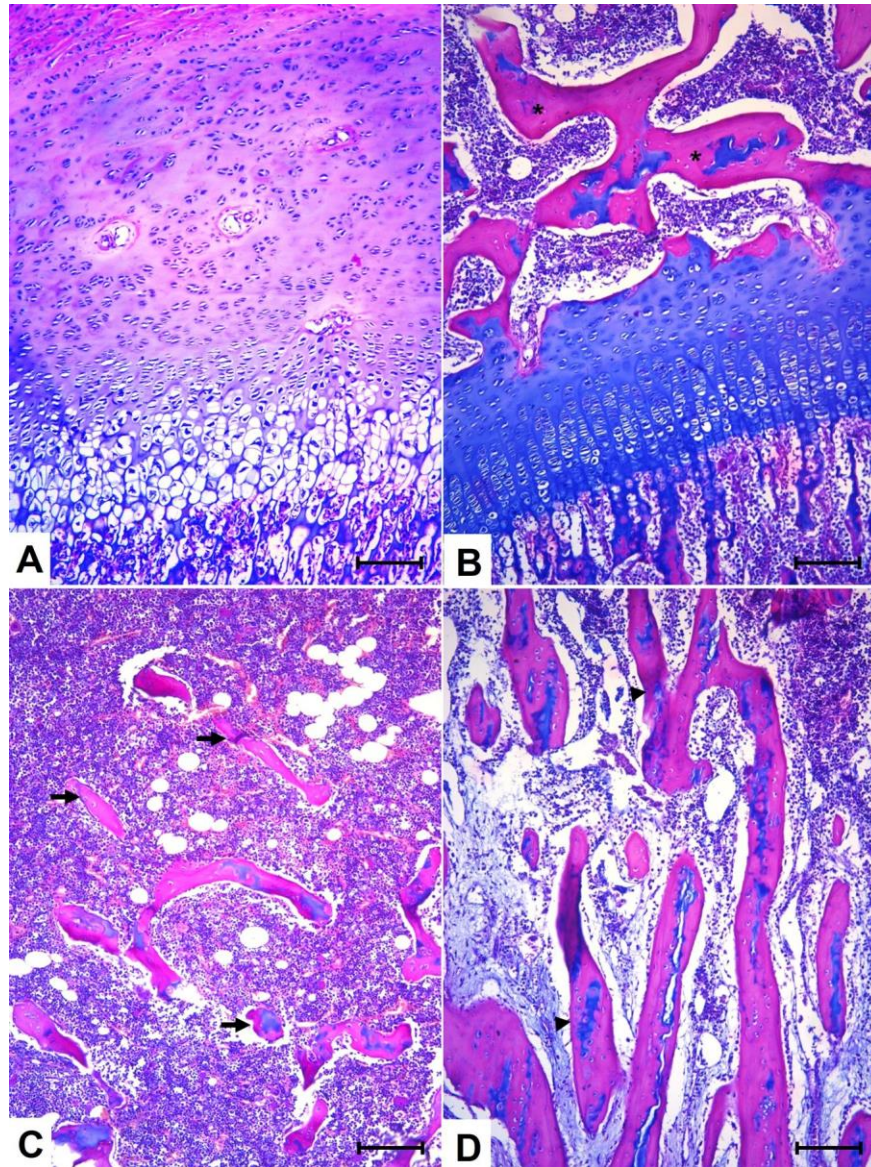


Figure 3. Co-occurrence of osteogenesis imperfecta-like phenotype and congenital diaphragmatic hernia in a kitten. (A) Cartilaginous epiphysis of the kitten predominantly attached to the epiphyseal plate with absence of secondary ossification centers or incipient formation. (B) Cartilaginous epiphysis of the control cat entirely replaced by trabecular bone (asterisk). (C) Trabecular bone tissue of the kitten with intensely thin trabeculae and no connection between them (arrows). (D) Trabecular bone tissue of the control cat with thick trabeculae and connections between tissues (arrowhead). (Hematoxylin-Eosin stain; Bar = 360 μ m).

The cortical long bones, vertebrae, skull and ribs were thin and discontinuous and predominantly composed of trabecular bone without osteon formation. In some areas, the cortical bones were nonexistent (Fig. 4A), unlike the control cat, which had thick cortical bones and primary osteon formation (Fig. 4B). In the bone callus region of the

long bones, the diaphysis had intense new bone formation from the endosteum toward the medullar canal. The trabecular bones were formed by immature tissue (woven bone) and coated with one or more layers of bulky osteoblasts with oval nuclei. The osteocytes were oval and had a large nucleus within extended lacunes.

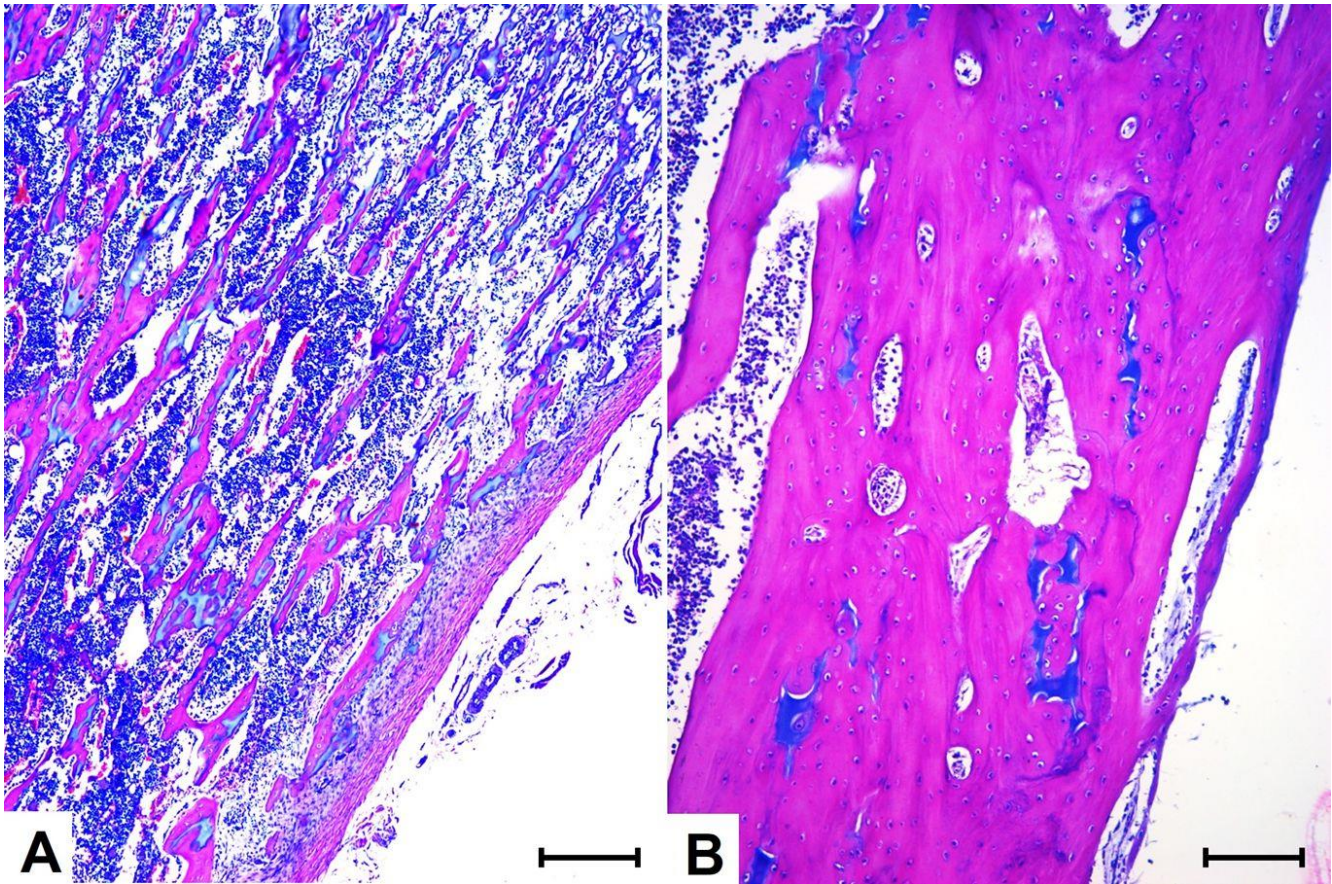


Figure 4. Co-occurrence of osteogenesis imperfecta-like phenotype and congenital diaphragmatic hernia in a kitten. (A) Cortical bone of the kitten was thin, discontinuous and predominantly composed of trabecular bone without osteon formation. (B) Cortical bone of the control cat was thick and exhibited primary osteon formation. (Hematoxylin-Eosin stain; Bar = 180 μ m).

The right lung had intense congestion, and the left lung exhibited extensive areas of intense atelectasis characterized by alveoli collapse and intense reduction of the alveolar space. The other organs, including the skin, eyes, teeth, thyroid and parathyroid, had no significant changes.

Discussion

This animal had limited mobility at birth and macro- and microscopic radiological bone changes consistent with the diagnosis of osteogenesis imperfecta, whose main features are radiolucency around the skeleton, the presence of thin cortical and trabecular bones, enlargement of the medullar canal and presence of pathological fractures (non-traumatic) with discrete bone callus. These bone changes have also been reported in other cases of OI in cats (19) and dogs (25). As in the present study, in some OI cases, the diagnosis is based on the clinical and pathological features of the disease, both in animals (6, 11, 19) and humans (9). Although the clinical diagnosis can be based on these characteristics, disease confirmation is based on examining gene mutations encoding type I collagen. However, a negative result of

this mutation does not exclude an OI diagnosis because OI is not always associated with mutations in genes encoding type I collagen (22). In fibroblast cultures taken from children with OI, mutations in the genes encoding BMP-1 were observed (15).

In this case, the differential diagnosis included metabolic bone diseases, such as general fibrous osteodystrophy caused by nutritional and secondary or primary renal hyperparathyroidism, rickets caused by primary or secondary calcium and/or phosphorus deficiency and osteoporosis. Generalized fibrous osteodystrophy is characterized histologically by severe osteolysis and osteocytic osteoclasia associated with the replacement of bone tissue by fibrous tissue, which is associated with hyperplasia and hypertrophy of parathyroid cells or cancer, depending on the type of hyperparathyroidism (14). All of these changes were absent in the bone tissue sections and parathyroid. In addition, clinical changes resulting from osteodystrophy not manifest at birth were observed in this animal. In cats, the clinical manifestation of fibrous osteodystrophy commonly occurs from four to eight months of age (24). Rickets was also excluded. With rickets, swelling of the costo-chondral junctions and epiphyses of long bones is

commonly observed. Areas of osteoid accumulation and osteoblastic hyperplasia are observed with microscopy (14). These macro- and microscopic changes were not observed here. The diagnosis of osteoporosis was excluded because osteoblastic coating covering all bone surfaces was observed, and most osteoblasts were cuboidal, unlike that observed in osteoporosis. With osteoporosis, osteoblastic insufficiency is microscopically characterized by atrophy, and osteoblastic hypoplasia is observed (14).

Although OI is associated with changes in the teeth, skin and eyes, this animal did not present changes in these tissues. Some human cases of OI also do not exhibit changes in these tissues. Thus, human OI is divided into seven subtypes according to the severity of the bone disorders and extra-skeletal characteristics observed (22).

Hernias are extra-skeletal manifestations that are also associated with OI in humans and are commonly represented by inguinal hernias (18) and more rarely by congenital diaphragmatic hernia (9, 26). A pleuroperitoneal congenital diaphragmatic hernia, as observed here, is considered rare in cats (20, 27), unlike the peritoneum-pericardial diaphragmatic hernia most commonly observed in this species (13). To the best of our knowledge, this report is the first documented case of the co-occurrence of OI and congenital diaphragmatic hernia in animals. The diaphragmatic hernia in this animal was considered congenital because of the clinical signs of dyspnea from birth, lack of history of trauma or traumatic injury and the macro- and microscopic characteristics of the diaphragm hole, which showed no bleeding or scarring, as would be expected with a traumatic hernia.

Congenital diaphragmatic hernia is characterized by the presence of a hole in the posterolateral region of the diaphragm, more frequently on the left side (28), similar to that observed here. Although congenital diaphragmatic hernia in humans is associated with miscarriage or stillbirth (28), in some cases, when the hernia is corrected and the animal does not come to death, bone deformities, such as *pectus excavatum* and scoliosis, occur due to the respiratory clinical condition (21, 29). These bone changes were not observed here, although the cat survived without hernia correction until two months of age.

OI can occur as congenital diaphragmatic hernia via genetic mutations (9). Although several factors involved in the etiology of hernias (3), changes in collagen synthesis, with increasing amounts of type III collagen relative to type I collagen, can lead to hernia, particularly inguinal hernia (12, 17). However, the etiology of congenital diaphragmatic hernia is mostly unknown (28). Mutations in the genes encoding lysyl oxidase and collagen 3a1 and the genes associated with retinoic acid synthesis can compromise the development of the extracellular matrix, causing congenital diaphragmatic hernia (16).

In humans, OI is hereditary and is in most cases caused by autosomal dominant mutations in the genes encoding for type I collagen (23). However, in some

animals, such as Friesian calves, OI has also exhibited characteristics of hereditary disease (8). Here, it was not possible to determine whether the changes presented by the animal were hereditary because the mother and her reproductive history are unknown.

Conclusions

Based on clinical, radiological, macroscopic and microscopic findings, a diagnosis of osteogenesis imperfecta and congenital diaphragmatic hernia in a kitten was confirmed.

References

1. AGERHOLM JS., LUND AM., BLOCH B., REIBEL J., BASSE A., ARNBJERG J. Osteogenesis imperfecta in Holstein-Friesian calves. **J. Vet. Med.**, 1994, 41, 128-138.
2. ARTHUR DG., THOMPSON KG., SWARBRICK P. Lethal osteogenesis imperfecta and skin fragility in newborn New Zealand Romney lambs. **N. Z. Vet. J.**, 1992, 40, 112-116.
3. BENDAVID R. The unified theory of hernia formation. **Hernia**, 2004, 8, 171-176.
4. CAMPBELL BG., WOOTTON JA., MACLEOD JN., MINOR RR. Canine COL1A2 mutation resulting in C-terminal truncation of pro-alpha2(I) and severe osteogenesis imperfecta. **J. Bone Miner. Res.**, 2001, 16, 1147-1153.
5. CAMPBELL BG., WOOTTON JA., MACLEOD JN., MINOR RR. Sequence of normal canine COL1A1 cDNA and identification of a heterozygous alpha1(I) collagen Gly208Ala mutation in a severe case of canine osteogenesis imperfecta. **Arch. Biochem. Biophys.**, 2000, 384, 37-46.
6. COHN LA., MEUTEN DJ. Bone fragility in a kitten: an osteogenesis imperfecta-like syndrome. **J. Am. Vet. Med. Assoc.**, 1990, 197, 98-100.
7. COOP MC. A treatment for osteogenesis imperfecta in kittens. **J. Am. Vet. Med. Assoc.**, 1958, 132, 299-300.
8. DENHOLM LJ., COLE WG. Heritable bone fragility, joint laxity and dysplastic dentin in Friesian calves: a bovine syndrome of osteogenesis imperfecta. **Aust. Vet. J.**, 1983, 60, 9-17.
9. DHOLAKIA S., CLEEVE S. Osteogenesis imperfecta and congenital diaphragmatic hernia. **BMJ Case Rep.**, 2013, 22, 2013.
10. DRÖGEMÜLLER C., BECKER D., BRUNNER A., HAASE B., KIRCHER P., SEELIGER F., FEHR M., BAUMANN U., LINDBLAD-TOH K., LEEB T. A missense mutation in the SERPINH1 gene in Dachshunds with osteogenesis imperfecta. **PLoS Genet.**, 2009, 5, e1000579.
11. EVASON MD., TAYLOR SM., BEBCHUK TN. Suspect osteogenesis imperfecta in a male kitten. **Can. Vet. J.**, 2007, 48, 296-298.

12. FRIEDMAN DW., BOYD CD., NORTON P., GRECO RS., BOYARSKY AH., MACKENZIE JW., DEAK SB. Increases in type III collagen gene expression and protein synthesis in patients with inguinal hernias. **Ann. Surg.**, 1993, 218, 754-760.
13. HODGKISS-GEERE HM., PALERMO V., LIUTI T., PHILBEY AW., MARQUES A. Pericardial cyst in a 2-year-old Maine Coon cat following peritoneopericardial diaphragmatic hernia repair. **J. Feline Med. Surg.**, 2014, 17, 381-386.
14. KROOK L. **Metabolic disease of bone and bones.** Cornell University, New York 1983.
15. MARTÍNEZ-GLEZ V., VALENCIA M., CAPARRÓS-MARTÍN JA., AGLAN M., TEMTAMY S., TENORIO J., PULIDO V., LINDERT U., ROHRBACH M., EYRE D., GIUNTA C., LAPUNZINA P., RUIZ-PEREZ VL. Identification of a mutation causing deficient BMP1/mTLD proteolytic activity in autosomal recessive osteogenesis imperfecta. **Hum. Mutat.**, 2012, 33, 343-350.
16. MERRELL AJ., KARDON G. Development of the diaphragm, a skeletal muscle essential for mammalian respiration. **FEBS. J.**, 2013, 280, 4026-4035.
17. MEYER AL., BERGER E., MONTEIRO JRO., ALONSO PA., STAVALE JN., GONÇALVES MP. Quantitative and qualitative analysis of collagen types in the fascia transversalis of inguinal hernia patients. **Arq. Gastroenterol.**, 2007, 44, 230-234.
18. MURRAY M. Nyhus and Condon's Hernia, 5 ed. **Ann. Surg.**, 2002, 236, 693.
19. OMAR AR. Osteogenesis imperfect in cats. **J. Path. Bact.**, 1961, 82, 303-314.
20. PARRY A. Positive contrast peritoneography in the diagnosis of a pleuroperitoneal diaphragmatic hernia in a cat. **J. Feline Med. Surg.**, 2010, 12, 141-143.
21. PEETSOLD MG., HEIJ HA., KNEEPPKENS CM., NAGELKERKE AF., HUISMAN J., GEMKE RJ. The long-term follow-up of patients with a congenital diaphragmatic hernia: a broad spectrum of morbidity. **Pediatr. Surg. Int.**, 2009, 25, 1-17.
22. RAUCH F., GLORIEUX FH. Osteogenesis imperfect. **The Lancet**, 2004, 363, 1377-1385.
23. ROWE DW., SHAPIRO JR. Osteogenesis imperfecta. AVIOLI LV., KRANE SM. (Eds). **Metabolic Bone Disease.** 3 ed., Acad Pr, London 1998:651-695.
24. SCOTT P. Osteodystrophies. **Vet. Rec.**, 1969, 84, 333-335.
25. SEELIGER F., LEEB T., PETERS M., BRUGMANN M., FEHR M., HEWICKER-TRAUTWEIN M. Osteogenesis imperfecta in two litters of dachshunds. **Vet. Pathol.**, 2003, 40, 530-539.
26. SPENCE PA., COHEN Z., SALERNO TA. Strangulated diaphragmatic hernia in a patient with osteogenesis imperfecta. **Can. Med. Assoc. J.**, 1984, 131, 1369-1370.
27. THRALL DE. **Textbook of Veterinary Diagnostic Radiology**, 2 ed., WB Saunders, Philadelphia 1994:271-272.
28. TOVAR JA. Congenital Diaphragmatic Hernia. **Orphanet. J. Rare. Dis.**, 2012, 7, 1.
29. VANAMO K., PELTONEN J., RINTALA R., LINDAHL H., JÄÄSKELÄINEN J., LOUHIMO I. Chest wall and spinal deformities in adults with congenital diaphragmatic defects. **J. Pediatr. Surg.**, 1996, 31, 851-854.