BJVP
Brazilian Journal of Veterinary Pathology
ISSN 1983-0246

Case Report

Cystitis and peritonitis caused by *Staphylococcus xylosus* infection in a calf

Daniel R. Rissi[1*], Elizabeth J. Elsmo[1], Susan Sanchez[2]

[1] Department of Pathology and Athens Veterinary Diagnostic Laboratory, College of Veterinary Medicine, The University of Georgia, Athens, GA, USA.
[2] Department of Infectious Diseases and Athens Veterinary Diagnostic Laboratory, College of Veterinary Medicine, The University of Georgia, Athens, GA, USA.
*** Corresponding Author:** Dr. Daniel R. Rissi, Department of Pathology and Athens Veterinary Diagnostic Laboratory, College of Veterinary Medicine, The University of Georgia, Athens, GA 30602. Phone: 706 542 5916. E-mail: rissi@uga.edu

Submitted July 30th 2015, Accepted September 8th 2015

Abstract

Staphylococcus xylosus is a Gram-positive coagulase-negative staphylococcus with hemolytic activity and ability to form biofilms. This organism can be a component of the human skin microbiome, with rare reported cases of opportunistic infections. *S. xylosus* can be also isolated from the skin of healthy cattle, horses, pigs, dogs, laboratory mice, chickens, and pigeons. Reports of disease caused by *S. xylosus* are rare in veterinary medicine, with cases of bovine and ovine mastitis and dermatitis, and pneumonia in immunocompromised laboratory mice. This report describes the first case of transmural necrotizing cystitis and secondary peritonitis caused by *S. xylosus* in a 4-month-old male Holstein calf with a history of acute onset of recumbency and spontaneous death. Gross necropsy findings included marked urinary bladder distention and diffuse reddening, and large amounts of dark red, hemorrhagic contents. In addition, segments of small intestine and mesentery were adhered to the urinary bladder. Histological evaluation revealed transmural necrosuppurative cystitis with secondary peritonitis and intralesional Gram-positive and fewer Gram-negative cocci. Bacterial culture of urine samples yielded heavy growth of *S. xylosus*.

Key words: *Staphylococcus xylosus*, cystitis, peritonitis, calf.

Introduction

Staphylococcus xylosus are coagulase-negative, Gram-positive cocci that are widely distributed in the environment, as well as commensal organisms in the skin and mucosal surfaces of mammals (especially mice and humans) and birds (5). *S. xylosus* are normally nonpathogenic and utilized as a starter culture for meat products (12). However, opportunistic infections have been described in the veterinary and human medical literature. Animal infections include mastitis in cattle and sheep, dermatitis in gerbils and immunodeficient mice, and pulmonary and lymph node lesions in immunodeficient mice (3, 6, 9, 14, 18). Clinical disease in humans is characterized by septicemia, endocarditis, pyelonephritis, cerebral abscesses, and suppurative keratitis (1, 2, 7, 8, 10, 15).

Case Report

This report describes a case of transmural necrotizing cystitis and secondary peritonitis caused by *S. xylosus* in a 4-month-old male Holstein calf with history of acute onset of recumbency. The calf spontaneously died and was necropsied by the referring veterinarian. Reported gross necropsy findings included marked urinary bladder distention and transmural reddening with large amounts of dark red contents. In addition, segments of small intestine and mesentery were adhered to the urinary bladder. No other changes were observed and no evidence of urethral

 All rights reserved 2007.

obstruction was detected during necropsy. Formalin-fixed samples of urinary bladder, kidney, and small intestines were submitted for histological evaluation and fresh samples of kidney and urinary bladder contents were submitted for aerobic bacterial culture and fluorescent antibody testing (FAT) for *Leptospira* spp.

Histological examination revealed a transmural necrosuppurative cystitis (Fig. 1) with secondary suppurative peritonitis and intralesional Gram-positive cocci with fewer Gram-negative cocci (Fig. 2). Bacterial aerobic culture on blood agar of the bladder contents yielded heavy and pure growth of *S. xylosus* that was identified by colony morphology, Gram stain and MALDITOF (Matrix Assisted Laser Desorption Ionization Time of Flight). Fresh samples of kidney were negative for *Leptospira* spp. on FAT.

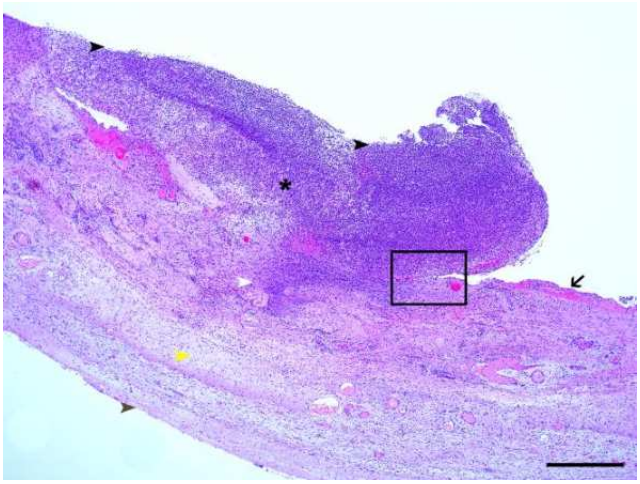

Figure 1. Urinary bladder, calf. Most of the urothelium (arrow) has been lost (black arrowheads) and replaced by severe suppurative inflammation (asterisk) that also extends to and partially effaces the submucosa (white arrowhead), muscle layers (yellow arrowhead), and serosal surface (brown arrowhead). HE. Bar = 1 mm.

Discussion

Coagulase-negative staphylococci are increasingly recognized as important pathogens in veterinary and human medicine, carrying multiple antibiotic resistance genes and causing nosocomial infections in immunocompromised human patients (16). *S. xylosus* infection in cattle appears to be restricted to the mammary gland and no lesions in internal organs have previously been described in this species (3, 6, 9, 14, 18). The calf of the present report had diffuse, transmural, suppurative cystitis that most likely culminated in uroperitoneum and subsequent fibrinosuppurative peritonitis due to leakage of urine, bacteria, and inflammatory exudate from the diffusely damaged bladder wall. The primary source of bacterial infection could not be determined, but since *S. xylosus* naturally occurs in the environment and inhabits animal skin and mucosal surfaces (including prepuce and vagina), environmental transmission and/or ascending infection from the prepuce was considered the most likely pathogenic mechanism in this case (5, 19).

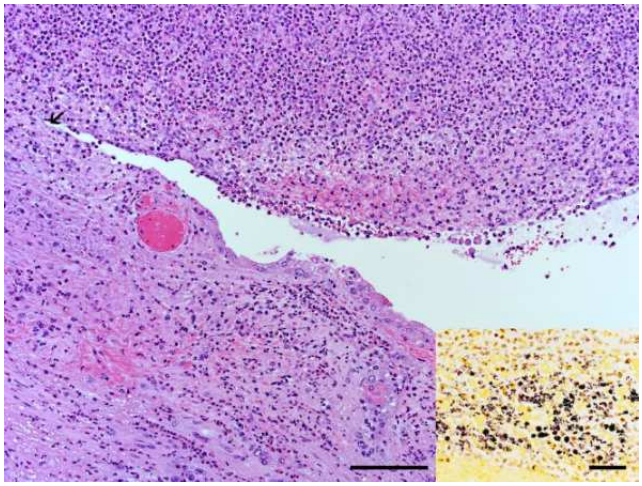

Figure 2. Urinary bladder, calf. Closer view of the squared area shown in Fig. 1. There is abrupt urothelial loss and ulceration (arrow) with accumulation of numerous neutrophils and hemorrhage (top). HE. Bar = 100µm. Inset: Intralesional Gram-positive bacterial cocci. Brown and Brenn. Bar = 100 µm.

Bovine cystitis is an important clinical entity that can occur as an isolated lesion or can ascend to the ureters and kidneys, leading to concurrent ureteritis and pyelonephritis, respectively (4, 11, 13, 19). Clinical disease occurs worldwide and has been most commonly associated with infection by *Corynebacterium renale*, *C. cystidis*, *C. pilosum*, *Trueperella pyogenes*, and *Escherichia coli* (11, 13, 17). Major risks and predisposing factors associated with these infections include gender (females are more susceptible due to their shorter urethra), parturition, urinary stasis due to an atonic bladder or obstruction, urethral trauma, inadequate sanitation, and poor husbandry in a contaminated environment (19). Clinical signs may be characterized by stranguria, hematuria and/or pyuria, and arched stance. Systemic signs, including anorexia, fever, colic, weight loss, and decreased milk production, may appear as the infection ascends to the upper urinary tract (11, 19). Pathological findings typically consist of fibrinous or suppurative cystitis with luminal hemorrhage, with or without ureteral and renal enlargement due to edema and inflammation (4, 11, 13, 19).

In conclusion, the current report briefly describes the first case of bovine cystitis and peritonitis by *S. xylosus*. These results highlight the importance of bacterial culture in cases of urinary tract disease in cattle, since it may detect infection by uncommon and potentially emerging or zoonotic pathogens that may be of public health importance.

References

1. AKHADDAR A., ELOUENNASS M., NAAMA O., BOUCETTA M. *Staphylococcus xylosus* isolated from an otogenic brain abscess in an adolescent. **Surg. Infect. (Larchmt).**, 2010, 11, 559-561.
2. BERNAT GARCIA A., ROIG RICO P., SANCHEZ ALDAS J., NIETO A. Acute endocarditis due to *Staphylococcus xylosus.* **Rev. Clin. Esp.**, 1992, 190, 213-214.
3. BRADFIELD JF., WAGNER JE., BOIVIN GP., STEFFEN EK., RUSSELL RJ. Epizootic fatal dermatitis in athymic nude mice due to *Staphylococcus xylosus.* **Lab. Anim. Sci.**, 1993, 43, 111-113.
4. BRAUN U., NUSS K., WEHBRINK D., RAUCH S., POSPISCHIL A. Clinical and ultrasonographic findings, diagnosis and treatment of pyelonephritis in 17 cows. **Vet. J.**, 2008, 175, 240-248.
5. DORDET-FRISONI E., DORCHIES G., DE ARAUJO C., TALON R., LEROY, S. Genomic diversity in *Staphylococcus xylosus.* **Appl. Environ. Microbiol.**, 2007, 73, 7199-7209.
6. FTHENAKIS GC., MARPLES RR., RICHARDSON JF., JONES JE. Some properties of coagulase-negative staphylococci isolated from cases of ovine mastitis. **Epidemiol. Infect.**, 1994, 112, 171-176.
7. HRICAK V., KOVACIK J., MARKS P., WEST D., KROMERY V., JR. Aetiology and outcome in 53 cases of native valve staphylococcal endocarditis. **Postgrad. Med. J.**, 1999, 75, 540-543.
8. KOKSAL F., YASAR H., SAMASTI M. Antibiotic resistance patterns of coagulase-negative staphylococcus strains isolated from blood cultures of septicemic patients in Turkey. **Microbiol. Res.**, 2009, 164, 404-410.
9. MIEDZOBRODZKI J., NAIDU AS., WATTS JL., CIBOROWSKI P., PALM K., WADSTROM T. Effect of milk on fibronectin and collagen type I binding to *Staphylococcus aureus* and coagulase-negative staphylococci isolated from bovine mastitis. **J. Clin. Microbiol.**, 1989, 27, 540-544.
10. PINNA A., ZANETTI S., SOTGIU M., SECHI L.A., FADDA G., CARTA F. Identification and antibiotic susceptibility of coagulase negative staphylococci isolated in corneal/external infections. **Br. J. Ophthalmol.**, 1999, 83, 771-773.
11. REBHUN WC., DILL SG., PERDRIZET JA., HATFIELD CE. Pyelonephritis in cows: 15 cases (1982-1986). **J. Am. Vet. Med. Assoc.**, 1989, 194, 953-955.
12. RESCH M., NAGEL V., HERTEL C. Antibiotic resistance of coagulase-negative staphylococci associated with food and used in starter cultures. **Int. J. Food. Microbiol.**, 2008, 127, 99-104.
13. ROSENBAUM A., GUARD CL., NJAA BL., MCDONAGH PL., SCHULTZ CA., WARNICK LD., WHITE ME. Slaughterhouse survey of pyelonephritis in dairy cows. **Vet. Rec.,** 2005, 157, 652-655.
14. SOLOMON HF., DIXON DM., POUCH W. A survey of staphylococci isolated from the laboratory gerbil. **Lab. Anim. Sci.**, 1990, 40, 316-318.
15. TSELENIS-KOTSOWILIS AD., KOLIOMICHALIS MP., PAPAVASSILIOU JT. Acute pyelonephritis caused by *Staphylococcus xylosus.* **J. Clin. Microbiol.**, 1982, 16, 593-594.
16. VON EIFF C., PETERS G., HEILMANN C. Pathogenesis of infections due to coagulase-negative staphylococci. **Lancet Infect. Dis.**, 2002, 2, 677-685.
17. WALLACE L.L., BOUCHARD G., NICHOLSON W., TURK J., SWEENEY CL. Polypoid cystitis, pyelonephritis, and obstructive uropathy in a cow. **J. Am. Vet. Med. Assoc.**, 1990, 197, 1181-1183.
18. WON YS., KWON HJ., OH GT., KIM BH., LEE CH., PARK Y.H., HYUN BH., CHOI YK. Identification of *Staphylococcus xylosus* isolated from C57BL/6J-Nos2(tm1Lau) mice with dermatitis. **Microbiol. Immunol.**, 2002, 46, 629-632.
19. YERUHAM I., ELAD D., AVIDAR Y., GOSHEN T. A herd level analysis of urinary tract infection in dairy cattle. **Vet. J.**, 2006, 171, 172-176

 All rights reserved 2007.