



Case Report

Nasal polyposis in a cow

Roberta P. Duarte*, Paulo Ricardo D. Rocha, Augusto Schweigert,
 Fernando C. G. Morelli, Gisele F. Machado

Faculdade de Medicina Veterinária, Universidade Estadual Paulista Júlio de Mesquita Filho - UNESP, Araçatuba, SP, Brazil.

* **Corresponding author:** E-mail: robertapicciuto.medvet@hotmail.com

Submitted August 13th 2015, Accepted September 14th 2015

Abstract

A case report of nasal polyps in an eight year-old Tabapuã cow is reported. The cow had a history of difficulty in breathing, was euthanatized and referred for necropsy. Twenty three pedunculated neoformations were observed in the nasal cavity. Microscopically, polypoid structures were composed by swollen myxomatous stroma lined by pseudostratified columnar epithelium. Immunohistochemistry was positive for cytokeratin in the cytoplasm of epithelial cells only covering the pseudo-stratified respiratory epithelium, whereas anti-vimentin antibody was positive in the cytoplasm of cells and areas of calcification of the tunica media of blood vessels and fibroblasts within the parenchyma of the polyps. The macroscopy, histopathological, and immunohistochemical findings were consistent with nasal polyps. This is the first report of nasal polyposis in a cow in Brazil.

Key words: polyp, bovine, nasopharyngeal obstruction, upper respiratory tract.

Introduction

Nasal polyps are non-neoplastic structures that rise from the mucosal surface expanding to the nasal cavity, usually due to a chronic inflammatory process (7, 16). Macroscopically, polyps are spherical, ovoid or elongated firm nodules of various sizes, which protrude from the mucosa into the nasal cavity (7, 16). Nasal polyps are initially sessile; however, when larger, they may become pedunculated (2). The surface can be smooth, ulcerated, hemorrhagic and/or present secondary infection (7). Polyps are sometimes multiple and may cause respiratory difficulty due to the obstruction of the nasopharynx (16) and subsequent death due to asphyxiation (13). Histologically, polyps are characterized by edematous fibrous tissue covered by regular respiratory epithelium or stratified squamous epithelium (16) and by a lymphocytic inflammatory infiltrate (7). Clinical signs are not specific; increased respiratory effort, stertorous inspiration, nasal discharge and/or epistaxis are the most clinically observed signs (13, 15).

Nasal polyps occur infrequently in animals. In horses, there is a condition called progressive ethmoid hematoma or hemorrhagic nasal polyp. In cats, polyps can affect the ear canal and even the middle ear (2, 16). In goats, nasal polyps have been described as enzootic intranasal tumors (4). Nasal polyposis is one of the disorders less commonly reported in cattle (11). The aim of this article was to describe a case report of nasal polyp in a cow by means of necropsy, histopathology and immunohistochemistry.

Case report

An eight year-old purebred Tabapuã cow was referred to the Veterinary Pathology service at UNESP (Araçatuba, Brazil), after humane euthanasia. The cow had history of difficulty breathing, and therapy was unsuccessful. Clinical signs started about six months before the death and when the animal was submitted to management, respiratory difficulty was more noticed. The cow presented respiratory sounds that became more severe with time and were audible even at a considerable distance.

The animal was vaccinated for brucellosis, foot-and-mouth disease, and blackleg, and was also dewormed. The cow lived only on pasture away from roads and industries. Because of the respiratory signs, the tuberculin test was done, but the result was negative.

At necropsy, the animal had a good body condition without ectoparasites. Ocular, oral and vaginal mucosa were normal. In the nasal cavity, 23 pedunculated neoformations of various sizes (from 4-15 cm long) with ovoid end, smooth surface, grey in color, soft (gelatinous) and multifocal insertions in nasal epithelium of the cribriform plate were observed (Fig. 1). On cut surface, multifocal, firm white masses resembling calcifications were observed in the center of polyps (Fig. 2). In the lungs, especially in the ventral portion of the cranial lobes, dark red symmetrically focally extensive areas of consolidation were observed. When cut, multifocal nodules filled with yellow (purulent) exudate were present. The bronchi were filled by the same exudate. No significant changes were observed in other organs. Lungs, heart, liver, spleen, intestines, kidneys and nasal neoformations fragments were collected, fixed in 10% buffered formalin, trimmed, routinely embedded in paraffin, sectioned at 5µm thickness and stained with hematoxylin and eosin for histopathological analysis.

Microscopically, the polypoid structures were composed by swollen myxomatous stroma lined by pseudostratified columnar epithelium (Fig. 3). In the stroma and sub-epithelial layer, multifocal lymphocytic and macrophagic inflammatory infiltrate were observed, respectively. Moreover, multifocal areas of cartilaginous metaplasia with ossification, characterized by densely basophilic trabecular formations with giant osteoblasts-like cells (Fig. 4), moderate marked neovascularization and multifocal glandular hyperplasia were also observed.

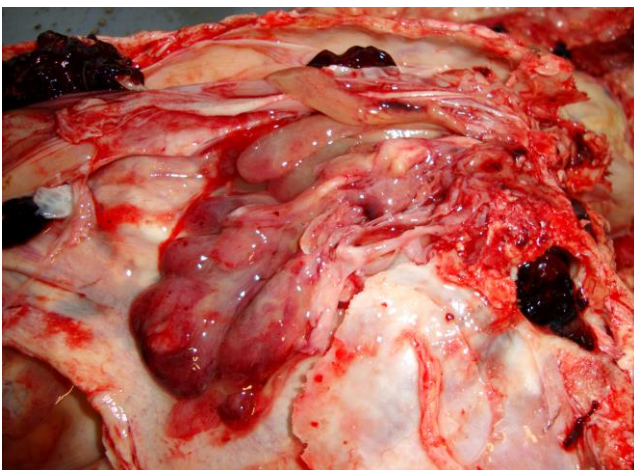


Figure 1. Cow, nasopharynx. Multiple nasal polyps with ovoid end, smooth surface, grey, soft (gelatinous) and multifocal insertions in nasal epithelium of the cribriform plate.

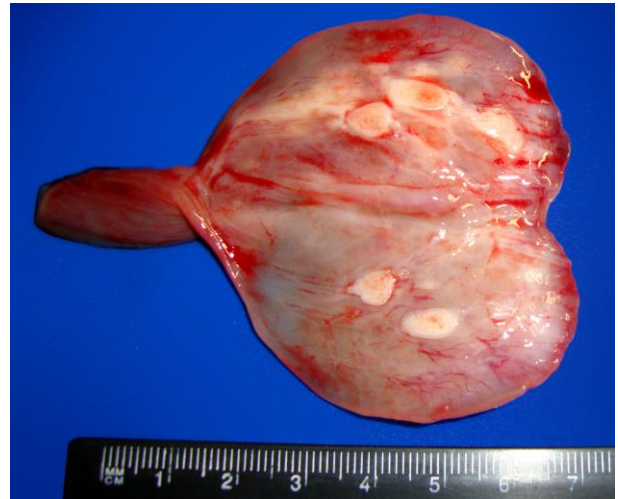

Figure 2. Cut surface of tissues shown in Fig. 1, firm, white mass with multifocal calcifications at the center of polyps.

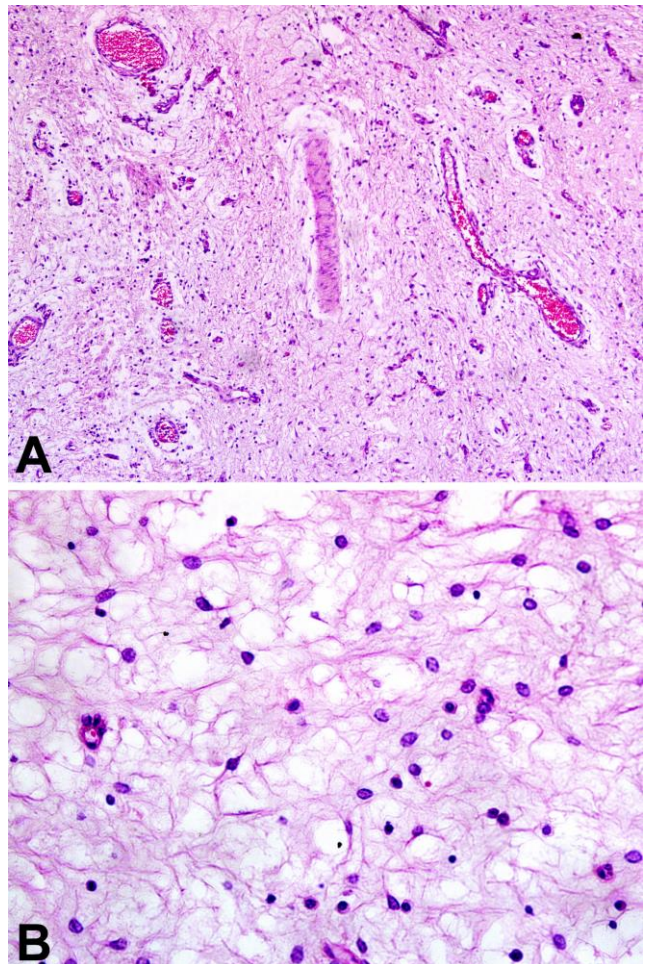


Figure 3. Swollen myxomatous stroma with multifocal neovascularization. Hematoxylin and Eosin, (A) 100x magnification. (B) 400x magnification.

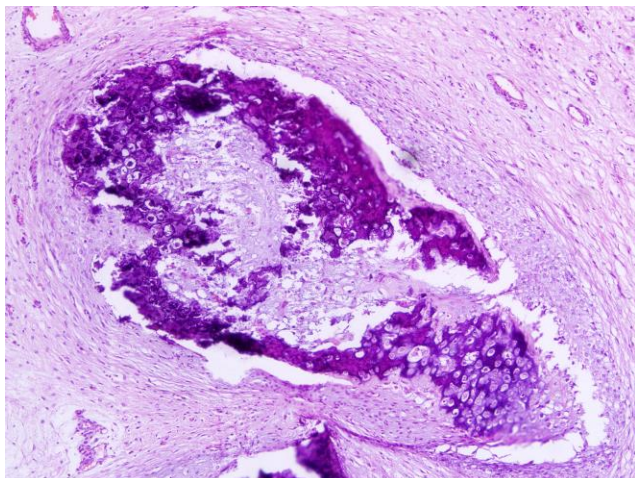


Figure 4. Multifocal areas of cartilaginous metaplasia with ossification, characterized by densely basophilic trabecular formations with giant osteoblasts-like cells. Hematoxylin and Eosin, 100x magnification.

Briefly, indirect immunohistochemistry (IHC) was performed using monoclonal primary antibodies (12) against cytokeratin (DAKO, Carpinteria, USA, Code M3515, 1:50) and vimentin (DAKO, Code M7020, 1:100). For antigen retrieval, all sections were incubated with citrate buffer (pH 6.0) at 125°C for 10 minutes. The secondary kit detection system LSAB2-HRP kit (Code K0679, DAKO, USA), biotin labeled goat anti-rabbit +goat anti-mouse was applied. Subsequently, permanent red was incubated for 30 minutes at room temperature (only for vimentin) and 3,3'- diaminobenzidine chromogen (DAB, DAKO, USA, cytokerin) was incubated for 1 minute at room temperature. Finally, the sections were counterstained using Mayer's hematoxylin. Positive controls included a mammary carcinoma from a dog and a normal skin from a bull. Sections of the neoplasm herein described and the positive controls without the incubation of the primary antibody were used as negative controls.

Anti-cytokeratin antibody was positive only in the cytoplasm of epithelial cells covering the pseudo-stratified respiratory epithelium and endothelium of blood vessels of polyps, whereas anti-vimentin antibody was positive cytoplasm of cells and areas of calcification of the tunica media of blood vessels and fibroblasts within the parenchyma of the polyps (Fig. 5 and 6).

Discussion

The gross histopathologic and immuno-histochemical findings of this case were consistent with the diagnosis of nasal polyps. Polyps diagnosis can be challenging (10). Diagnosis has been done by endoscopy, but radiograph can also help, and histopathology is the definite tool for the diagnosis (14). Initially, the externalization of the masses through the nostrils is an important signal for the clinical diagnosis of nasal

polyposis (1, 4, 6, 11, 13, 14, 15). In this case report, as the polyps were not externalized, the main suspected diagnosis was pneumonia unresponsive to treatment. RINGS and ROJKO (13) reported that of 11 sheep with signs of nasal obstruction, nine had previously been treated for pneumonia before definitive diagnosis, similar to this case report. The humane euthanasia of this cow was a diagnosis option since the referred Veterinarian was afraid of an infectious disease, so the cow was sacrificed for more detailed investigation.

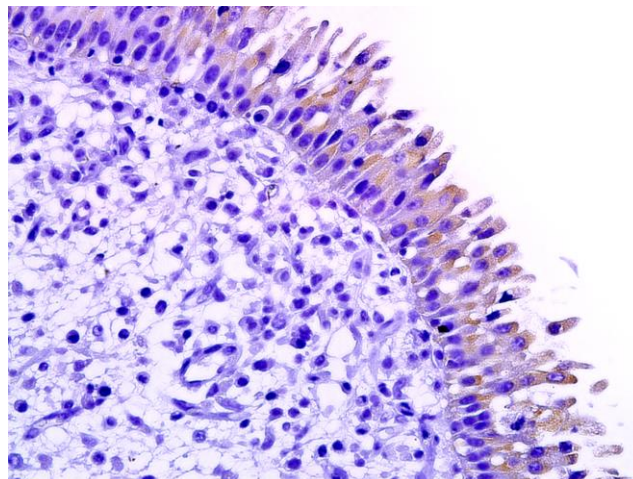


Figure 5. Immunopositivity for cytokeratin in the cytoplasm of pseudostratified epithelium. Immunohistochemistry with diaminobenzidine as chromogen, counterstained with hematoxylin, 400x magnification.

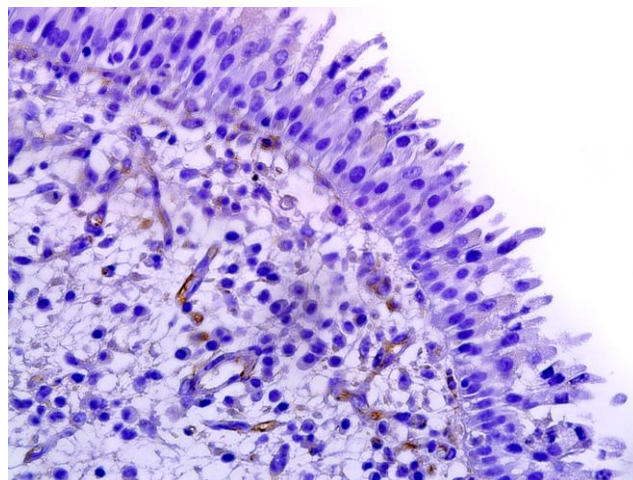


Figure 6. Immunopositivity for vimentin in the cytoplasm of fibroblasts. Immunohistochemistry with diaminobenzidine as chromogen, counterstained with hematoxylin, 400x magnification.

Among the differential diagnoses of nasal polyposis, many neoplastic processes like polypoid tumors, such as fibromas, papillomas and hemangiomas (16), as well as a wide range of carcinomas (14) should be considered. IHC can be very useful in distinguishing polyps and tumors, because it has been proved to be one of the most important ancillary techniques in the characterization of neoplastic diseases and their correspondent cell types (12).

The etiology of nasal polyps remains unknown in both humans and animals (3, 10, 13, 16). A case of nasal polyp in an Arab horse was reported and the authors suggested an infectious cause due to viral inclusions found both in polyps as in tumors associated with polyps, however, the authors disagree with this association (14). Rhinosporidiosis is a zoonotic disease characterized by nasal polyps caused by the mesomycetozoa *Rhinosporidium seeberi*. It affects many animals, primarily the horse, but has been reported in dogs (5), including in Brazil (9), and also in a cat (1). In humans, the incidence of nasal polyps is 4% of the population (10) and people with nasal polyps are more reactive to allergens than the general population, suggesting that an IgE mediated hypersensitivity reaction might be the key for the development of the disease (8).

Regarding histopathology, sharp lymphocytic infiltrate in the stroma, and the presence of macrophages mainly in sub-epithelial layer is consistent with the definition of nasal polyp (2, 3, 7, 16). In humans, eosinophils are the most common inflammatory cells in nasal polyps (8, 10). A large amount of eosinophils was also found in the inflammatory infiltrate in goats with enzootic intranasal tumors (8), as well as reported in rhinosporidiosis in pets (1, 5, 9).

In cats, inflammatory polyps of the nasal turbinates are distinguished histologically of nasopharyngeal polyps (6). Inflammatory polyps are characterized by the presence of bone tissue as part of stromal proliferation and there are gaps filled with erythrocytes, and these histologic characteristics are similar to nasal hamartoma in children (6). In this case report, the presence of bone tissue proliferation observed is similar to these findings in cats, except for the gaps filled by erythrocytes.

In humans, polyps were grouped in: (A) edematous or eosinophilic polyps; (B) fibroinflammatory polyps; (C) polyps with seromucinous gland hyperplasia; and (D) polyps with stromal atypia (3). Fibroinflammatory polyps features a marked inflammatory infiltrate containing mostly lymphocytes as well as a lack of stromal edema and goblet cell hyperplasia. Thus, based on this classification, the present case was classified as nasal polyps of mixed type with a fibroinflammatory component, hyperplasia of seromucinous glands, and bone tissue proliferation, like in cats (6).

This is the first report of nasal polyposis in a cow in Brazil. Although it is possible to classify nasal polyps in

four types in man, in veterinary medicine, this classification proved limited in this case report. Further studies focused on histologic findings of nasal polyps in domestic animals are needed, particularly in farm animals, in order to establish a proper classification.

References

1. BRENSEKE BM., SAUNDERS GK. Concurrent nasal adenocarcinoma and rhinosporidiosis in a cat. **J. Vet. Diagn. Invest.**, 2010, 22, 155-157.
2. CASWELL JL., WILLIAMS KJ. Respiratory System. MAXIE MG. (Ed). **Jubb, Kennedy, and Palmer's Pathology of Domestic Animals**. 5 ed., vol. 2. Saunders Elsevier, Philadelphia 2007: 533-534.
3. COUTO LGF., FERNADES AM., BRANDÃO DF., DE SANTI NETO D., VALERA FCP., ANSELMO-LIMA WT. Histological aspects of rhinosinusal polyps. **Braz. J. Otorhinolaryngol.**, 2008, 74, 2, 207-212.
4. DE LAS HERAS M., GARCIA DE JALON JA., SHARP JM. Pathology of enzootic intranasal tumor in thirty-eight goats. **Vet. Pathol.**, 1991, 28, 474-481.
5. EASLEY JR., MEUTEN DJ., LEVY MG., DYKSTRA MJ., BREITSCHWERDT EB., HOLZINGER EA., CATTLEY RC. Nasal rhinosporidiosis in the dog. **Vet. Pathol.**, 1986, 23, 50-56.
6. GRECI V., MORTELLARO CM., OLIVERO D., COCCI A., HAWKINS EC. Inflammatory polyps of the nasal turbinates of cats: an argument for designation as feline mesenchymal nasal hamartoma. **J. Fel. Med. Surg.**, 2011, 13, 213-219.
7. LÓPEZ A. Sistema respiratório. MCGAVIN MD., ZACHARY JF. (Eds). **Bases da Patologia em Veterinária**. 4 ed., Elsevier, Rio de Janeiro 2009: 485-486.
8. MUÑOZ DEL CASTILLO F., JURADO-RAMOS A., FERNÁNDEZ-COINDE BL., SOLER R., BARASONA MJ., CANTILLO E., MORENO C., GUERRA F. Allergenic profile of nasal polyposis. **J. Investig. Allergol. Clin. Immunol.**, 2009, 19, 2, 110-116.
9. NEVES CD., DUTRA NR., NETO FB., SILVEIRA LS. Canine nasal rhinosporidiosis: case report in Brazil. **Rev. Bras. Ciênc. Vet.**, 2014, 21, 4, 223-225.
10. NEWTON JR., AH-SEE KW. A Review of nasal polyposis. **Therap. Clin. R. Manag.**, 2008, 4, 2, 507-512.
11. NIGAM JM., SINGH AP., CHANDNA IS. Radiographic evaluation of bovine skull disorders. **Mod. Vet. Pract.**, 1981, 239-243.
12. RAMOS-VARA JA., KIUPEL M., BASZLER T., BLIVEN L., BRODERSEN B., CHELACK B., CZUB S., DEL PIERO F., DIAL S., EHRHART EJ., GRAHAM T., MANNING L., PAULSEN D., VALLI VE., WEST K. Suggested guidelines for

- immunohistochemical techniques in veterinary diagnostic laboratories. **J. Vet. Diagn. Invest.**, 2008, 20, 4, 393-413.
13. RINGS DM., ROJKO J. Naturally occurring nasal obstructions in 11 sheep. **Cornell Vet.**, 1985, 75, 269-276.
 14. WATT BC., BECK BE. Removal of a nasal polyp in a standing horse. **Can. Vet. J.**, 1997, 38, 108-109.
 15. WENZEL AM., WACK AN., BECK SE., BRONSON E. Pathology in practice. nasal and nasopharyngeal polyps. **J. Am. Vet. Med. Assoc.**, 2012, 241, 7, 885-887.
 16. WILSON DW., DUNGWORTH DL. Tumors of the respiratory tract. MEUTEN DJ. (Ed). **Tumors of Domestic Animals**. 4 ed., Iowa State Press, Ames 2002: 376-377.