



Original Full Paper

Adverse reactions to oil-emulsified (ISA-70) Newcastle disease vaccine in a pigeon flock

Ghasem Farjanikish^{1*}, Azizollah Khodakaram-Tafti², Amir H. Aslnajjari³

¹Department of Pathobiology, Faculty of Veterinary Medicine, Lorestan University, Khorram Abad, Iran.

²Department of Pathology, School of Veterinary Medicine, Shiraz University, Shiraz, Iran.

³Avian Disease Research Center, School of Veterinary Medicine, Shiraz University, Shiraz, Iran.

* **Corresponding author:** Ghasem Farjanikish, DVM, PhD of Veterinary Pathology, Faculty of Veterinary Medicine, Lorestan University, Khorram Abad, Iran. E-mail: farjanikish.gh@lu.ac.ir

Submitted December 31st 2015, Accepted March 24th 2016

Abstract

Oil adjuvants in combination with inactivated vaccines against several avian diseases are widely used. In spite of some advantages of oil adjuvants, a local tissue reaction has been reported in some animals. In this report, about 30 birds of a flock of pigeons with 40 birds, developed scattered small to large nodules about 5 mm to 2 cm in diameter in subcutaneous tissues and pectoral muscles after intramuscularly injection of an oil-emulsified (ISA-70) Newcastle disease vaccine. Histopathologic examination showed granulomatous and cystic reactions in the site of injection. Bacteriological examinations as well as fresh smears stained with Ziehl-Neelsen, Brown-Brenn Gram and PAS stains were void of bacteria or fungi. It may be prudent to consider the potential for induction of adverse reaction of vaccine formulations containing mineral oils as adjuvant in pigeons.

Key words: ISA-70, vaccine reactions, granulomatous and cystic lesions, pigeon.

Introduction

Currently, oil adjuvants in combination with inactivated vaccines against several avian diseases are widely used. In spite of some advantages of these oil adjuvants, local tissue reactions including granulomatous reactions are reported in some animals (6, 8, 9, 10, 11). The inactivated Newcastle disease vaccine is an example of mineral oil adjuvant application in birds in endemic areas. Newcastle disease virus (NDV) is an avian paramyxovirus that causes an economically important and highly contagious disease in poultry. In addition to the domestic avian species, natural or experimental infection with NDV has been demonstrated in other species of birds. Several previous studies have demonstrated that pigeons (*Columba livia*) and other members of the Columbidae family are susceptible to NDV. Ideally, vaccination against Newcastle disease would result in immunity against infection and replication of the virus (2), however as stated

before adverse reactions may occur in vaccinated animals. This study reports the occurrence of granulomatous reactions on pectoral muscles of a pigeon flock for the first time.

Materials and methods

On November 2012, five 2-year-old behbahanian breed of domestic pigeons with nodular lesions on pectoral muscle were presented to School of Veterinary Medicine, Shiraz University, Iran. On the basis of owner's declaration, the total number of birds in the aviary was 40 and most of them (30 pigeons) were involved. All of the affected birds were intramuscularly injected with 0.4 mL oil-emulsified (Montanide ISA-70) Newcastle disease vaccine in pectoral muscle about 5 months ago. All birds received the vaccine with an individual syringe and 18G hypodermic needle.

The formation of nodules was associated with the booster intramuscular vaccination. Birds were in relatively good condition, except for the presence of small to large nodules (about 5 mm to 20 mm in diameter) on the chest with pink to yellow in color. Clinical examination showed thickening and stiffness of subcutaneous tissues and muscles of the chest region (Fig. 1).

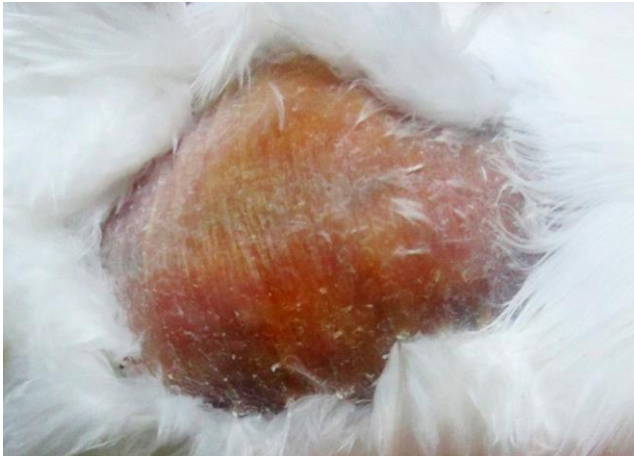

Figure 1. Granulomatous reactions on pectoral muscles of a pigeon.

Grossly, some of the nodules had connective tissue stiffness while others palpated with cystic consistency. White liquid material was drained from cystic nodules under lidocaine local anesthesia then both kinds of nodules were surgically removed and prepared for histopathologic examination by routine procedures. Five μm -thick sections were stained by hematoxylin and eosin (HE), modified Brown-Brenn Gram stains, Ziehl-Neelsen, and Periodic Acid Schiff (PAS) stain. Moreover, smears were prepared from drained liquid and stained with Giemsa, Ziehl-Neelsen and Gram's method for light microscopic examination. For bacteriologic examination, drained material was transferred to culture media including blood agar, eosine methylene blue and selenite broth.

Results

Smears from drained material showed no bacteria. In addition, tissues stained with Ziehl-Neelsen and Brown-Brenn Gram and PAS stains did not demonstrate bacteria or fungi associated with lesions. Microscopic examination of affected tissues revealed multifocal granulomatous dermatitis and myositis and abscess-like lesions on the site of vaccine application. Scattered granulomatous reactions as well as cystic structures with different diameters were observed (Fig. 2). Necrotic cell debris in the center of typical granulomas were peripherally surrounded by mononuclear inflammatory cells including lymphocytes, macrophages, plasma cells, numerous heterophils and giant cells with fibrous connective tissue (Fig. 3). Cysts with inflammatory reactions, scattered giant cells and fibrous

connective tissue were present between the granulomas (Fig. 4).

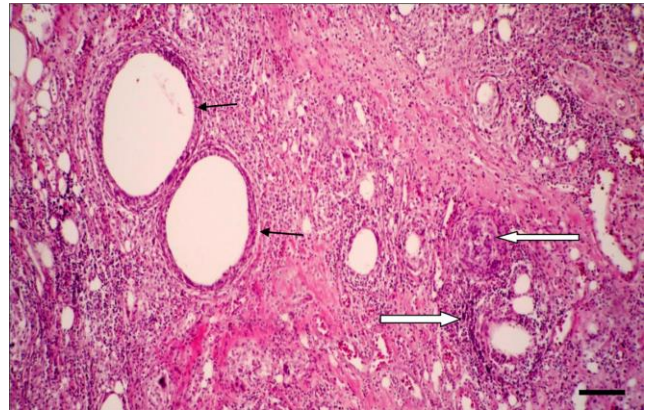


Figure 2. Cystic cavities (small arrows), scattered granulomatous reaction, and infiltration of mononuclear inflammatory cells (large arrows) between muscle fibers. HE, Bar = 100 μm .

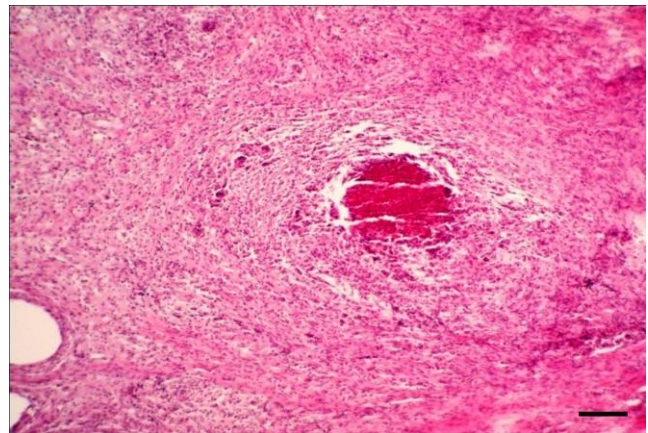


Figure 3. Typical granulomas at the site of injection. Necrotic debris in the center surrounded by giant cells, lymphocytes, macrophages, plasma cells and numerous heterophils and fibrous connective tissue. HE, Bar = 200 μm .

Discussion

Granulomatous reactions were previously reported in chickens following vaccination. Droual et al. (4) showed that oil-adjuvanted killed vaccines may produce long-lived residual lesions in chickens. The lesions typically were yellow opaque cysts along the fascial planes separating the superficial and deep pectoral muscles. Microscopic evaluation showed that most lesions were cysts with thin fibrous capsules, at times associated with lymphocytic aggregates and, more rarely, a granulomatous reaction (4). Khodakaram-Tafti and Dadras (6) observed local tissue reactions due to subcutaneous injection of killed ND vaccine in broiler breeder chickens. Granulomatous dermatitis and granulomatous myositis were diagnosed at the site of injection (6). Moreover, a

discrete swelling at the injection site of killed ND vaccine has been described in turkey, which regressed during a ten-week period. Histologically the swelling consisted of an inflammatory granulomatous reaction, with an accumulation of macrophages containing phagocytosed droplets of vaccine. Plasma cells were also present (1).

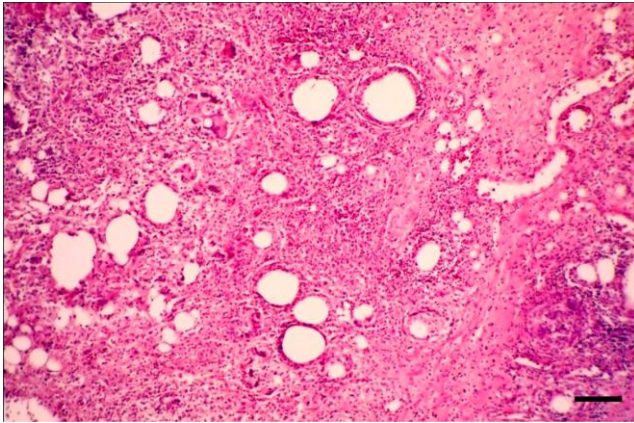


Figure 4. Cysts with inflammatory reactions. Scattered giant cells and fibrous connective tissue were seen between the granulomas. HE, Bar = 100 µm.

It has been shown that Freund's complete adjuvant (FCA) induces the most severe granulomatous lesions with abscess formation (10). Complications from the vaccination of pigeons with ND were previously reported (3). Adverse reactions to oil-based vaccines have also been reported in other avian species, including poultry (7, 10).

Fukanoki et al. (5) showed that among liquid forms of paraffin, lytol induces granulomatous reactions and abscesses (5). Yamanaka et al. (10) investigated pathological changes at the injection site of ISA-70 emulsion and other vaccines containing inactivated Newcastle disease virus antigen in guinea pigs and rats. Local thickening of subcutaneous tissue, discoloration of inter-muscular connective tissue and swelling of the inguinal lymph nodes were observed. Histopathologically, ISA-70 injected sites revealed acute inflammatory changes, macrophage accumulation around oil cysts accompanied with fibrosis and an infiltration of plasma cells and lymphocytes (9). In another study in chickens, gross and microscopic changes at the injection site of inactivated NDV vaccines contained ISA-70, some lesions such as proliferation of macrophages, epithelioid cells, and fibroblasts around the small cysts in the muscle as well as infiltration of lymphocytes and plasma cells were reported (10). Relatively same reaction are observed in pigs and cats (11).

In the present case, scattered granulomatous reactions were observed in pectoral muscles of a pigeon flock vaccinated with killed ND vaccine, containing ISA-70 mineral oil adjuvant. Cysts with inflammatory reactions, scattered giant cells and fibrous connective tissue were present between the granulomas. As discussed

above, these reactions may be due to the mineral oil-emulsion formulation of the vaccine.

Regarding the fact that the ability of flight in pigeons is very important, lesions in pectoral muscles, which have a considerable role in flying, may remarkably reduce bird's flying performance. The risk of killed oil-emulsion vaccines for inducing pectoral lesions recommends for caution. In conclusion, it may be prudent to consider the potential for induction an adverse reaction of vaccine formulations containing mineral oils as an adjuvant in pigeons.

Acknowledgments

The authors would like to thank Mr. Shirvani and Mr. Yousefi for their excellent technical assistance.

References

1. AITKEN ID., SURVASHE BD. Observations on the serological and dermal responses of turkeys to a single subcutaneous inoculation of inactivated Newcastle disease vaccine in mineral oil adjuvant. **Avian Pathol.**, 1974, 3, 211-222.
2. ALEXANDER D., SENNE D. Newcastle disease, other avian paramyxoviruses, and pneumovirus infections. SAIF YM., FADLY AM., GLISSON JR., MCDUGALD LR., NOLAN LK., SWAYNE DE. **Diseases of poultry**. 12 ed., Blackwell Publishing, Ames, 2008: 75-98.
3. COWAN ML., MONKS DJ., RAIDAL SR. Granuloma formation and suspected neuropathic pain in a domestic pigeon (*Columba livia*) secondary to an oil-based, inactivated Newcastle disease vaccine administered for protection against pigeon paramyxovirus-1. **Aust. Vet. J.**, 2014, 92, 171-176.
4. DROUAL R., BICKFORD AA., CHARLTON BR., KUNEY DR. Investigation of problems associated with intramuscular breast injection of oil-adjuvanted killed vaccines in chickens. **Avian Dis.**, 1990, 34, 473-478.
5. FUKANOKI S., MATSUMOTO K., MORI H., TAKEDA R. Effect of liquid paraffin on antibody responses and local adverse reactions of bivalent oil adjuvanted vaccines containing newcastle disease virus and infectious bronchitis virus. **J. Vet. Med. Sci.**, 2000, 62, 1317-1319.
6. KHODAKARAM-TAFTI AA., DADRAS HA. A pathological study on local tissue reactions induced after subcutaneous injection of oil Newcastle disease vaccine in broiler breeder chickens. **Iran. J. Vet. Res.**, 2001, 2, 164-168.
7. RITCHIE BW., NIAGRO FD., LATIMER KS, PRITCHARD N., GREENACRE C., CAMPAGNOLI RP., LUKERT PD. Antibody response and local reactions to adjuvanted avian polyomavirus vaccines

- in psittacine birds. **J. Assoc. Avian Vet.**, 1994, 8, 21-26.
8. WOODWARD KN., TOON LA. adverse reactions to vaccines. WOODWARD K. **Veterinary pharmacovigilance: adverse reactions to veterinary medicinal products**. Wiley-Blackwell, 2009: 453-473.
 9. YAMANAKA M., HIRAMATSU K., HIRAHARA T., OKABE T., NAKAI M., SASAKI N., GOTO N. Pathological studies on local tissue reactions in guinea pigs and rats caused by four different adjuvants. **J. Vet. Med. Sci.**, 1992, 54, 685-692.
 10. YAMANAKA M., OKABE T., NAKAI M., GOTO N. Local pathological reactions and immune response of chickens to ISA-70 and other adjuvants containing Newcastle disease virus antigen. **Avian Dis.**, 1993, 37, 459-466.
 11. YAMANAKA M., OKABE T., KODAMA K., GOTO N. Local pathological reactions induced in pigs and cats by adjuvant ISA-70 containing inactivated Newcastle disease virus antigen. **J. Vet. Med. Sci.**, 1994, 56, 185-187.