



Original full paper

Serological and histopathological survey of *Lawsonia intracellularis* infection in 30 argentinean swine herds

Mariana A. Machuca^{1*}, Javier A. Cappuccio¹, Pablo E. Piñeyro¹,
Maria C. Venturini², Maria A. Quiroga¹, Carlos J. Perfumo¹

¹Institute of Pathology, ²Laboratory of Immunoparasitology, Faculty of Veterinary Sciences, La Plata National University,.

Corresponding author: Mariana A. Machuca. Institute of Pathology. P. Box 296, B1900AVW, La Plata, Argentina. E-mail: mmachuca@fcv.unlp.edu.ar

Submitted July 7th 2008, Accepted November 10th 2008

Abstract

The objectives of this work were: 1) to investigate *L. intracellularis* antibodies in grower-finisher pigs from 30 herds by immunofluorescent antibody test (IFAT) 2) to evaluate the porcine proliferative enteropathy (PPE) lesions by histopathology, histochemistry (Warthin Starry) and immunohistochemistry (IHC) in ileum samples obtained at slaughterhouse from 10 selected herds, 9 seropositive and 1 control seronegative. At each farm, 30 grower-finisher pigs (18 to 20 weeks old pigs) were randomly selected for blood sampling. The sera were analyzed with a commercial IFAT kit (IleiTest, Elanco Animal Health). The overall percentage of positive pigs was 31.2% (281/900), whereas the percentage of positive farms was 76.7% (23/30). The within-herd mean percentage of positive sera ranged from 27.5 to 53.6%. Only 1 out of the 10 selected farms showed characteristic gross and histopathological lesions at slaughterhouse. On the other hand, 4 farms were positive by immunohistochemistry. In conclusion *L. intracellularis* infection is widespread among Argentinean farms even though the within-herd percentage was quite variable. Slaughter pigs without microscopic lesions showed immunoreactivity to *L. intracellularis*.

Key Words: *Lawsonia intracellularis*, porcine proliferative enteropathy, swine

Introduction

Porcine proliferative enteropathy (PPE), caused by *Lawsonia intracellularis*, is a widespread enteric infectious disease that affects weaned and growing-finishing pigs (19). Recent advances in diagnostic methods have allowed some estimates of the prevalence of the disease. Serological studies in USA and Europe have shown that the prevalence of PPE positive herds ranged from 60 to 100 % (19).

Antemortem methods available for diagnosis of PPE included polymerase chain reaction (PCR) in fecal samples and serological tests: indirect fluorescent antibody test (IFAT), immunoperoxidase monolayer assay (IPMA)

and ELISA (3, 9, 10, 18). Sera antibodies have been routinely detected using IFAT and IPMA test. Serum antibody response starts 2 weeks after infection-exposure lasted 3 to 13 weeks thereafter, depending on the clinical presentation and severity of PPE (12). However, as *L. intracellularis* is an obligate intracellular bacterium that infects epithelial intestinal cells, therefore, sera IgG does not seem to play a protective effect against infection, while secretory IgA and cell-mediated immune responses play a more significant role (7). Nevertheless, detection of IgG using IFAT is a useful tool in evaluating the exposure to *L. intracellularis* (7, 18).

Previous studies have shown that serological tests are more sensitive than PCR in faecal samples for

detecting experimentally infected pigs (10, 18). Besides, histochemistry, immunohistochemistry (IHC) and PCR are all sensitive diagnostic test to detect *L. Intracellularis* from clinical cases with gross lesions. On the other hand, only PCR and IHC are sensitive for detection of *L. Intracellularis* in suspected cases of PPE without gross or histopathological changes (14).

The aim of this study were to detect antibodies produced by *L. intracellularis* exposure-infection in grower-finisher pigs from confinement herds using IFAT and to evaluate the PPE lesions at slaughter by histopathology, histochemistry and IHC studies in ileum samples from selected herds.

Materials and methods

Localization and number of farms

A total of 30 farms (F1 to F30) were studied. These farms represent 9% of the total Argentinean farms. Among them, 13 were located in Buenos Aires province, 10 in Santa Fe, 5 in Cordoba, 1 in San Luis and 1 in La Rioja. These provinces represent an estimated 67% of the total pig inventory, 79.6% of the hog farms and 80.7% of the breed stock (13). A high percentage of the farms (83.3%) were management as an one site production system. The average number of sows per farm was 1,070 sows (range: 150 - 4,600).

Herd sampling procedure

On each farm, 30 blood samples were taken from grower-finisher pigs (18 to 20 weeks old pigs). Thirty samples per group were chosen as the number sufficient to detect a disease estimated as being of 10 or more per cent prevalence in any group of 1000 or more pigs, with a 95% of confidence level (6). Blood samples were obtained by venipuncture of the cranial vena cava. Serum was recovered by centrifugation and stored at -20°C until processed.

Serological examination

L. intracellularis antibodies were detected by a commercial IFAT kit (IleiTest, Elanco Animal Health). Briefly, sera samples were diluted 1:30 with phosphate buffered saline (PBS) pH 7.2 and incubated in glass slides coated with *L. intracellularis* antigen for 12 hours in a humid chamber at 4°C. After rinsing with PBS (4 washes for 10 minutes), rabbit anti-swine IgG fluorescein conjugate (Sigma Chemical Co, St. Louis, USA) diluted 1:100 was added and incubated for 30 min at 37°C in a humid chamber. The technique was validated by blind assay of 2 known negative sera and 2 known positive sera (clear fluorescence at 1/30 dilution). Glass slides were

examined with a Nikon Optiphot microscope (Nikon, USA) equipped for epifluorescence with halogen lamp.

The herd was classified as positive if one or more samples were IFAT positive (2). Overall percentage of positive sera, percentage of positive herds and within-herd percentage of positive sera (WHP) were calculated.

Pathological studies

A total of 2100 pigs from 10 farms, 9 seropositive (F1 to F9) and 1 seronegative (F10) were examined for gross lesions at slaughterhouse. From each farm, 50 ileum samples were taken for histopathology (HP) and 20 for IHC and Warthin Starry (WS) staining. Tissues were fixed in 10% buffered formalin and embedded in paraffin. Serial sections (3 µm) were routinely processed for HP and WS (1).

For IHC, tissue sections were deparaffinized and rehydrated by sequential immersions of the slides in xylene followed by graded concentrations of ethanol. Endogenous peroxidase activity was blocked by incubation in 3% H₂O₂ in PBS for 30 min at room temperature. Antigen retrieval was performed with proteinase K (Sigma Chemical Co. St Louis, USA P 2308) 1/200 in PBS for 15 min at 37°C. Then sections were washed 5 min in PBS. Non-specific bindings were saturated by 30 min incubation with 10% w/v powered milk for 30 min at room temperature. A polyclonal rabbit antibody (kindly provided by Dr. R.M.C Guedes) diluted at 1/6,000 with PBS, was used (11). It was applied for 1 hour at 37°C in a humid chamber. Then, tissues sections were washed in PBS-tween for 5 min, and incubated for 20 min at room temperature with labelled streptavidin-biotin link universal (LSAB2® System HRP K0673, DAKO Laboratories Co., California, USA). The slides were washed three times with PBS-tween before flooding and incubating with LSAB2 (LSAB2® System HRP K0673, DAKO Laboratories Co., California, USA) for 20 min at room temperature. The final reaction was produced by immersing the sections in a solution of diaminobenzidine (DAB) (LSAB2® System HRP K0673, DAKO Laboratories Co., California, USA) for 10 min at room temperature. The sections were washed and counterstained with haematoxylin. Positive and negative control sections were included.

Results

Serological studies

The total percentage of positive serum samples in growing-finishing pigs was 31.2% (281/900). The percentage of positive farms was 76.7% (23/30). The within-herd percentage of positive sera ranged from 7.1% to 80% (table 1).

Table 1 - Within herd percentage of positive sera in growing-finishing in 30 Argentinean pigs farms.

Prevalence	Frequency	Percentage	95% Confidence Interval
≤0	7	23.30%	9.90-42.30
>0 – 10	3	10.00%	2.10-26.50
>10 – 20	5	16.70%	5.60-34.70
>20 – 30	3	10.00%	2.10-26.50
>30 – 40	2	6.70%	0.80-22.10
>40 – 50	1	3.30%	0.10-17.20
>50 – 60	2	6.70%	0.80-22.10
>60 – 70	3	10.00%	2.10-26.50
>70 – 80	4	13.30%	3.80-30.70
Total	30	100.00%	

Pathological studies

Only 1 sample (2%), belong to F8, showed characteristic gross and microscopic lesions of regional ileitis (RI). However, both WS and IHC studies were negative. Furthermore, gross, histopathological and WS studies carried out in the remaining 9 farms were negative (table 2) (figure 1).

Four farms were positive for *L. intracellularis* by IHC. The proportion of positive samples varies between 10 to 60%. The results are showed in table 2.

Table 2 - Serological, macroscopical, histopathological, histochemical and immunohistochemical studies performed in 10 selected farms (expressed in percentage)

	Serology n=30	Macroscopic lesions n=210	Microscopic lesions n=50	WS n=20	IHC n=20
F1	17.8	0	0	0	0
F2	75	0	0	0	15
F3	55	0	0	0	60
F4	30	0	0	0	40
F5	44	0	0	0	0
F6	10.4	0	0	0	10
F7	46.4	0	0	0	0
F8	64.2	2*RI	2*RI	0	0
F9	80	0	0	0	0
F10 **	0	0	0	0	0

WS: Warthin Starry, IHC: immunohistochemistry, *RI: regional ileitis and **F10 negative control farm (IFAT).

Discussion

The results of this study showed that *L. intracellularis* infection-exposure is widespread among Argentinean farms. Twenty three out of the 30 farms analyzed (76.7%) were seropositive by IFAT. This percentage is in agreement to those reported in Canada (5), Denmark (21), Spain and France (4). The high percentage of seropositive herds could be related with the one site production system and continuous pig flow in grower-finisher facilities (4).

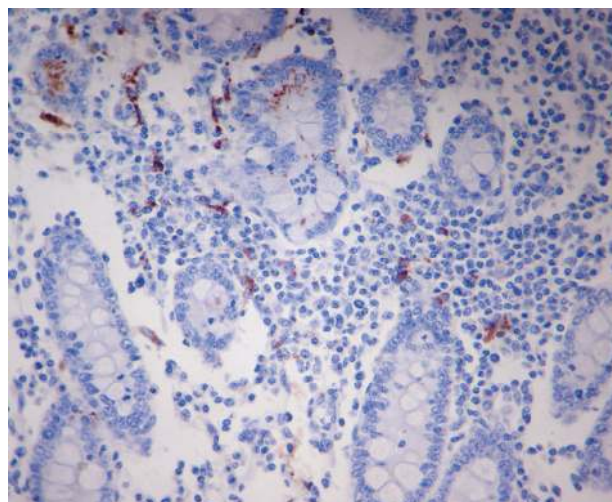


Figure 1 - *Lawsonia intracellularis* positive cells. Enterocytes of the few normal crypts and macrophages in lamina propria of infected pig. (IHC, LSAB. Obj. 40x).

Furthermore, the within-herd distribution of positive sera ranged from 0 to 20% in almost 50% of the farms evaluated. These low values are similar to those reported in previous studies (15, 17, 19, 20). Besides, 23.3% of the farms had more than 60% of positive samples. The wide range of seroprevalence among the farms may be due to different management systems and the use of antibiotics as a growth promoters or preventive to concomitant respiratory or enteric infections (4, 22).

Several reports have described gross lesions at slaughter age, however the prevalence reported varies from 0.7 to 2.0% (19). In this study only in 1 farm characteristic gross and microscopic lesions have been observed. However, WS and IHC studies of those cases were negative. These discrepancies could be due that RI is considered a chronic form of PPE or the end result of porcine intestinal adenomatosis (19, 20). In addition, in an experimental inoculation study, at 35 days post inoculation *L. Intracellularis* antigen was not detected by IHC (8). Moreover, the high percentage of seropositive pigs detected in several farms, were not related with WS or IHC results observed at slaughter. These results suggest that at slaughter time IFAT may be more appropriated diagnostic tool for identifying *L. intracellularis* exposure than pathological studies (15, 18).

The results of this study are similar with previous studies in which IHC was more sensitive than WS for the detection of *L. intracellularis* in both, epithelial cells and macrophages (14). In this study, IHC detected *L. intracellularis* antigen in a few enterocytes or macrophages without microscopic lesions. Experimental studies have showed that gross and microscopic lesions began to resolve after 28 days of inoculation (8). In these cases an IHC positive result may indicate previous infection. Moreover, pigs without gross and microscopic lesions in ileum but IHC positive could be considered as an infected pig. Those pigs could maintain the infection on

the farm acting as a reservoirs and intermittent shedders of *L. intracellularis* (16).

It was concluded that *L. intracellularis* infection is widespread among Argentinean farms even though the within-herd percentage was quite variable. Moreover a low percentage of slaughter pigs without gross and microscopical lesions harbored the bacteria in ileal enterocytes and macrophages.

References

1. ARRINGTON JB. Bacterias, hongos y otros microorganismos. In: Prophet EB, Mills B, Arrington JB, Sobin LH, Métodos histotecnológicos. Registro de Patología de los Estados Unidos de América. Washington, USA, 1995, pp. 220-221.
2. BRONSVOORT M., NORBY B., BANE DP., GARDNER A. Management factors associated with seropositivity to *Lawsonia intracellularis*. J. Swine Health Prod. 2001, 9, 285-290.
3. BOESEN HT, JENSEN TK, Moller K, NIELSEN LH, JUNGENSEN G. Evaluation of a novel enzyme – linked immunoabsorbent assay for serological diagnosis of porcine proliferative enteropathy. Vet. Microbiol. 2005, 1, 105-112.
4. CHOUET S., PRIETO C., MIELI L., VEENHUIZEN MF., MCORIST S. Patterns of exposure to *Lawsonia intracellularis* infection on European pig farms. Vet. Rec. 2003, 152, 14-17.
5. CORZO CA., FRIENDSHIP R., DEWEY C., BLACKWELL T. Porcine proliferative enteropathy in high health herds. The Pig Journal, 2004, 54, 9-16.
6. GARDNER IA., BLANCHARD PB. Interpretation of laboratory results. In: Straw BE., D'allaire S., Mengeling WL., Taylor DJ. (Eds.) Diseases of Swine. 8th ed. Iowa State University Press, Ames, Iowa, USA, 1999, pp. 19-39
7. GEBHART CJ., GUEDES RM. Proliferative enteropathy: diagnostic and immunity. Proceeding of American Association of Swine Veterinarians (AASV), 2001, 353-357.
8. GEBHART CJ. *Lawsonia intracellularis* infections. Oral presentations. In: Proceedings de 19th IPVS Congress, Copenhagen, Denmark, 2006; 1: 48-53.
9. GUEDES RM, GEBHART CJ, WINKELMAN NL, MACKIE-NUSS RA. A comparative study of an indirect fluorescent antibody test and an immunoperoxidase monolayer assay for the diagnosis of proliferative enteropathy. J. Vet. Diagn. Invest., 2002, 14, 420-423.
10. GUEDES RM., GEBHART CJ, DEEN J, WINKELMAN NL. Validation of an immunoperoxidase monolayer assay as a serologic test for porcine proliferative enteropathy. J. Vet. Diagn. Invest., 2002, 14, 528-530.
11. GUEDES RM., GEBHART CJ. Preparation and characterization of polyclonal and monoclonal antibodies against *Lawsonia intracellularis*. J. Vet. Diagn. Invest., 2003, 15, 438-446.
12. GUEDES RC., GEBHART CJ., ARMBRUSTER GA., ROGGOW BD. Serologic follow-up of a repopulated swine herd after an outbreak of proliferative hemorrhagic enteropathy. Can. J. Vet. Res., 2002, 66, 258-263.
13. GITEP (Technological Exchange Group of Swine Enterprises). Statistical annual study. Swine Analysis. Available from <http://www.gitep.com.ar/2004.pdf>. Accessed December of 2005.
14. JENSEN TK., MØLLER TD., LESER SE., JORSAL SE. Comparison of histology, immunohistochemistry and polymerase reaction for detection of *Lawsonia intracellularis* in natural porcine proliferative enteropathy. Europ. J. Vet. Path., 1997, 3: 115-123.
15. JENSEN TK., MOLLER K., CHRISTENSEN G., LESER TD., JORSAL SE. Monitoring ileitis and *Lawsonia intracellularis* in abattoir pigs. Vet. Rec., 1999, 145: 613-615.
16. JENSEN TK, VIGRE H, SORENSEN V, MOLLER K. Naturally acquired *Lawsonia intracellularis* infection in pigs studies from weaning to slaughter by indirect immunofluorescence antibody test and polymerase chain reaction on faeces. Res. Vet. Sci. 2005, 79, 93-98.
17. JUST SD., THOEN CO., THACKER BJ., THOMPSON JU. Monitoring of *Lawsonia intracellularis* by indirect serum immunofluorescence assay in a commercial swine production system. J. Swine Health Prod. 2001, 9, 57-61.
18. KNITTEL JP, JORDAN DM., SCHWARTZ KJ., JANKE BH., ROOF MB., MCORIST S., HARRIS L. Evaluation of antemortem polymerase chain reaction and serologic methods for detection of *Lawsonia intracellularis*-exposed pigs. Am. J. Vet. Res. 1998, 59, 722-726.
19. MCORIST S., GEBHART CJ. Proliferative enteropathies. In: Straw, B.E., Zimmerman JJ., D'allaire S., Taylor DJ. (Eds.), Diseases of Swine. 9th ed. Blackwell Publishing Professional, Ames, Iowa, USA, 2006, pp. 727-737.
20. MCORIST S., HARDGE T., GEBHART C, OHLINGER V., POHLENZ J., KELLER C, VOETS H., WALTER D. Porcine proliferative enteropathy – Ileitis. Technical Manual 3.0. Ed. Boehringer Ingelheim Animal Health GmbH, Rhein, Alemania 2006, pp. 49-69.
21. VESTERGAARD K., STEGE H., BÆKBO P., JENSEN TK, JORSAL SE, MØLLER K. Infection dynamics of *Lawsonia intracellularis* in Danish pig herds. En Proceedings 18th IPVS Congress, Hamburg, Germany, 2004;1: 292
22. WENDT M., SCHULZE-JOHANN R. Cross sectional study on *Lawsonia intracellularis* infections in German farrow-to-finish herds. In: Proceedings de 18th IPVS Congress, Hamburg, Germany, 2004; 1: 267.