BJVP
Brazilian Journal of Veterinary Pathology
ISSN 1983-0246

Case Report

Dysgerminoma and granulosa cell tumor in a bitch

Ayisa R. Oliveira[1*], Mayra C. Flecher[1], Flávia F. Jabour[1], Tayse D. Souza[1], Isabela Hardt[1], Fernanda T. Vieira[1], Alice C. Rassele[2], Gabriel C. Vicente[2], Flávia M. Machado[2]

[1]Laboratory of Animal Pathology, Universidade Vila Velha.
[2]Veterinary Hospital Prof. Ricardo Alexandre Hippler, Universidade Vila Velha.
[*] **Corresponding Author**: Universidade Vila Velha, campus Nossa Senhora da Penha. Rua Mercúrio, s/n, Boa Vista, Vila Velha, ES, 29102-623, Brasil.
E-mail: ayisa.rodrigues@gmail.com.

Submitted December 16th 2015, Accepted March 03rd 2016

Abstract

Dysgerminoma and granulosa cell tumor are neoplasms of the ovary of domestic animals, originating from germ cells and sex-cords cells, respectively. These neoplasms generally occur unilaterally, and usually as a single neoplasm. This report describes a case of a dysgerminoma in the right ovary and a granulosa cell tumor in the left ovary in a six years old bitch. An Akita and Siberian Husky crossbred bitch was admitted at the Veterinary Hospital (Universidade Vila Velha), with a history of purulent vaginal discharge, irregular estrous cycle, fatigue, polydipsia and polyuria. Ultrasound exam demonstrated bilateral ovarian neoplasms, and the animal was subjected to ovariohysterectomy. Macroscopic and microscopic features found in right and left ovaries were typical of dysgerminoma and granulosa cells tumor Sertoli-like, respectively. The uterus had cystic endometrial hyperplasia associated with mild metritis. Ovarian neoplasms occurring bilaterally are uncommon especially with different cell origins and distinct histopathological patterns in each ovary as described in this report.

Key words: ovary, ovarian neoplasm, female reproduction, metritis, hyperestrogenism.

Introduction

Ovarian tumors are classified as epithelial, mesenchymal, germ cell tumors and sex-cords tumors (4, 9, 10, 15). The dysgerminoma is an uncommon germ cell tumor in domestic animals, being more often reported in bitches and queens. It has malignant potential, particularly in older animals and occasionally can result in hyperestrogenism (5, 10, 15). Usually it is a solid, white, friable, and lobulated mass with areas of hemorrhage and necrosis (5), ranging from 2-30 cm in diameter (3).

The granulosa cell tumor is the most common ovarian neoplasm among domestic animals, especially in the case of large animals (5, 15), and has its origin in sex-cords cells. In dogs the incidence is high, especially in intact older bitches (6). It is usually unilateral, reaching up to 20-30 cm in diameter. They are mostly benign (5, 16), and they can produce steroids, primarily estrogen and testosterone, interfering with the reproductive function of the affected animals (15, 7). This report describes a case of dysgerminoma and granulosa cell tumor in the right and left ovaries, respectively, in a six years old bitch admitted at the Veterinary Hospital of the Universidade Vila Velha (H. Vet. - UVV).

Case report

A six-year-old Akita and Siberian Husky crossbred bitch, 16 kg of body weight, was admitted at the H. Vet. - UVV with a history of purulent vaginal discharge for one month and a half, irregular estrous cycle, fatigue, polydipsia, polyuria, and no history of contraceptive drugs administration. During the past week before admission, the animal had become lethargic, with soft feces, and occasional vomiting. At physical examination, the abdomen was rigid; the vulva was swollen with purulent

discharge and bilateral alopecia on the flank, perivulvar region, abdomen and neck. In the ultrasound examination, uterine horns presented hyperechoic with hyperplastic endometrium, and no intraluminal secretion. The left ovary had an anechoic structure measuring 2.3 cm in diameter with echogenic points. The right ovary had a heterogeneous mass, hyperechoic, measuring 4 cm in diameter, with irregular small cystic areas. Bilateral ovarian neoplasm was suspected, and the animal was submitted to an ovariohysterectomy (OSH).

The ovaries and the uterus were fixed in 10% buffered formalin, and submitted to the UVV Laboratory of Animal Pathology. Macroscopic features were described. Tissue samples were collected, processed for routine paraffin embedding, and hematoxylin and eosin (HE) staining of 4 µm thick tissue sections.

Macroscopically, the right ovary was oval with 4.8 x 3.5 cm, dark red slightly purplish and soft; the cut surface was irregular, with small cysts ranging from 0.2 to 0.5 cm in diameter and multiple regions with brown and friable material (necrotic foci). The left ovary had 3.2 x 2.0 cm, whitish, soft with small reddish areas randomly distributed on the cut surface. The uterine horns and body had an irregular and cystic mucosa with brownish viscous content in the lumen.

Microscopically, both the right and left ovary had proliferation of neoplastic cells, but with different histological features. The right ovary had a great quantity of large and polyhedral cells arranged in nests and trabeculae separated by a thin connective tissue. Such cells exhibited an eosinophilic cytoplasm, high nucleus:cytoplasm ratio, associated to a central large nucleus, sometimes multiples, with marked anisokaryosis and moderate pleomorphism; granular chromatin and one or more prominent nucleolus. There were 10 mitotic figures per high power field, with moderate amount of atypical mitosis (Fig. 1). Also were extensive multifocal areas of hemorrhage and moderate multifocal, predominantly perivascular, lymphoplasmacytic inflammatory infiltration.

In the left ovary, there were a marked proliferation of round elongated cells arranged in large nests and trabeculae separated by a connective tissue, sometimes with palisading arrangement. The cells were predominantly fusiform resembling Sertoli cells; with a large, round to oval, and moderately pleomorphic nucleus. There were moderate anisokaryosis; granular chromatin, and prominent central nucleolus, with two mitotic figures per high power field (Fig. 2). In addition, rare Call-Exner bodies and multifocal areas of hemorrhage with mild diffuse lymphocytic infiltration were observed. The uterus had moderately hyperplastic endometrium with intraluminal projections. Endometrial glands were dilated (cystic) and there were multifocal areas of hemorrhage and mild to moderate multifocal neutrophilic infiltration, predominantly in the glandular lumen.

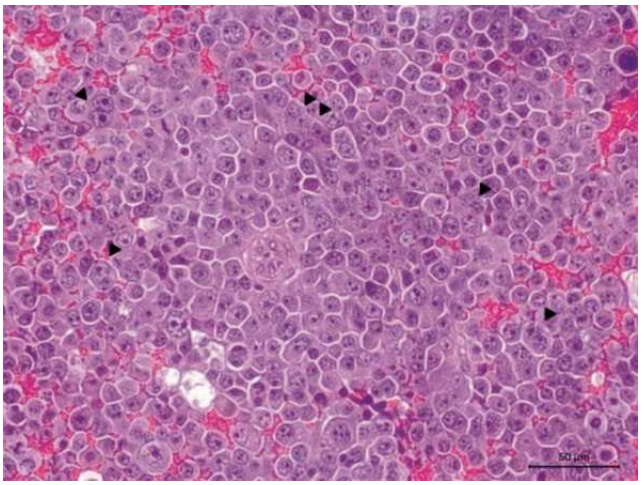

Figure 1. Right ovary. Dysgerminoma. Polyhedral cells with high nucleus:cytoplasm ratio, eosinophilic cytoplasm, a central large nucleus, with granular chromatin, and one or more prominent nucleolus. Marked anisokaryosis, moderate amount of atypical mitosis and numerous cells with two or more nuclei (black arrowheads) can be observed. There were also extensive multifocal areas of hemorrhage. HE, 400x.

Six months after the surgery another search for metastasis were performed, with radiographic examination of the thoracic cavity, and ultrasonography evaluation of the abdominal cavity, mesenteric lymph nodes, kidneys, liver, pancreas, spleen, and urinary bladder. No macrometastatic foci (larger than 0.3 cm) were found.

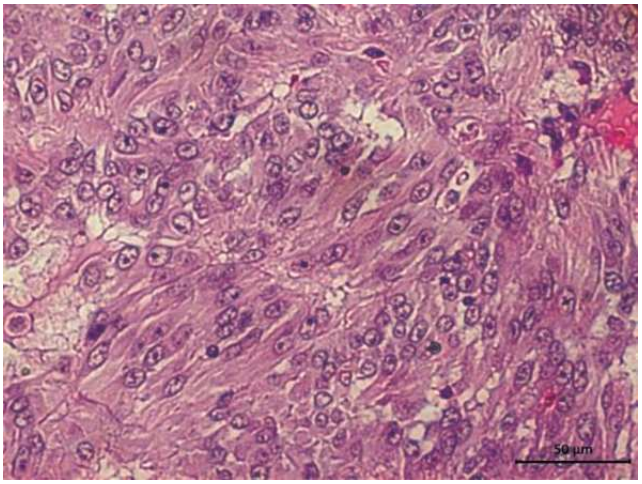

Figure 2. Left ovary. Neoplastic cell population compatible with granulosa cells tumor Sertoli-like. Marked proliferation of round to elongated cells arranged in palisade. Predominant fusiform aspect resembling Sertoli cells. HE, 400x.

Discussion

The microscopic features seen in the right and left ovaries were typical of dysgerminoma and granulosa cell

tumor Sertoli-like, respectively. Macroscopically, the dysgerminoma presented a dark red staining pattern, differing slightly from the whitish appearance described in the literature (3). Histologically, granulosa cells tumors, both in humans and in dogs, have a wide variety of growth patterns and can be microfollicular, macrofollicular, trabecular, diffuse, and Sertoli-like (2, 7, 16, 10, 13). In some cases, more than one pattern can be observed (2, 7). The granulosa cell tumor from the present study was morphologically characterized as Sertoli-like due to the predominance of spindle palisading cells arranged in cords in the histopathological sections. In these cases, the cells resemble the pattern of Sertoli cell tumor in testicles (10). The uterine body and horns had cystic endometrial hyperplasia associated with a discrete metritis.

Both granulosa cell tumor and dysgerminoma may lead to hyperestrogenism (5, 8, 10, 15) so they can induce cystic endometrial hyperplasia and metritis as observed in this case. Importantly, cutaneous changes that were observed prior to surgery resolved after OSH.

Polyuria and polydipsia presented by the dog in this case have also been reported as clinical manifestations in another case report of dysgerminoma (17), as well as apathy, occasional vomiting, irregular estrous cycle and purulent vulvar discharge (1, 11, 14, 16). The latter is also often described in animals with granulosa cell tumors (9). Although 10-20% of canine dysgerminomas are considered malignant (9), with eventual metastases reports (9, 11), no metastases were observed in the bitch of the present case, but the number of mitotic figures and atypia observed are indicative of malignancy.

The bitch in this report presented younger than the age group of 10-14 years, described in literature as the most common for the diagnosis of sex-cords tumors, even though, literature cited six years old as the average for the development of dysgerminomas (12, 16). It is uncommon for ovarian neoplasms to occur bilaterally (14, 16) specially with different cell origins and distinct histopathological patterns in each ovary, as is the case in the present report.

References

1. ANTONOV A., FASULKOV I., SIMEONOV R. A. Clinical case of unilateral ovarian dysgerminoma and pyometra in a bitch. **Mac. Vet. Rev.**, 2014, 37, 2, 179-183.
2. BANCO B., ANTUOFERMO E., BORZACCHIELLO G., COSSU-ROCCA P., GRIECO V. Canine ovarian tumors: an immunohistochemical study with HBME-1 antibody. **J. Vet. Diagn. Invest.**, 2011, 23, 5, 977-981.
3. DEHNER LP., NORRIS HJ., GARNER FM., TAYLOR HB. Comparative pathology of ovarian neoplasms. III. Germ cell tumours of canine, bovine, feline, rodent and human species. **J. Comp. Pathol.**, 1970, 80, 299-306.
4. ETTINGER SJ., FELDMAN EC. **Textbook of Veterinary Internal Medicine**. 6 ed., Mosby Elsevier, 2005.
5. FOSTER RA. Sistema reprodutor da fêmea e glândula mamária. ZACHARY JF., MCGAVIN MD. **Bases da Patologia Veterinária**. 5 ed.; Elsevier, 2013: 1088-1129.
6. JOHNSTON SD., KUSTRITZ MVR., OLSON PNS. Disorders of the canine ovary. JOHNSTON SD., KUSTRITZ, MVR., OLSON PNS. **Canine and feline theriogenology**. W.B. Saunders, 2001: 193-205.
7. KENNEDY PC., CULLEN JM., EDWARDS JF., GOLDSCHMIDT MH., LARSEN S., MUNSON L., NIELSEN S. **Histological classification of tumors of the genital system of domestic animals**. World Health Organization, Washington DC, 1998.
8. MACLACHLAN NJ. Ovarian disorders in domestic animals. **Environ. Health Perspect.**, 1987, 73, 27-33.
9. MEUTEN DJ. Tumors of genital systems. MEUTEN DJ. **Tumors in domestic animals**. 4 ed. Blackwell, 2002: 547-574.
10. NOVOTNY R., VITASEK R., BARTOSKOVA A. Ovarian dysgerminoma with retroperitoneal metastases in a bitch: a case report. **Vet. Med.**, 2011, 56, 3, 140-144.
11. PATNAIK AK., GREENLEE PG. Canine ovarian neoplasms: a clinicopathologic study of 71 cases including histology of 12 granulosa cell tumors. **Vet. Pathol.**, 1987, 24, 509-514.
12. RICCARDI E., GRIECO V., VERGANTI S., FINAZZI M. Immunohistochemical diagnosis of a canine ovarian epitelial and granulosa cell tumors. **J. Vet. Diagn. Invest.**, 2007, 19, 431-435.
13. ROLIM VM., PINTO TM., LOPES LMA., SONNE L., OLIVEIRA EC., ALMEIDA PR., BECK CAC., DRIEMEIER D. Disgerminoma bilateral e hiperplasia endometrial cística com piometra em cadela. **Acta Sci. Vet.,** 2010, 38, 3, 337-340.
14. SANTOS RL., NASCIMENTO EF., EDWARDS JF. Sistema reprodutivo feminino. SANTOS RL, ALESSI AC. **Patologia Veterinária**. Roca, São Paulo, 2011: 797-854.
15. SCULLY RE. Granulosa cell tumors. **Histological typing of ovarian tumors**. World Health Organization, Berlin, 1999: 20-21.
16. SFORNA M., BRACHELENTE C., LEPRI E., MECHELLI L. Canine ovarian tumors: A retrospective study of 49 cases. **Vet. Res. Commun.**, 2003, 27, 1, 359-361.
17. TAMIASSO NV., ASSIS HA., ANDRADE JUNIOR PSC., NUNES LC., BOELONI JN. Disgerminoma ovariano em cadela. **III Congresso Brasileiro de Patologia Veterinária. Enapave 2015**. 2015. Anais Resumos. Access: http://enapave.com.br/site/arquivos/anais_resumos_enapave_2015.pdf.

 All rights reserved 2007.