BJVP
Brazilian Journal of Veterinary Pathology
ISSN 1983-0246

Original Full Paper

Frequency, pathology and electron microscopy of dromedary camel viral fibro-papilloma in Sudan

Ahmed K. Elfadl[1*], Kathrin Jäger[2], Heinz A. Schoon[3], Ahmed A. Gameel[4]

[1] Department of Pathology, College of Veterinary Medicine, Kyungpook National University, Daegu, Republic of Korea
[2] LABOKLIN GmbH, Steubenstraße 4, 97688 Bad Kissingen, Germany.
[3] Institute of Veterinary pathology, Faculty of Veterinary Medicine, University of Leipzig, Germany.
[4] Department of Pathology, Faculty of Veterinary Medicine, University of Khartoum, PO Box 32, Shambat, Khartoum North, Sudan
[*] **Corresponding author:** Kyungpook National University, Daegu, Republic of Korea.
E-mail: ahmedpath@hotmail.com

Submitted December 15th 2015, Accepted April 13th 2016

Abstract

Sixteen different herds comprising 1803 camels were surveyed between August 2009 and January 2012 for presence of Camel Papillomatosis. Outbreaks of the disease were observed in two different areas. The first outbreak occurred in Al-Qutaynah locality, about 83 Km south of Khartoum and the second in Al-Fashagah locality about 410 Km south east of Khartoum. Fifty three camels were found to be affected with papillomatosis, with a total morbidity rate of 2.9%. All affected animals were 3-24 months old in addition to 2 females aged four and five years old. Cases of Camel Papillomatosis were recorded in January, July, August and October. The skin lesions were dark grey or white keratinized fissured raised masses, some of which were pedunculated. They showed various shapes: round, oval, cauliflower, horn shape, flat or dome shape and measured on average about 8.8 X 7.5 X 7.1 mm. Warts occurred mostly in head and face but other sites (limbs, ventral abdomen, sternum and tail) were also involved. Twenty Five cases were analyzed histopathologically, in which sections were typical for fibropapilloma characterized by multiple papillary proliferations covered with keratinized epithelium, with down growth of rete ridges. Acanthosis with karyopyknosis and cytoplasmic vacuolations in stratum spinosum cells and hyperkeratosis were seen together with subepithelial fibrosis. No inclusions could be detected in squamous cells. Out of 19 samples investigated immunohistochemically for papillomavirus antigens, 10 samples were found positive. Using transmission electron microscopy, aggregates of papillomavirus virions were found in the nuclei of the stratum granulosum in one sample.

Key words: camels, epidemiology, pathology, electron microscopy, viral fibro-papilloma.

Introduction

The family Papillomaviridae is composed of circular dsDNA viruses that are widespread among vertebrates. These viruses are known to infect the epithelial tissues of reptiles, birds and mammals, and almost all papillomaviruses are strictly specific to their natural host and do not infect even closely related species (2, 4). The complete genome of two *Camelus dromedarius* papilloma viruses have been described and located within the genus delta-papillomavirus for the first time in Sudan by (18). Both of genomes were taken from fipropapillomas according to the histopathological examination. Cases were recorded in August which is the rainy season in Sudan. Papillomas recorded in young animals aged < 8months with a total morbidity of 44%. Lesions were either oval, round or cauliflower distributed in lips and lower jaw. According to the fact that a few information were recorded regarding the epidemiology, pathology of camel papillomatosis, this publication was created with the aim of evaluation of various types of camel warts grossly, histologically, immuno-histochemically and detection of

 All rights reserved 2007.

the virus particles by Transmission Electron Microscopy (TEM). Leukemia (CEL) in an African pygmy hedgehog, which showed neoplastic proliferation of eosinophils infiltrating different tissues and in peripheral blood. In the absence of a known cause for reactive eosinophilia, CEL and hypereosinophilic syndrome were the main differential diagnosis (9, 13).

Material and methods

Collection of epidemiological data

Continuous visits to camel markets and herds were performed between August 2009 and January 2011, to obtain biopsies from Camels showing skin papillomas, as well as establishing brief data on epidemiology of the disease. During visits, epidemiology of the disease was recorded including, age of animals, sex, breed, morbidity rates as well as season. Also, number, shape, size and sites of warts on body were determined. Climate parameters temperature, humidity and rainfall were also recorded.

Sample collection

Animals were restrained, age estimated and the skin was carefully inspected for abnormal lesions. Animals with skin papillomas were identified, and the lesions were described and photographed. Whole biopsies from affected animals were excised surgically (using 2% lignocaine as a local anesthetic) and fixed in 10% neutral buffered formalin. This study has been ethically approved by the Sudan Veterinary Council.

Histopathology

Twenty Five of samples for histopathology were trimmed, serially dehydrated, paraffin embedded, sectioned at 5 mm and stained with haematoxylin and eosin and Masson's Trichrome.

Immunohistochemistry

Camel papillomavirus major capsid protein (L1) was demonstrated in paraffin embedded wart sections, using a mono clonal antibodies [BPV-1/1H8 + CAMVIR] and peroxidase anti peroxidase method (PAP). Sections were deparaffinized, rehydrated and endogenous peroxidase was inactivated by incubation in H_2O_2 0.5% for 30 min. The slides were incubated in Citrate buffer at 96°C for 25 min for antigen unmasking. Mouse monoclonal antibodies [BPV-1/1H8 + CAMVIR] against HPV were used as primary antibodies (Abcam plc, 330 Cambridge Science Park, Cambridge, CB4 0FLm, UK). The secondary antibody was applied (rat-anti mouse) and after an incubation time of 30 min, horseradish-peroxidase-antiperoxidase-complex from the mouse was added. The slides were stained with diaminobenzidine and finally counterstained with Papanicolaou.

Electron microscopy

Epon embedding method was used. The samples were cut in pieces with a feed size of 2 mm, fixed in 3% glutaraldehyde and embedded in Epon 812. In semi thin slides, the region of interest was determined by means of Toluidin blue staining. Afterwards, ultra-thin slides were cut with a diamond blade and mounted on impregnated and sputtered grids. Double contrasting of the slides was done with uranyl acetate and plumb citrate (according to Reynolds), and the grids examined using Electron microscope (EM 900, Zeiss, Oberkochen, Germany) in magnifications from 400x – 80,000x

Results

Epidemiology of camel papillomatosis

Out of 1,803 animals surveyed in 16 different herds, 53 (2.9%) camels were found to have warts, 22 of them were females (41.5%), 15 (28.3%) were males and in 16 sexes were not determined (30.2%). Papillomatosis was seen in camel calves of different ages, from three months to two years. However, 2 female camels aged four and five years had recorded papillomas (Table 1). All camel types which showed warts were Arabic and Daeely (Rashaidy) camels with an equal frequency. Forty cases were recorded in January and 13 cases were observed in July, August and October, which are rainy months in most parts of Sudan.

Gross pathology

The skin lesions were dark grey or white keratinized fissured masses, some of which were pedunculated. They showed various shapes: round, oval, cauliflower, horn shape, flat or dome shape and measured on average about 8.8 x 7.5 x 7.1 mm. Total number of warts were 74 which distributed in face and head in 51 animals. However, two animals showed multiple uncountable warts in limbs, ventral side of abdomen, tail, and between forelimbs in the sternum (Table 2; Fig. 1 and 2).

Histopathology

As warts are getting hard in long term formalin fixation only 25 cases could be analyzed. Sections showed multiple papillary proliferations covered with keratinized epithelium, with down growth of rete ridges (Fig. 3A). Slight to moderate, severe to extensive hyperkeratosis and slight to moderate, severe to extensive parakeratosis were also seen (Table 3). Stratum granulosum was hyperplastic (hypergranulosis) and eosinophilic to dark blue, variably

Table 1. Total number of camels in herds, number of affected camels, age and sex of affected animals with percentages.

Herd No.	Total No. of camels	No. of affected	Morbidity	Age	Sex
A	145	2	4.4%	1.5/ 2 years	Female, male
B	38	2	5.3%	2 years/ Not determined	Female, male
C	200	2	1%	1 year/ Not determined	Female/ Not determined
D	40	1	2.5%	1year	Female
E	40	3	7.5%	1 year (2)/ 2years	Female (3)
F	200	3	1.5%	5/11/8 months	Male, female, Not determined
G	200	2	1%	3/ 6months	Female (2)
H	120	5	4.2%	1/1.5 year/ 2 years(3)	Female (4), male.
J	100	4	4%	1 year (2)/ 1.5 year/ 2 years	Male (2), female(2)
K	65	3	4.6%	1.5 year/ 2/ 4 years	Female (2), male
M	200	6	3%	6 months/ 1 year (3) 1.5 year (2)	Male (5), Not determined
N	60	3	5%	2.5 year/ 3/ 5 years	Female, male, Not determined
O	55	11	20%	7 months/ 9 months/ Not determined (9)	Not determined (11)
P	150	4	2.7%	1 year (4)	Female (3), male
Q	130	1	0.8%	1 year	Male
R	60	1	1.7%	1 year	Not determined
Total	1803	53	2.9%	minimum:3months, maximum:60months, mean:17.17months Standard deviation: 11.04	22 females, 15 males, 16 Not determined

Table 2. Shows total No. of warts (74) recorded in 51 animals and their sites on head with percentages. Note, 2 animals with uncountable warts in abdomen and tail are not included.

Sites on Body	Upper right lip	Upper left lip	Lower lip	Upper jaw	Lower jaw	Nares	Lip commissure
No. of Warts	19	9	7	4	29	4	2
Percentage	25.67%	12.16%	9.45%	5.40%	39.18%	5.40%	2.70%

sized, round or irregular, giant keratinohyaline granules were seen in most of sections (Table 3; Fig. 3B).

In stratum spinosum, gradually varying acanthosis, koilocytosis and nuclear vacuolation were observed (Fig. 3C). Proliferation of stratum basale, irregularity of the layer and vacuolation of cells were prominent. Degenerative changes and a few mitotic figures were also noticed. Fibroplasia of the dermis was prominent resulting in obliterating of the adnexa (Fig. 4). A gradually varying interstitial infiltration of the dermis with mononuclear cells, chiefly lymphocytes, was seen (Fig. 3D). Three shapes of fibrous connective tissue were demonstrated by Masson's Trichrome; loose connective tissue, dense and dense fibrous tissue arranging in bundles (Fig. 4).

Immunohistochemistry

Long term fixation of warts in formalin resulted in hardening of tissues which made it difficult to be analyzed. Therefore only 19 samples were examined. Ten sections showed few to numerous epidermal cells with moderate to strong intranuclear reaction; nine samples were negative. Reaction was confined to stratum granulosum in most sections. Stratum spinosum showed positive reaction in 3 sections (Fig. 5).

Electron microscopy

Two samples that were positive for immunohistochemistry were submitted for Electron microscopy Examination after marking of the area in

sections that showing localization of antibodies. Aggregates of virions with icosahedral symmetry were found in the nuclei of the epithelial cells in stratum granulosum. Virions were naked and approximately 50-90 nm in diameter (Fig. 6).



Figure 1. *Camelus dromedarius*, a solitary round nodule in the lower lip (arrow).



Figure 2. *Camelus dromedarius*, multiple cauliflower–like warts on the hind limb (arrows).

Discussion

Papillomatosis in the dromedary camel seems to be less studied compared to other domestic animals. Papillomatosis received more attention in cattle, sheep, horses and dogs (3, 5, 11, 14, 19).

In the Sudan few reports are available on dromedary camel papillomatosis, despite the large camel population estimated at 4,406,000 (12); Khalafalla (10) reported in the epizootiology of the disease and Ure et al. (18) characterized the genome of two types (cdPV 1&2) of papilloma virus in Sudanese camels

In the present study, the morbidity rate of camel papillomatosis was found to be 2.9% with variations between herds. 20% morbidity was recorded in the only closed camel farm where confinement and close contact between animals predispose to injury and favor spread of the disease. The rest of the cases were reported in grazing camels. However, the average morbidity rate is comparable to that previously reported by Khalafalla (9) in Sudan. According to the survey, the higher frequency of Papillomatosis (40 cases) were recorded in January comparing to only 13 cases which were found during July, August and October. Camel herds in Sudan are in continuous movements and they are not settled down in one location. They move away from areas of heavy rains escaping from harmful insects and they come back again in dry season. Therefore, the survey team had only access to most of cases in January when Camel herds are available in Al-Fashagah locality where part of the survey was conducted. However, more investigations determining the prevalence of the disease during the year are required. The results indicate that young camels, 3-30 months old, are more susceptible to infection though older camels, as seen here, can also be infected. Corneal viral papillomatosis was reported in a 15 years old dromedary (10) and five cases of fibropapillomatosis have been described in two llamas and three alpacas, all six years old (17).

The gross lesions described here are not largely different from those reported by other authors (6, 9, 18). Most of warts were reported in face and mouth and this is probably due to scratches and injuries happen in these sites during grazing of camels on thorny trees which facilitates entering of the virus into skin. However, one case showed manifestation of warts in the lower part of body and legs; this is might be also due to possible exposure of the skin to erosions when animal rests down. However, other factors that could be responsible for presence of warts in lower parts of body should be further investigated.

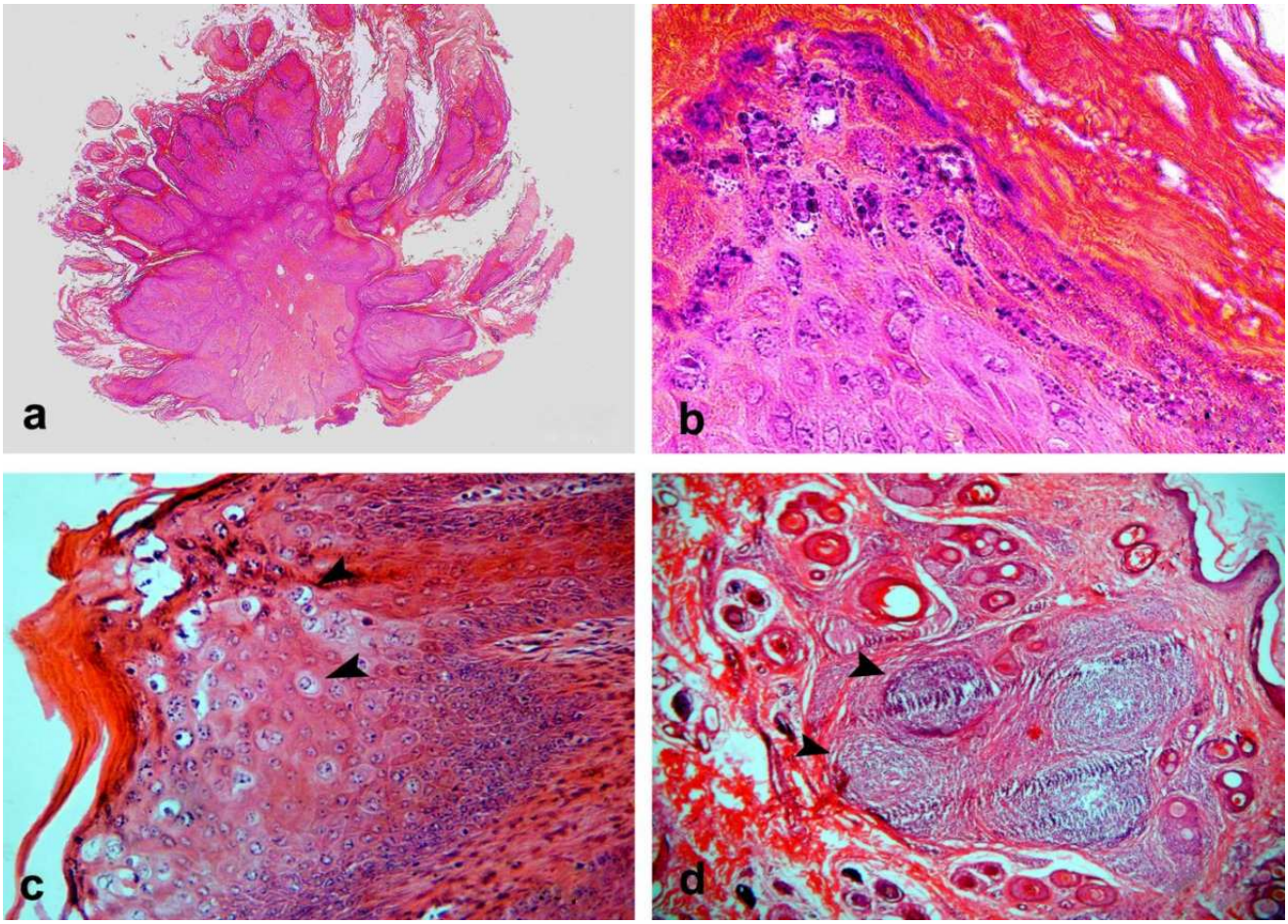

Figure 3. Skin; *Camelus dromedarius* (**a**) Overview of camel papilloma. Hematoxylin & Eosin (HE) (**b**) Hyperkeratosis (arrow) and giant keratinohyaline granules (arrow head). Hematoxylin & Eosin (H&E). (**c**) Some keratinocytes exhibited vacuolations in the cytoplasm (arrow head) which termed (Koilocytes). Hematoxylin & Eosin (HE). (**d**) Multifocal infiltration of mononuclear cells in the dermis. Hematoxylin & Eosin (HE).

Table 3. Histopathological changes of warts in 25 cases.

Histological changes	Number of samples
Wart shape	Frond (21/84%), Fungoid (4/16%)
Hyperkeratosis	Slight (4/16%), Moderate (9/36%), Severe (11/44%), Extensive (1/4%)
Parakeratosis	None: (9/36%) Slight (1/4%), Moderate (4/16%), Severe (5/20%), Extensive (6/24%)
Acanthosis	Slight (6/24%), Moderate (10/40%), Severe (9/36%)
Hypergranulosis	None: (2/8%) Slight (8/32%), Moderate (10/40%), Severe (5/20%)
Tumor stroma	Loose (9/36%), Dense (16/64%)
Inflammatory cells	No Infiltration (4/16%), Infiltration (21/84%)

Hyperkeratosis (Average of layers) = Slight: (6-14), Moderate: (15-24), Severe: (25-39), Extensive: (73). Parakeratosis (Average of Cells' Rows) None: 0 Slight: (6-14), Moderate: (15-24), Severe: (25-39), Extensive: (40-50). Acanthosis (Average of Cells' Rows) = Slight: (5-7), Moderate: (8-14), Severe: (15-31). Hypergranulosis (Average of Cells' Rows) = None: 0 Slight: (2-5), Moderate: (6-10), Severe: (11-20).

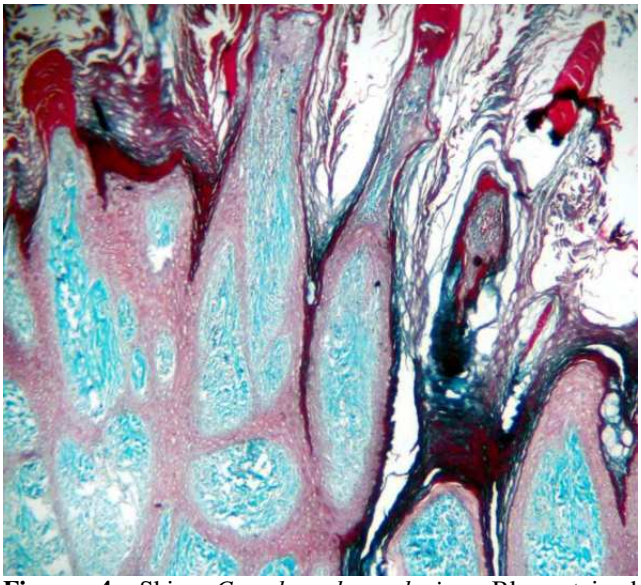

Figure 4. Skin; *Camelus dromedarius*, Blue stained collagen fibers in the dermis. Masson's Trichrome.

The microscopic features of the lesions are those of fibropapilloma (18, 17, 7, 8, 1). Orthokeratotic and parakeratotic hyperkeratosis, hypergranulosis and acanthosis were observed in all sections with proliferation of basal layer in some cases. Enlarged vacuolated acanthocytes were seen and cells resembling koilocytes were observed in the stratum granulosum, the latter may indicate viral infection. Inclusion bodies as those described by Killic et al. (10) have not been noticed. The dermis showed fibroplasia which was dense in some sections and loose in others. Mononuclear cells infiltration in dermis was a common feature. Mild lymphocytic dermal infiltration was reported in Bovine papillomatosis (16). However, presence of inflammatory cells may indicate good prognosis and spontaneous regression of the wart (15).

The immunohistochemistry investigation using mononuclear antibodies BPV-1/1H8 revealed moderate to strong intranuclear reaction in cells of the granular and spinosum layers.

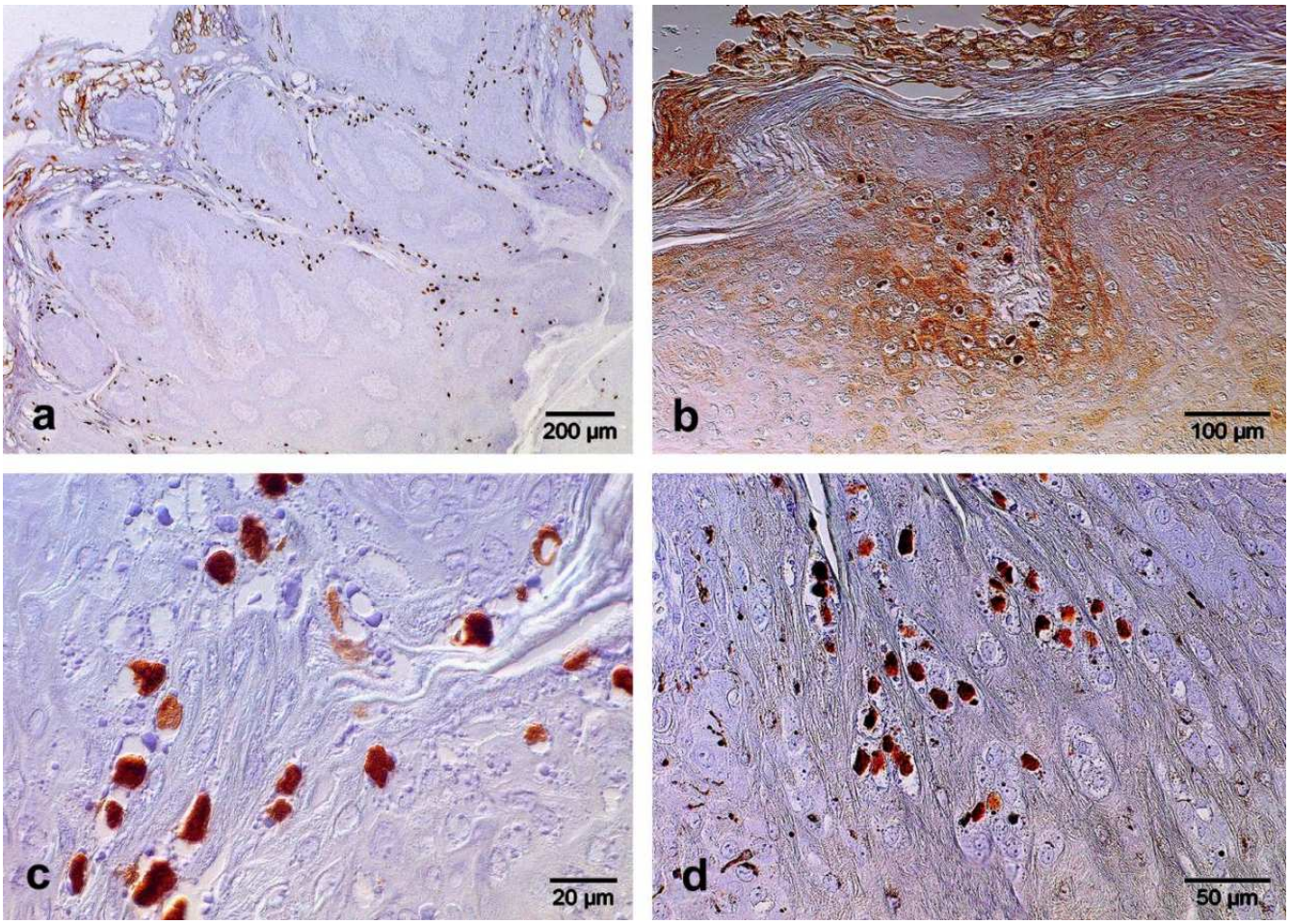

Figure 5. Skin; *Camelus dromedarius* (**a**) Immunohistochemical reaction of BPV-1 antibodies showing numerous positive cells in the stratum granulosum. (**b**) Few cells in stratum spinosum showing positive reaction with BPV-1 antibodies. (**c**) Moderate intranuclear reaction to BPV-1 antibodies. (**d**) Strong intranuclear reaction to BPV-1antibodies (PAP method).

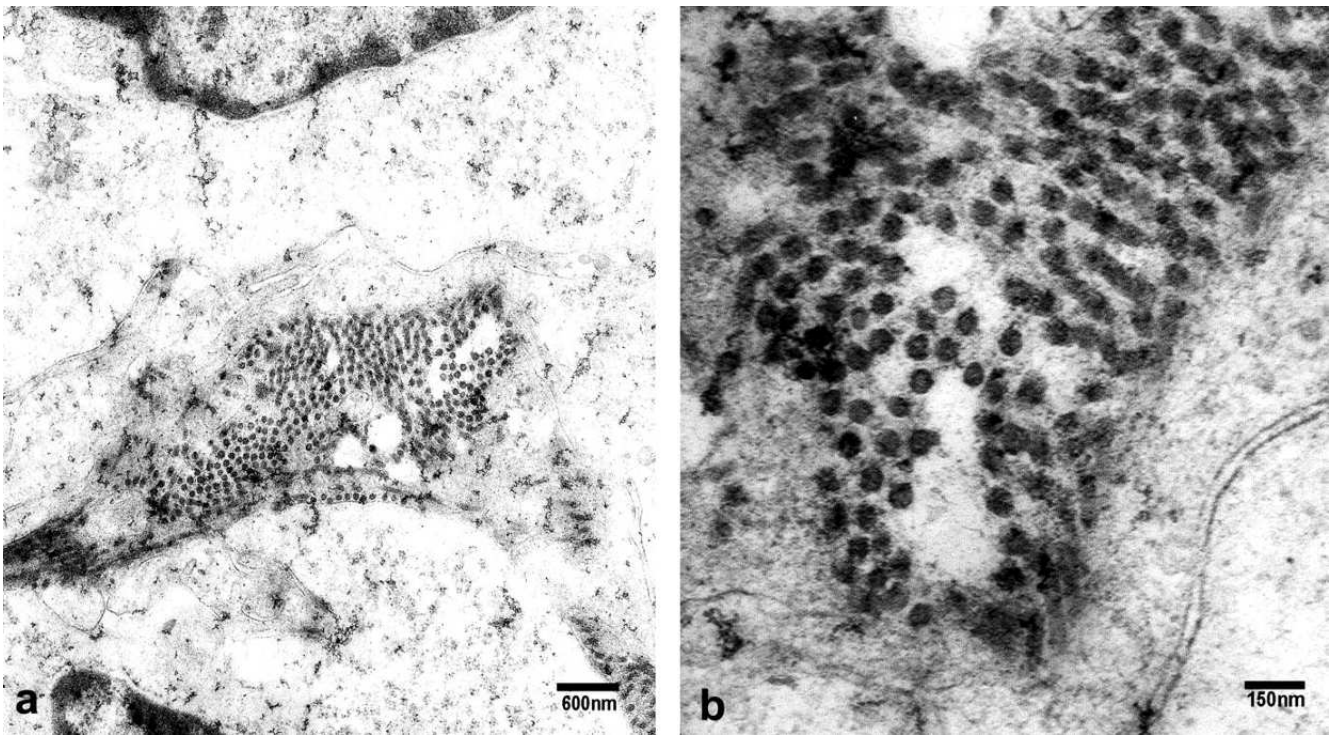

Figure 6. Skin; *Camelus dromedarius*. Aggregates of virus like particles inside a keratinocyte nucleus (**a**). Virions were naked and approximately 50-90 nm in diameter (**b**). Epon embedding method.

These mononuclear antibodies were basically used to detect human papillomavirus (HPV).

Using these antibodies PV antigens could be detected in corneal papilloma in a camel; positive reaction was seen in nuclei and cytoplasm of epithelial cells especially in basal and spinosum layers and in fibroblasts (10). This may suggest a close relationship between camel PV, BPV-1 and human papillomavirus, as also indicated in our previous study (18) reporting the characterization of camel papillomavirus genome.

In addition, intranuclear viral-like particles resembling those of papillomaviruses have been detected in epidermal cells by TEM, giving more support to the viral etiology of the cases herewith investigated. However, Camel Papilloma virus virions have been presented before in negative staining preparations from wart tissues (13).

In conclusion, Camel Papillomatosis affects mainly calves but adult animals can also catch the disease. Infection occurs due to close contact between animals, where virus finds his path into skin through erosions and injuries. Skin erosions occur when camels feed on thorny trees or when animal rest down exposing lower parts to erosions. Cases of Papillomatosis occur in rainy season as well as in January. Hyperkeratosis, acanthosis, hypergranulosis with proliferation of fibrous tissue in the dermis is the main histological picture of camel papillomatosis. Papilloma virus antigens were mainly detected in the stratum granulosum with few antigens in stratum spinosum. Camel Papilloma virus virions are naked and 50-90 nm in size.

Acknowledgements

We are so grateful to Dr. Ali Hassan, Mr. Abdo Bosharah (Al-showak camel research station) who made everything possible during our stay in Al-Fashagah Locality for sample collection. Also, we would like to thank Prof. Jeong Kyu Shik for making comments on the manuscript.

References

1. BARAKAT SEM., AL HIZAB FA., EL-BAHR SM. Clinicopathological investigation of naturally occurring serobiochemical cutaneous papillomatosis in dromedary camels (*Camelus dromedarius*) **Sci. Int.**, 2013, 1, 6, 212-216.
2. BERNARD HU., BURK RD., CHEN Z., DOORSLAER KV., HAUSEN HZ., DE VILLIERS EM. Classification of papillomaviruses (PVs) based on 189 PV types and proposal of taxonomic amendments. **Virology**, 2010, 401, 70-79.
3. CAMPO MS. Animal models of papillomavirus pathogenesis.**Virus Res.**, 2002, 89, 249-261.

4. CHOW LT., BROKER TR., STEINBERG BM. The natural history of human papillomavirus infections of the mucosal epithelia. **APMIS**, 2010,118, 422-449.
5. DE VILLIERS EM., FAUQUET C., BROKER TR., BERNARD HU., ZUR HAUSEN H. Classification of papillomaviruses. **Virology**, 2004, 324, 17-27.
6. DIOLI M., STIMMELMAYR R. Important camel diseases. Schwartz H., DIOLI M. The one humped camel in eastern Africa. A pictorial guide to disease, health care and management. Verlag M Joseph Margraf, Scientific Books; 1992: 155-164.
7. EBU ELZEIN ET., SUNDBERG JP., HOUSAWI FM., GAMEEL AA., RAMADAN RO., HASSANEIN MM. Genital bovine papillomavirus infection in Saudi Arabia. **J. Vet. Diagn. Invest.**, 1991, 3, 36-38.
8. GOLDSCHMIDT MH., DUNSTAN RW., STANNARD AA., VON TSCHARNER C., WALDER EJ., YAGER JA. **Histological classification of epithelial and melanocytic tumors of the skin of domestic animals**. Washington D.C: Armed Forces Institute of Pathology, 1998, 19.
9. KHALAFALLA AI. Epizootiology of Camel Pox, Camel Ecthyma and camel papillomatosis in the Sudan. **Proceedings of the Third Annual Meeting for Animal Production under Arid Conditions**. 1998, 2, 115-131.
10. KILIC N., TOPLU N., AYDOGAN A., YAYGINGUL R., OZSOY SY. Corneal papilloma associated with papillomavirus in a one-humped camel (*Camelus dromedarius*). **Vet. Ophthalmol.**, 2010,13, 1, 100-102.
11. LANCASTER WD., OLSON C. Animal papillomaviruses. **Microbiol. Rev.**, 1998, 46, 2, 191-207.
12. Ministry of Animal Resource, 2008. Dept. of statistic and information, Khartoum - Sudan.
13. MUNZ E., MOALLIN AS., MAHNEL H, REIMANN M. Camel papillomatosis in Somalia. **Zentralbl. Veterinarmed. B.**, 1990, 37, 3, 191-196.
14. NARAMA I., KOBAYASHI Y., YAMAGAMI T., OZAKI K., UEDA Y. Pigmented cutaneous Papillomatosis (Pigmented Epidermal Nevus) in Three Pug Dogs; Histopathology, Electron Microscopy and Analysis of Viral DNA by the Polymerase Chain Reaction. **J. Comp. Path.**, 2005, 132, 132-138.
15. NICHOLLS PK., MOORE PF., ANDERSON DM., MOORE, RA., PARRY NR., GOUGH GW., STANLEY MA. Regression of Canine Oral Papillomas Is Associated with Infiltration of CD41 and CD81 Lymphocytes. **Virology**, 2001, 283, 31-39.
16. ÖZSOY SY., ÖZYILDIZ Z., GÜZEL M. Clinical, pathological and immunohistochemical findings of bovine cutaneous papillomatosis. Ankara **Üniv. Vet. Fak. Derg.**, 2011, 58,161-165.
17. SCHULMAN FY., KRAFFT AE., JANCZEWSKI T., REUPERT R., JACKSON K., GARNER MM. Camelid mucocutaneous fibropapillomas: clinicopathologic findings and association with papillomavirus. **Vet. Pathol.**, 2003, 40, 103-107.
18. URE AE., ELFADL AK., KHALAFALLA AI., GAMEEL AA., DILLNER J., FORSLUND O. Characterization of complete genomes of Camelus dromedarius papillomavirus type 1 and 2. **J. Gen. Virol.**, 2011, 92, 1769-1777.
19. UZAL FA., LATORRACA A., GHODDUSI M., HORN M., ADAMSON M., KELLY WR., SCHENKEL R. An apparent outbreak of cutaneous papillomatosis in Merino sheep in Patagonia, Argentina. **Vet. Res. Commun.**, 2000, 24,197-202.