BJVP
Brazilian Journal of Veterinary Pathology
ISSN 1983-0246

**Original Full Paper**

# Matrix metalloproteinase 9 expression in canine mammary carcinomas

Bianca C. Gramulia[1], Lidia H. Pulz[1,2], Emerson F. F. Mota[3], Heidge Fukumasu[1], Ricardo F. Strefezzi[1*]

[1]Laboratório de Oncologia Comparada e Translacional, Departamento de Medicina Veterinária, Faculdade de Zootecnia e Engenharia de Alimentos da Universidade de São Paulo (FZEA-USP), Pirassununga, SP, Brazil.
[2]Departamento de Patologia, Faculdade de Medicina Veterinária e Zootecnia da Universidade de São Paulo (FMVZ-USP), São Paulo, SP, Brazil.
[3]Laboratório Histopet, São Paulo, SP, Brazil.
*** Corresponding author:** Laboratório de Oncologia Comparada e Translacional, Departamento de Medicina Veterinária, Faculdade de Zootecnia e Engenharia de Alimentos da Universidade de São Paulo (FZEA-USP). Av. Duque de Caxias Norte, 225, Pirassununga, SP 13635-900, Brazil.
E-mail: rstrefezzi@usp.br

Submitted April 26th 2016, Accepted June 02nd 2016

## Abstract

Mammary neoplasms are among the most common canine tumors, with high risk of invasion and metastasis. Important steps for these events are the loss of cell adhesion to the main tumor mass and extracellular matrix degradation. Matrix metalloproteinases (MMPs) are proteolytic enzymes containing zinc, which are capable of degrading and remodeling the surrounding extracellular matrix, facilitating these events. Involvement of MMPs has been demonstrated in many pathological processes, as well as in human and canine tumors, which has been related to malignancy and prognosis. The aim of this study was to characterize the immunohistochemical expression of matrix metalloproteinase 9 (MMP-9) in canine mammary gland tumors, as well as to verify its relation with the different histologic patterns. Thirty-one of the 41 tumors (75.61%) were positive. Twenty-two samples (70.97%) had diffuse cytoplasmic immunostaining and 9 (29.03%) had a finely granular pattern. Immunostaining intensity was strong in 21 (67.74%) tumors and weak in 10 (32.26%). No statistically significant differences were found between anaplastic carcinomas, carcinomas in a mixed tumor and simple carcinomas regarding positivity (p=0.9707), intensity (p=0.5386) and staining pattern (0.6135); between solid carcinomas and simple papillary carcinomas for positivity (p=0,7333), intensity (p=0.7333) and staining pattern (p=0.3037); or between solid carcinomas and simple tubular and papillary carcinomas for positivity (p=0.9682), intensity (p=0.8450) and staining pattern (p=0.5068). MMP-9 was detected with variable intensity and morphological patterns of cytoplasmic staining. However significant statistic differences were not found between the histological types or histopathological grades.

**Key words:** canine, extracellular matrix, mammary tumor, MMP-9, prognostic markers.

## Introduction

Mammary gland tumors are the most frequent tumors in female dogs, as well as in women, accounting for up to 52% of the cases (31, 33). Almost half of them are malignant and are commonly found in females with 9.5 years or more. Intact or late-spayed females correspond to the majority of the cases. These tumors also share epidemiological, clinical, pathological, biochemical and genetic aspects with human counterparts (24, 27), being considered a good comparative model for human breast cancer. Perez et al. (28) demonstrated positive correlation between diets with high proportion of bovine or swine meat and obesity with the incidence of mammary neoplasms. Use of contraceptives it's also a predisposing factor to the disease (31).

Mammary tumors are frequently firm, nodular, variable sized, and might occur in any location of the mammary gland chain. However, inguinal mammary glands are the most affected (6, 33, 34). Multiple lesions

 All rights reserved 2007.

and different histological types can be found in the same animal. Skin and/or abdominal wall invasion are possible, with or without ulceration and some histological types are accompanied by intense inflammatory response.

Prognostic studies in humans have provided useful information for accurate diagnosis and treatment, decreasing collateral effects and increasing survival of patients. In veterinary medicine, these studies also have great potential (1, 6, 13, 23, 24), and biological markers can be used to differentiate neoplastic tissue from the normal tissue, to indicate survival or recurrence probability, or even to determine the response to a specific treatment, thereby acting as predictive markers (12, 24). Most part of the prognostic markers has been investigated through immunohistochemical methods. However, macroscopic features, dimensions and regional lymph node involvement are considered important indicators of biological behavior (1, 24). Estrogen (ER) and progesterone receptors (PR) are normally expressed in the female tissues, in different levels. Most of benign tumors express higher levels of ER and PR than malignant ones (1, 6, 24, 27, 35). Tumor malignancy was correlated with decrease of hormonal requirement in canine tumors. Women with ER and PR positive mammary tumors have better prognosis and effective adjuvant therapy, reaching up to 60% of success, than ER and PR negative patients (24, 27). Association between EGFR expression and the epithelial malignant component was also described for carcinomas in mixed tumors, suggesting that alterations of this receptor represent a step in malignant transformation in canine mammary tumors (3).

Metastases, the major complicating factor for treatment and cure, occur mainly at the regional lymph nodes (5), followed by lungs, liver, heart, kidneys, and adrenal glands (25). Bone and spleen metastases are rare (24, 25). Simple carcinoma is the most common histological type, followed by malignant mixed tumor, complex adenoma, and benign mixed tumor (24, 25). Invasion and metastasis are typical features of carcinomas (18). Disruption of the extracellular matrix is an important step for successful cell invasion, and follows the secretion of several proteases and cytokines in the stroma of cancerous tissue (11, 18). These processes are dependent on Matrix metalloproteinases (MMPs), which are zinc-dependent proteolytic enzymes secreted by several stromal cells, as fibroblasts and leukocytes, which are capable of degrade basement membranes and other extracellular matrix compounds. Therefore, they have important role in neoplastic invasion and metastasis. Furthermore, they stimulate angiogenesis, inflammation and contribute to tumor growth (36). MMP's activities are mostly regulated by tissue inhibitors of metalloproteinases (TIMPs) (2, 19, 30, 36). MMP-2 and MMP-9 are the most studied MMPs due to its ability to degrade type IV collagen, the main compound of basement membranes. MMP-9 expression can be used as distant metastasis predictor in human breast cancer (2, 14, 19, 36, 37), and MMP-2 is related with shorter survival (16). Thus, the aim of this research was characterize the immunohistochemical expression of MMP-9 in different histological types of canine mammary gland tumors.

## Material and methods

Forty-one mammary carcinoma samples from 41 bitches were routinely processed for histological analysis, after fixation in 10% formalin for 48 hours. Histological sections were stained with hematoxylin and eosin (29) for diagnosis, histological classification and grading according to Cassali et al. (5). Histologically heterogeneous tumors were avoided in order to better characterize the histopathologic variants. Then, one representative area of each tumor was obtained for Tissue Micro Arrays (TMAs) production. The TMAs were composed of 2 mm-cores.

Immunohistochemistry was performed according to Hsu et al. (17), with modifications. Antigen retrieval was achieved by heating the sections in citrate buffer (pH 6.0) in a pressure cooker for 1 minute. Endogenous peroxidase was blocked with 3% hydrogen peroxide. Subsequently, non-specific binding was blocked with 5% skim milk solution for 90 minutes, followed by incubation with primary rabbit polyclonal anti-MMP-9 antibody (1:500, DakoCytomation), overnight, at a 4°C in a humid chamber, accordingly to the manufacturer's instructions. Negative control was incubated with normal rabbit immunoglobulin G (IgG) in the same dilution and conditions as the primary antibody. Secondary biotinylated antibody (LSAB+ System HRP; Ref. K0690; DakoCytomation) was applied accordingly to the manufacturer's instructions followed by streptavidin-peroxidase complex (Ref. 0690, DakoCytomation, Inc.) for 20 minute each, at room temperature. Immunoreaction was observed with Diaminobenzidine (DAB) chromogen. The slides were counterstained with Harry's hematoxylin.

Two simultaneous observers determined immunostaining scores semiquantitatively, as negative, weak or strong (2). Cytoplasmic staining pattern was also evaluated as granular or diffuse. Results were compared to the histological types using ANOVA/Kruskal-Wallis, followed by Dunn's test, and Mann-Whitney test. Significance level was set as 5%.

## Results

TMAs were composed by seven (17.07%) anaplastic carcinomas, eight (19.51%) carcinomas in a mixed tumor, four (9.75%) solid carcinomas, ten (24.39%) simple carcinomas of the tubular-type and ten (24.39%) simple carcinomas of the papillary type, one (2.44%) simple carcinoma and one (2.44%) micropapillary carcinoma. The histopathological types and their respective grades are listed in Tables 1 to 3.

Thirty-one tumors (75.61%) were positive to MMP-9 (Table 1). Twenty-two samples (70.97%) showed

 All rights reserved 2007.

**Table 1.** Distribution of the carcinomas analyzed according to the positivity for antibody anti-MMP-9.

| | Antibody anti-MMP-9 | |
|---|---|---|
| **Diagnosis** | **Positive** | **Negative** |
| Anaplastic carcinoma – grade III | 5 (71.4%) | 2 (28.6%) |
| Carcinoma in a mixed tumor - grade I | 5 (71.4%) | 2 (28.6%) |
| Carcinoma in a mixed tumor - grade II | 1 (100%) | - |
| Solid carcinoma - grade I | 2 (66.7%) | 1 (33.3%) |
| Solid carcinoma – grade II | 1 (100%) | - |
| Simple carcinoma – grade II | 1 (100%) | - |
| Simple carcinoma – tubular – grade I | 8 (100%) | - |
| Simple carcinoma – tubular – grade II | 1 (50%) | 1 (50%) |
| Simple carcinoma – papillary – grade I | 5 (55.6%) | 4 (44.4%) |
| Simple carcinoma –papillary – grade II | 1 (100%) | - |
| Micropapillary carcinoma – grade II | 1 (100%) | - |

**Table 2**. Distribution of carcinomas analyzed according to cytoplasmic staining pattern.

| | Staining pattern | |
|---|---|---|
| **Diagnosis** | **Diffuse** | **Granular** |
| Anaplastic carcinoma – grade III | 5 (100%) | - |
| Carcinoma in a mixed tumor - grade I | 3 (60%) | 2 (40%) |
| Carcinoma in a mixed tumor - grade II | 1 (100%) | - |
| Solid carcinoma - grade I | 1 (50%) | 1 (50%) |
| Solid carcinoma – grade II | - | 1 (100%) |
| Simple carcinoma – grade II | 1 (100%) | - |
| Simple carcinoma – tubular – grade I | 5 (62.5%) | 3 (37.5%) |
| Simple carcinoma – tubular – grade II | 1 (100%) | - |
| Simple carcinoma – papillary – grade I | 4 (80%) | 1 (20%) |
| Simple carcinoma – papillary – grade II | 1 (100%) | - |
| Micropapillary carcinoma – grade II | - | 1 (100%) |

**Table 3**. Distribution of carcinomas according to cytoplasmic staining intensity.

| | Staining intensity | |
|---|---|---|
| **Diagnosis** | **Strong** | **Weak** |
| Anaplastic carcinoma – grade III | 3 (60%) | 2 (40%) |
| Carcinoma in a mixed tumor - grade I | 5 (100%) | - |
| Carcinoma in a mixed tumor - grade II | 1 (100%) | - |
| Solid carcinoma - grade I | 2 (100%) | - |
| Solid carcinoma – grade II | - | 1 (100%) |
| Simple carcinoma – grade II | 1 (100%) | - |
| Simple carcinoma – tubular – grade I | 4 (50%) | 4 (50%) |
| Simple carcinoma – tubular – grade II | - | 1 (100%) |
| Simple carcinoma – papillary – grade I | 3 (60%) | 2 (40%) |
| Simple carcinoma – papillary – grade II | 1 (100%) | - |
| Micropapillary carcinoma – grade II | 1 (100%) | - |

 All rights reserved 2007.

diffuse cytoplasmic immunostaining (Fig. 1) and a finely granular pattern (Fig. 2) was observed in 9 (29.03%), as described in Table 2. The tumors were also graded according to their immunostaining intensity: 21 (67.74%) showed strong and 10 (32.26%) showed weak immunolabelling (Table 3).

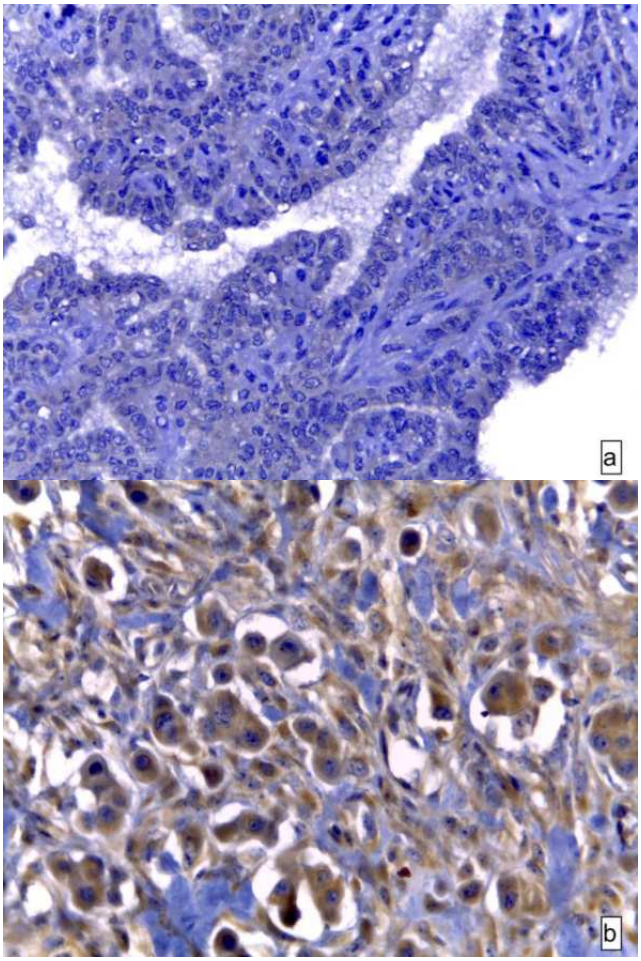


**Figure 1.** Simple papillary carcinoma. (a) diffuse weak cytoplasmic immunostaining, and an anaplastic carcinoma (b); diffuse strong cytoplasmic immunostaining for MMP-9. IHC, counterstained with Harris hematoxylin.

There were no statistically significant differences between anaplastic carcinomas, carcinomas in a mixed tumor and simple carcinomas regarding positivity (p=0.9707), intensity (p=0.5386) and staining pattern (0.6135). Similar results were observed when solid carcinomas were compared to simple papillary carcinomas for positivity (p=0,7333), intensity (p=0.7333) and staining pattern (p=0.3037); and when solid carcinomas were compared to simple tubular and papillary carcinomas grouped: positivity (p=0.9682), intensity (p=0.8450) and staining pattern (p=0.5068). These categories were chosen due to reasonable number of cases for statistical analysis and because they represent known prognostic variables, with higher aggressiveness for anaplastic carcinomas, followed by solid and simple carcinomas (22).

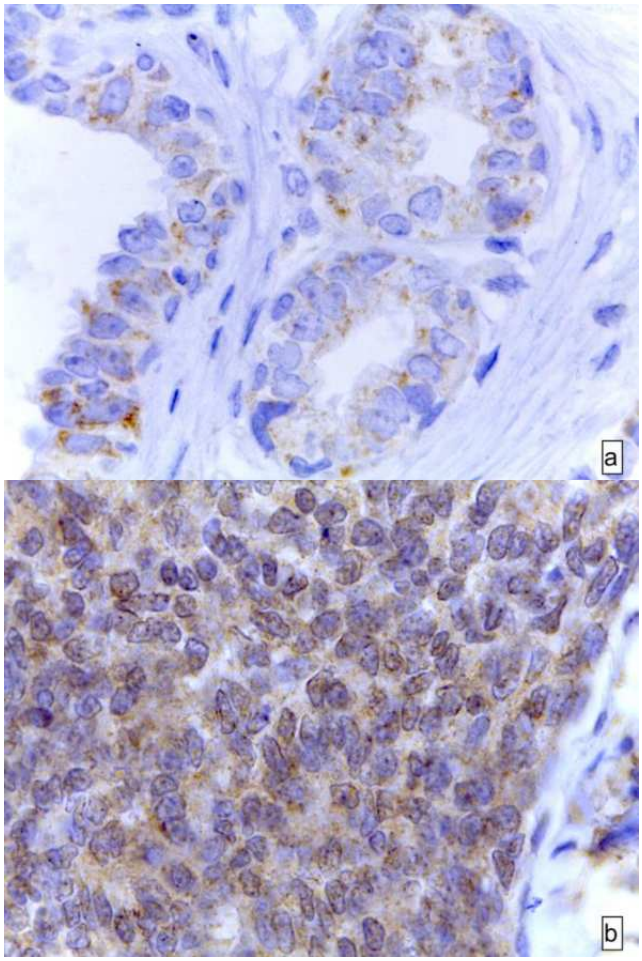


**Figure 2.** Simple tubular carcinoma. (a) granular weak cytoplasmic immunostaining, and a solid carcinoma (b) showing granular strong cytoplasmic immunostaining for MMP-9. IHC, counterstained with Harris hematoxylin.

## Discussion

In human breast cancer, a relation was established between breast density and increased cancer susceptibility, with tumors arising within the densest parts of the mammary tissue (4). These densest areas are more often associated with high cellularity and collagen concentration, but the contribution of the last is not yet well understood (7). MMPs are involved in degradation of extracellular matrix elements and considered predictive of worse prognoses in several tumors (8, 11, 26). Among this group of enzymes, MMP-9 is believed to be involved in the complex metastatic cascade, mainly by degrading extracellular matrix compounds and contributing to invasion.

In the present study, no significant differences were found in MMP-9 expression between histological

types of canine mammary carcinomas. Our data are comparable to those from similar studies. Aresu et al. (2) analyzed the MMP-9 expression at mRNA and protein levels in canine mammary tumors and found a minor role for this gelatinase. In a research involving 94 women, Zhang et al. (38) found no relation between MMP-9 expression and worst prognosis, tumor size, presence of metastasis in lymph nodes and recurrence.

The presence of MMP-9 has been demonstrated in human tumors, as well as its higher expression in malignant tumors in comparison to benign ones (7). Similar results were also obtained for proliferative and invasive tumors. Previous observations in human breast cancer (9) and canine mammary tumors (2, 15) demonstrated that MMP-9 positivity was higher in malignant tumors than in adenomas. Santos et al. (32) observed that stromal and neoplastic cells in malignant mammary gland neoplasms express higher MMP-9 levels than in benign lesions. Loukopoulos et al. (21) showed higher MMP-9 expression in canine tumors than in benign or non-neoplastic tissues. DoCampo et al. (10) observed that canine malignant melanomas express higher MMP-9 levels than melanocytomas. MMP-9 expression was also correlated to histopathological grading in canine cutaneous mast cell tumors (20) and osteosarcomas (21).

TMAs are composed of small samples from each tumor and, despite the immunohistochemical standardization advantages, might not reflect the variable features of the whole lesion, due to mammary tumors heterogeneity (5, 13). In order to minimize this bias, we selected only homogeneous tumors for the TMA, and repeated part of the immunohistochemical tests in the original samples, obtaining the same results.

A granular pattern for MMP-9 immunostaining was described in our study. However, the biological significance of this observation could not be verified, as well as significant differences between the histological types. This may be explained by the small number of cases. In conclusion, we confirmed that canine mammary carcinomas express MMP-9 with variable frequency and different staining patterns. Studies involving a higher number of cases and including follow up data are under development for a more in-depth analysis of the MMP-9 prognostic value for these neoplasms.

## Acknowledgements

This research was supported by Fundação de Amparo à Pesquisa do Estado de São Paulo (FAPESP, grants #2008/54594-4, #2010/05094-5 and #2012/09266-0).

## References

1. ABREU E., KOIFMAN S. Fatores prognósticos no câncer de mama feminina. Review. **Rev. Bras. Cancerol.**, 2002, 48, 113-131.
2. ARESU L., GIANTIN M., MORELLO E., VASCELLARI M., CASTAGNARO M., LOPPARELLI R., ZANCANELLA V., GRANATO A., GARBISA S., ARICÒ A., BRADASCHIA A., MUTINELLI F., DACASTO M. Matrix Metallo-proteinases and their inhibitors in canine mammary tumors. **BMC Vet. Res.**, 2011, 7, 33.
3. BERTAGNOLLI AC., FERREIRA E., DIAS EJ., CASSALI GD. Canine mammary mixed tumours: immunohistochemical expressions of EGFR and HER-2. **Aust. Vet. J.**, 2011, 89, 8, 312-317.
4. BOYD NF., DITE GS., STONE J., GUNASEKARA A., ENGLISH DR., MCCREDIE MR., GILES GG., TRITCHLER D., CHIARELLI A., YAFFE MJ., HOPPER JL. Heritability of mammographic density, a risk factor for breast cancer. **N. Engl. J. Med.**, 2002, 347, 886-894.
5. CASSALI GD., LAVALLE GE., FERREIRA E., ESTRELA-LIMA A., DE NARDI AB., GHEVER C., SOBRAL RA., AMORIM RL., OLIVEIRA LO., SUEIRO FAR., BESERRA HEO., BERTAGNOLLI AC., GAMBA CO., DAMASCENO KA., CAMPOS CB., ARAUJO MR., CAMPOS LC., MONTEIRO LN., NUNES FC., HORTA RS., REIS DC., LUVIZOTTO MCR., MAGALHÃES GM., RAPOSO JB., FERREIRA AMR., TANAKA NM., GRANDI F., UBUKATA R., BATSCHINSKI K., TERRA EM., SALVADOR RCL., JARK PC., DELECRODI JER., NASCIMENTO NA., SILVA DN., SILVA LP., FERREIRA KCRS., FREHSE MS., DI SANTIS GW., SILVA EO., GUIM TN., KERR B., CINTRA PP., SILVA FBF., LEITE JS., MELLO MFV., FERREIRA MLG., FUKUMASU H., SALGADO BS., TORRES R. Consensus for the Diagnosis, Prognosis and Treatment of Canine Mammary Tumors. **Braz. J. Vet. Pathol.**, 2014, 7, 2, 38-69.
6. CHANG CC., TSAI MH., LIAO JW., CHAN JP., WONG ML., CHANG SC. Evaluation of hormone receptor expression for use in predicting survival of female dogs with malignant mammary gland tumors. **J. Am. Vet. Med. Assoc.**, 2009, 235, 391-396.
7. CONKLIN MW., KEELY PJ. Why the stroma matters in breast cancer: insights into breast cancer patient outcomes through the examination of stromal biomarkers. **Cell. Adh. Migr.**, 2012, 6, 249-260.
8. CURRAN S., MURRAY GI. Matrix metallo-proteinases in tumor invasion and metastasis. **J. Pathol.**, 1999, 189, 300-308.
9. DEL CASAR JM., GONZÁLEZ LO., ALVAREZ E., JUNQUERA S., MARÍN L., GONZÁLEZ L., BONGERA M., VÁZQUEZ J., VIZOSO FJ. Comparative analysis and clinical value of the expression of metalloproteases and their inhibitors by intratumor stromal fibroblasts and those at the invasive front of breast carcinomas. **Breast Cancer Res. Treat.**, 2009, 116, 39-52.

 All rights reserved 2007.

10. DOCAMPO MJ., CABRERA J., RABANAL RM., BASSOLS A. Expression of matrix metalloproteinase-2 and -9 and membrane-type 1 matrix metalloproteinase in melanocytic tumors of dogs and canine melanoma cell lines. **Am. J. Vet. Res.**, 2011, 72, 1087-1096.
11. EGEBLAD M., WERB Z. New functions for the matrix metalloproteinases in cancer progression. **Nat. Rev. Cancer**, 2002, 2, 161-174.
12. EISENBERG ALA., KOIFMAN S. Câncer de Mama: Marcadores Tumorais. **Rev. Brasil. Cancerol.**, 2001, 4, 377-388.
13. GOLDSCHMIDT M., PEÑA L., RASOTTO R., ZAPPULLI V. Classification and Grading of Canine Mammary Tumors. **Vet. Pathol.**, 2011, 48, 117.
14. GONZÁLEZ LO., GONZÁLEZ-REYES S., MARÍN L., GONZÁLEZ L., GONZÁLEZ JM., LAMELAS ML., MERINO AM., RODRÍGUEZ E., PIDAL I., DEL CASAR JM., ANDICOECHEA A., VIZOSO F. Comparative analysis and clinical value of the expression of metalloproteases and their inhibitors by intratumour stromal mononuclear inflammatory cell and those at the invasive front of breast carcinomas. **Histopathology**, 2010, 57, 862-876.
15. HIRAYAMA K., YOKOTA H., ONAI R., KOBAYASHI T., KUMATA T., KIHARA K., OKAMOTO M., SAKO T., NAKADE T., IZUMISAWA Y., TANIYAMA H. Detection of matrix metalloproteinase in canine mammary tumors: analysis by immunohistochemistry and zymography. **J. Comp. Pathol.**, 2002, 127, 249-256.
16. HIRVONEN R., TALVENSAARI-MATTILA A., PÄÄKKÖ P., TURPEENNIEMI-HUJANEN T. Matrix metalloproteinase-2 (MMP-2) in T1-2N0 breast carcinoma. **Breast Cancer Res. Treat.**, 2003, 77, 85-91.
17. HSU MK., RAINE L., FANGER H. Use of avidin-biotin-peroxidase complex (ABC) in immunoperoxidase techniques: a comparison between ABC and unlabeled antibody (PAP) procedures. **J. Histochem. Cytochem.**, 1981, 29, 577-580.
18. KARAYANNOPOULOU M., KALDRYMIDOU E., CONSTANTINIDIS TC., DESSIRIS A. Histological grading and prognosis in dogs with mammary carcinomas: application of a human grading method. **J. Comp. Pathol.**, 2005, 133, 246-252.
19. KAWAI K., UETSUKA K., DOI K., NAKAYAMA H. The Activity of Matrix Metalloproteinase (MMPs) and Tissue Inhibitors of Metalloproteinase (TIMPs) in Mammary Tumors of Dogs and Rats. **J. Vet. Med. Sci.**, 2006, 68, 105-111.
20. LEIBMAN NF., LANA SE., HANSEN RA., POWERS BE., FETTMAN MJ., WITHROW SJ., OGILVIE GK. Identification of matrix metalloproteinases in canine cutaneous mast cell tumors. **J. Vet. Intern. Med.**, 2000, 14, 583-586.
21. LOUKOPOULOS P., MUNGALL BA., STRAW RC., THORNTON JR., ROBINSON WF. Matrix metalloproteinase-2 and -9 involvement in canine tumors. **Vet. Pathol.**, 2003, 40, 382-394.
22. MISDORP W. Tumors of the mammary gland. MEUTEN DJ. (Ed). **Tumors in Domestic Animals**. 4 ed. Iowa State Press, Ames 2002, 575-606.
23. MORRIS JS. Improving the diagnosis and treatment of canine mammary tumours: Immunohistochemical markers as prognostic tools. **Vet. J.**, 2010, 184, 3-4.
24. MOTTA AC. **Patologia Molecular dos Tumores Caninos: Expressão de Marcadores Prognósticos e Mioepiteliais (Molecular pathology of canine tumours: expression of prognostic and myoepithelial markers).** Thesis, Doctorate, Faculty of Medicine, University of Rio Grande do Sul, Porto Alegre, RS, Brazil. 2008.
25. OLIVEIRA FILHO JC., KOMMERS GD., MASUDA EK., MARQUES BMFPP., FIGHERA RA., IRIGOYEN LF., BARROS CSL. Estudo retrospectivo de 1.647 tumores mamários em cães. **Pesq. Vet. Bras.**, 2010, 30, 177-185.
26. PAGE-MCCAW A., EWALD AJ., WERB Z. Matrix Metalloproteinases and the regulation of tissue remodeling. **Nat. Rev. Mol. Cell. Biol.**, 2007, 8, 221-233.
27. PEÑA L., GAMA A., GOLDSCHMIDT MH., ABADIE J., BENAZZI C., CASTAGNARO M., DÍEZ L., GÄRTNER F., HELLMÉN E., KIUPEL M., MILLÁN Y., MILLER MA., NGUYEN F., POLI A., SARLI G., ZAPPULLI V., DE LAS MULAS JM. Canine mammary tumors: a review and consensus of standard guidelines on epithelial and myoepithelial phenotype markers, HER2, and hormone receptor assessment using immunohistochemistry. **Vet. Pathol.**, 2014, 51, 127-145.
28. PEREZ AD., RUTTEMAN GR., PEÑA L., BEYNEN AC., CUESTA P. Relation between habitual diet and canine mammary tumors in a case control study. **J. Vet. Int. Med.**, 1998, 12, 132-139.
29. PROPHET EB., MILLS B., ARRINGTON JB., SOBIN LH. **Laboratory Methods in Histotechnology**. Armed Forces Institute of Pathology, Washington, DC, 1992.
30. PULZ LH., STREFEZZI RF. Proteases as prognostic markers in human and canine cancers. **Vet. Comp. Oncol.**, 2016 (in press).
31. RUTTEMAN GR., WITHROW SJ., MACEWEN EG. Tumors of the mammary gland. WITHROW SJ., MACEWEN EG. (Eds). **Small Animal Clinical Oncology.** 3 ed. W.B. Saunders, Philadelphia 2001, 455-477.
32. SANTOS AA., LOPES CC., MARQUES RM., AMORIM IF., GÄRTNER MF., DE MATOS AJ. Matrix metalloproteinase -9 expression in mammary gland tumors in dog and its relationship with

prognostic factors and patient outcome. **Am. J. Vet. Res.**, 2012, 73, 689-697.

33. SORENMO KU., KRISTIANSEN VM., COFONE MA., SHOFER FS., BREEN AM., LANGELAND M., MONGIL CM., GRONDAHL AM., TEIGE J., GOLDSCHMIDT MH. Canine mammary gland tumor; a histological continuum from benign to malignant; clinical and histopathological evidence. **Vet. Comp. Oncol.**, 2009, 7, 162-172.
34. SORENMO KU., ROSATTO R., ZAPPLLI V., GOLDSCHMIDT MH. Development, Anatomy, Histology, Lymphatic Drainage, Clinical Features, and Cell Differentiation Markers os Canine Mammary Gland Neoplasms. **Vet. Pathol.**, 2011, 48, 85-97.
35. SPOERRI M., GUSCETTI F., HARTNACK S., BOOS A., OEI C., BALOGH O., NOWACZYK RM., MICHEL E., REICHLER IM., KOWALEWSKI MP. Endocrine control of canine mammary neoplasms: serum reproductive hormone levels and tissue expression of steroid hormone, prolactin and growth hormone receptors. **BMC Vet. Res.**, 2015, 11, 235.
36. SUN J. Matrix Metalloproteinases and Tissue Inhibitors of Metalloproteinases Are Essential for the Inflammatory Response in Cancer Cells. **J. Signal. Transduct.**, 2010, 985132.
37. VINOTHINI G., ARAVINDRAJA C., CHITRATHARA K., NAGINI S. Correlation of matrix metalloproteinases and their inhibitors with hipoxia and angiogenesis in premenopausal patients with adenocarcinoma of the breast. **Clin. Biochem.**, 2011, 44, 969-974.
38. ZHANG YG., DU J., TIAN XX., ZHONG YF., FANG WG. Expression of E-cadherin, beta-cadherin, catepsin D, gelatinases and their inhibitors in invasive ductal breast carcinomas. **Chinese Med. J.**, 2007, 120, 1597-1605.