



Case Report

Enzootic hematuria in cattle from Northeastern Brazil

Suélen D. S. Reis¹, Juliana T. S. A. Macêdo², Ricardo S. Oliveira², Tiago C. Peixoto³,
Margareth M. Ferreira⁴, André Luís Gasper⁵, Pedro M. O. Pedroso^{2*}

¹Setor de Patologia Veterinária, Universidade Federal do Recôncavo da Bahia (UFRB), Cruz das Almas, BA, Brazil.

²Laboratório de Patologia Veterinária, Universidade de Brasília (UnB), Brasília, DF, Brazil.

³Laboratório de Patologia Veterinária, Universidade Federal da Bahia (UFBA), Salvador, BA, Brazil.

⁴Centro de Desenvolvimento da Pecuária (CDP), Universidade Federal da Bahia (UFBA), Santo Amaro, BA, Brazil.

⁵Departamento de Ciências Naturais, Fundação Universidade Regional de Blumenau, Blumenau, SC, Brazil.

* **Corresponding Author:** Universidade de Brasília (UnB), Via L4 Norte S/N, Brasília, DF 70910-970, Brazil.
E-mail: pedrosovet@yahoo.com.br

Submitted February 04th 2016, Accepted April 04th 2016

Abstract

Two outbreaks (A and B) of bovine enzootic hematuria in Bahia in the period 2012-2013 were described. In the outbreak A, a cow was necropsied and 27 cattle were slaughtered in a slaughterhouse, and the second outbreak two cattle were necropsied. In the outbreak A of a cattle herd 28 mixed breed, approximately two-years-old, three had hematuria for about three months and progressive weight loss. Grossly, the main findings in the bladder were petechiae, papillomatous formations, thickening areas of mucosa white and red nodules. In 2/28 cattle there were no microscopic changes in the urinary bladder, whereas 26/28 cattle had some kind of change. In four of these cattle neoplastic changes (2 cases with hemangioma, 1 with cavernous hemangioma and hemangiosarcoma, and 1 with transitional cell carcinoma) were observed. In the outbreak B, 42 cattle from a herd consisting of 278 Nelore cattle, with approximately four-years-old, presented clinical signs characterized by weakness, anemia, weight loss and intermittent hematuria. Of the 42 affected cattle, 23 died and two were necropsied. At necropsy, the main changes were anemia and marked wrinkling and diffuse thickening of the bladder mucosa, associated with multiple focal hemorrhages. Microscopically lesions consisted of benign angioblastic proliferation, urothelial carcinomas, hemangiomas and hemangiosarcoma. The diagnosis of bovine enzootic hematuria was based on clinical, pathological and epidemiological findings. The study showed that bovine enzootic hematuria caused by *Pteridium arachnoideum* is a diagnosis to be considered in cattle in Southwestern region of the State of Bahia, Brazil.

Key words: cattle diseases, hematuria, urinary bladder, neoplasia, bracken fern, *Pteridium arachnoideum*.

Introduction

Pteridium aquilinum (L.) Kuhn (= *Pteris aquilina* L.), family Polypodiaceae, is popularly known in Brazil as “samambaia”. Until recently, *Pteridium aquilinum* was considered to be the only species of the genus *Pteridium*; however, research has demonstrated that some of those were actually different species, two of which exist in Brazil (*P. arachnoideum* and *P. caudatum*) (14). These plants are found in all regions of Brazil. Cases of acute or chronic poisoning by *Pteridium* sp. in cattle have been described in the Southern, Southeastern, and Mid-Western regions of Brazil (3, 5, 6, 9, 12, 13, 15, 16).

Bovine enzootic hematuria occurs at any of the year and affects cattle over four years of age, especially dairy cows and trek oxes. At necropsy, thickening wall, and multifocal dark-red nodules, light-red nodules, papillomas, and multifocal hemorrhages can be observed in the wall of the bladder (3, 7, 16). Microscopically, both non-neoplastic alterations and metaplastic), neoplastic changes can be seen (11).

Data regarding poisoning by *P. arachnoideum* in the Northeastern region of Brazil are scarce. The goal of this report is to describe the main epidemiological and clinical-pathological aspects of two outbreaks enzootic hematuria in cattle from the state of Bahia, Brazil.

Case report

The two outbreaks (A and B) were investigated in the state during 2012-2013. In outbreak A, necropsy one bovine was necropsied and 27 were observed at slaughter. In outbreak B, two cattle were euthanized “*in extremis*”, and necropsied. Clinical and epidemiological data were obtained from local veterinarians. During necropsy or inspection at slaughter, tissue samples were collected, fixed in 10% formalin, routinely processed for histology, and stained with hematoxylin and eosin. Lesions of the bladder were classified according to previous studies (7, 11). Plant specimens from both locations where outbreaks of enzootic hematuria occurred were submitted for botanical identification.

In March 2012, a 2-year-old cow, from a herd of 28 cattle, mixed breed, approximately two-years-old (outbreak A) exhibited hematuria and progressive weight loss (Fig. 1) for approximately 3 months. Microscopically, an urinary bladder hemangioma was diagnosed. The animal was from Southwestern Bahia (15°27'32" South and 40°44'20" West). The pasture where cattle were held consist of *Brachiaria* grass with moderate invasion of *P. arachnoideum* (Fig. 2). The attending veterinarian, informed that the 28 cattle were purchased from a location that did not have *P. arachnoideum*, remained in the farm with moderate invasion of the plant for one year before they were transported to a farm in the region (12°40'12" South and 39°06'07" West). Diagnosis of bovine enzootic hematuria was possible based on epidemiological data, clinical signs, and pathological findings. Of the 27 remaining cattle, two exhibited intermittent hematuria for approximately 3 months, and progressive weight loss. All cattle from this herd were then send to slaughter. The main gross findings in the mucosal bladder collected at slaughter house were: petechiae, papillomatous formations, white areas of mucosal thickening, red nodules (Fig. 3) of multifocal distribution; in one case, the nodule was ulcerated, and in another, there was a pedunculated dark mass due to, congestion and necrosis from a twisted pedicle.

Twenty six of the 28 slaughtered cattle from outbreak A exhibit some type of microscopic change in the urinary bladder; including four neoplasms (two cases of hemangioma, one case of cavernous hemangioma associated hemangiosarcoma, and one transitional cell carcinoma) (Fig. 4). Non-neoplastic changes accounted for 92.85% of the cases, including: dysplasia (15/26), characterized by cytoplasmic vacuolation; hyperplasia (5/26), characterized by more than seven layers of epithelial cells in focally extensive areas of the urothelium; intraepithelial vacuoles in the urothelium (3/26); cystic cystitis (1/26), characterized by formation of cystic structures on the lamina propria, covered by transitional epithelium; squamous metaplasia (1/26), characterized by proliferation of well differentiated cells of the urothelium,

which became keratinized as they approach the lumen; and Brunn's nests (1/26), formed by cells of transitional epithelium grouped into nests on the lamina propria, with or without connection to the epithelial surface. General changes seen in the lamina propria were: mild hemorrhages (13/26), myxoid stroma (11/26), characterized by multifocal areas of loose connective tissue associated small amounts of amorphous and slightly basophilic material, mild swollen of endothelial cells (4/26), and dilation of lymphatic vessels (2/26). The inflammatory changes consisted of lymphoid follicles (8/26) organized around small vessels and histiocytic and lymphoplasmacytic infiltrate (1/26).

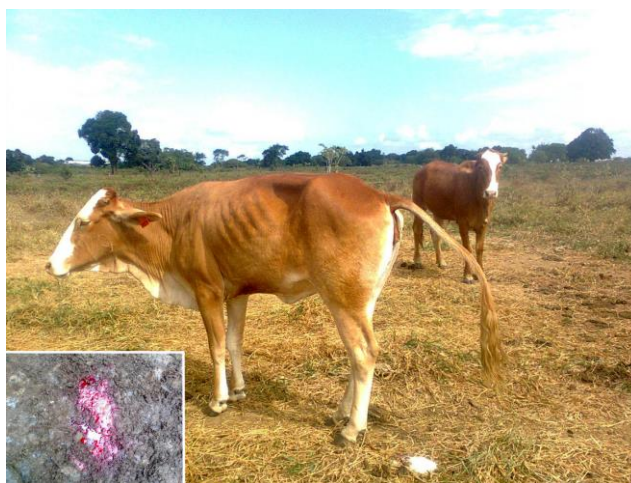

Figure 1. Bovine enzootic hematuria in Northeastern Brazil. (A) Bovine from outbreak A with progressive weight loss. In detail, hematuria.



Figure 2. Bovine enzootic hematuria in Northeastern Brazil. Pasture at the property from Southwestern Bahia (outbreak A). Note moderate invasion by *P. arachnoideum* in the area where the cattle were kept.

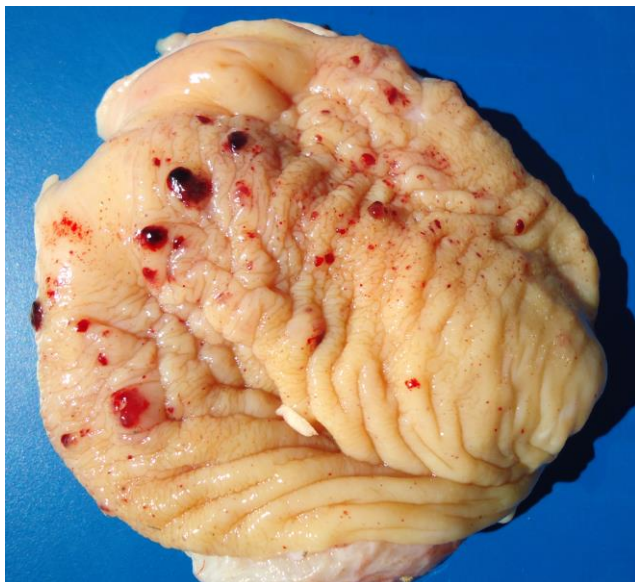


Figure 3. Bovine enzootic hematuria in Northeastern Brazil. Urinary bladder with petechiae and multifocal red nodules.

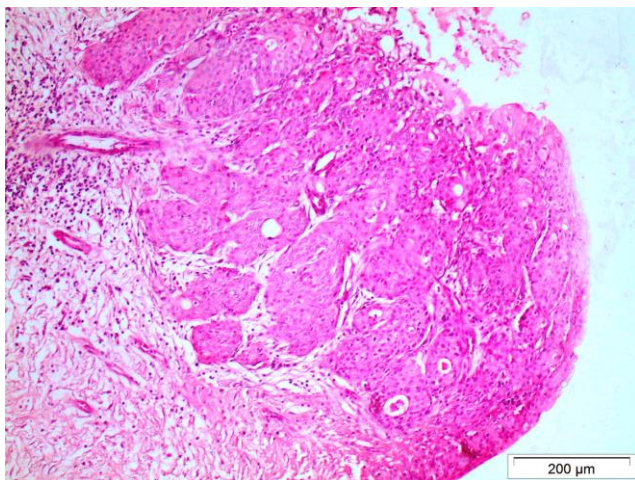


Figure 4. Bovine enzootic hematuria in Northeastern Brazil. Urinary bladder with transitional cell carcinoma in bovine from outbreak A exhibiting enzootic hematuria. (HE, obj. 20x).

Outbreak B occurred in May 2013 in Nelore cattle from a rural property in a farm (13°21'32" South and 39°48'54" West), of Southwestern Bahia. The herd, was raised in an extensive system, and consisted of 278 Nelore cattle, with approximately four years of age, which were kept in a pasture of *Brachiaria decumbens* intensely invaded by bracken fern that occupied over 70% of the area. According to the owner, the disease had been occurring for about three years in the farm, and affected only adult cattle, which exhibited weakness, anemia, weight loss, and hematuria. The disease was eventually fatal. The number of cases had intensified in the last

months, culminating with the death of 23 animals the same clinical signs as described above. For diagnostic confirmation, two four-years-old out of the 19 affected cows were euthanized while showing advanced disease, and necropsied. Physical examination revealed cachexia, dehydration, pale mucous membranes, and intermittent hematuria. Necropsy findings were moderate to marked, diffuse, wrinkling and thickening of the mucosa of the urinary bladder, associated with multiple petechiae and ecchymosis, nodular or polypoid proliferation, and occasional hemorrhagic areas with smooth or irregular surface, and areas of ulceration. In general, the areas with tissue proliferation were whitish to blackish-red, and with mm up to 4.5 cm in diameter. One of the bladders had irregular depressions, nodules, and prominent firm plaques on the mucosa. Microscopically, immature angioblastic proliferation of the lamina propria, transitional cell carcinomas, hemangiomas, and hemangiosarcomas were observed. The serological analyses of both animals were negative for leptospirosis.

The plants analyzed from both outbreaks were identified as *Pteridium arachnoideum*. It was classified by Dr. André Louis Gasper at the Department of Natural Sciences, University Foundation of Blumenau.

Discussion

Diagnosis of enzootic hematuria in young beef cattle in the state of Bahia, Brazil, was based on epidemiological, clinical, and pathological findings similar to the ones previous reports of this disease (7, 11, 14), combined with the botanical identification of the plant. Until then, bracken poisoning had been registered in Southern, Southeastern, and Midwestern regions of Brazil. In the Northeastern, there was the identification of the plant; but no report of the intoxication. Thus, the importance of bracken fern as a toxic plant of livestock was unknown in this region.

In the present study, *P. arachnoideum* was found in considerable amounts in the two farms where outbreaks occurred, and the severity of pasture invasion was considered moderate to marked, corresponding to 50% and 70%, respectively. In a study performed in 40 farms in the state of Mato Grosso, Brazil, the percentage of *P. arachnoideum* on the total pasture area was $9.6\% \pm 11.6$ (6).

Chronic bracken poisoning can occur in different times of the year and affects cattle over four years of age. The disease occurs when there is ingestion of less than 10 g/kg/day of the plant for one year or more. In outbreak A, cattle acquired from a location that did not have the plant and remained in the new property for one year. Animals in this study were beef cattle with a mean age of three years. Enzootic hematuria is rarely seen in young animals and in beef cattle (14). In outbreak B, suggests that the morbidity rate was 15%.

Clinical signs reported by the owners in outbreaks A and B corresponded to those observed during physical examination and were compatible with those described in the literature; hematuria being the main clinical sign (4, 7, 8, 14).

Microscopic findings included non-neoplastic and neoplastic changes; in outbreak A, with preponderance of non-neoplastic changes. This is consistent with a study conducted in cattle in the State of Rio Grande do Sul, where out of 19 changes found in 11 urinary bladders, only 5 were neoplastic, whereas 14 were non-neoplastic (7).

Another study which examined 59 urinary bladders of cattle the majority of alterations were neoplastic, although there they co-existed with inflammatory alterations and various types of neoplasms (11). The neoplasms found in both outbreaks have been identified in other studies (2, 6, 7, 11). In the present study, vascular neoplasms were predominant, as described by other authors from Brazil and from other countries (1, 2, 10).

Although there are no detailed reports on the influence of bovine enzootic hematuria over economy in the state of Bahia, we presume, based on anecdotal information the disease is more common than is document. Cattle raising is an important activity in the region where the outbreaks occurred, and the cases did not occur only in 2012 and 2013, which indicates that bovine enzootic hematuria has a considerable negative economic impact.

Based on epidemiological and clinical-pathological findings, it is possible to conclude that *Pteridium arachnoideum* in the form of bovine enzootic hematuria is a cause of death in young beef cattle in the State of Bahia, Northeastern Brazil, and should be considered in the differential diagnosis of similar diseases.

Acknowledgements

The authors acknowledge the financial support granted by Conselho Nacional de Desenvolvimento Científico e Tecnológico (CNPq), project number 475469/2012-7.

References

1. BULNES C., TOBAR AC. Lesiones asociadas a la Hematuria Enzootica Bovina (HEB) en animales de matadero (camal) de la Provincia Bolívar, Ecuador. **Rev. Salud Anim.**, 2014, 36, 97-105.
2. CARVALHO T., PINTO C., PELETEIRO MC. Urinary bladder lesions in bovine enzootic haematuria. **J. Comp. Pathol.**, 2006, 134, 336-346.
3. DÖBEREINER J., TOKARNIA CH., CANELLA CFC. Ocorrência de hematúria enzoótica e de carcinoma epidermóides no trato digestivo superior em bovinos no Brasil. **Pesq. Agropec. Bras.**, 1967, 2, 489-504.
4. FRANÇA TN., TOKARNIA CH., PEIXOTO PV. Enfermidades determinadas pelo princípio radiomimético de *Pteridium aquilinum* (Polypodiaceae). **Pesq. Vet. Bras.**, 2002, 22, 85-96.
5. FURLAN FH., COSTA FL., TORRES JÚNIOR SCS., KERBER FL., DAMASCENO ES., SALINO A., RIET-CORREA F. Perfil de propriedades rurais com pastos invadidos por *Pteridium arachnoideum* na região norte de Mato Grosso e prevalência de hematúria enzoótica bovina. **Pesq. Vet. Bras.**, 2014, 34, 753-759.
6. FURLAN FH., MENDES ER., DUCATTI KR., MARCON GC., DOMBROSKY T., AMORIM TM., RIET-CORREA F. Intoxicação aguda por *Pteridium arachnoideum* e *Pteridium caudatum* em bovinos e distribuição das plantas em Mato Grosso. **Pesq. Vet. Bras.**, 2014, 34, 343-348.
7. GABRIEL AL., KOMMERS GD., MASUDA EK., FIGHERA RA., PIAZER JVM., BARROS CSL., MARTINS TB., ROSA FB. Aspectos clínico-hematológicos e lesões vesicais na intoxicação crônica espontânea por *Pteridium aquilinum* em bovinos. **Pesq. Vet. Bras.**, 2009, 29, 515-525.
8. GALVÃO A., BRITO MF., ARAGÃO AP., YAMASAKI EM., PEIXOTO PV., TOKARNIA CH. Sobrevivência/viabilidade de bovinos com Hematúria Enzootica após transferência para região livre de *Pteridium arachnoideum*. **Pesq. Vet. Bras.**, 2012, 32, 887-902.
9. GAVA A., SCHILD AL., RIET-CORREA F. Bracken fern (*Pteridium aquilinum*) poisoning in cattle in Southern Brazil. **Vet. Hum. Toxicol.**, 2002, 44, 362-365.
10. GONZÁLES CE., CHAVERA AC., PERALES RC., FALCÓN NP., EVARISTO RR. Caracterización de las lesiones encontradas en bovinos con hematuria vesical enzoótica en la zona de Oxapampa, Pasco. **Rev Inv Vet Perú**, 2004, 15, 25-36.
11. PEIXOTO PV., FRANÇA TN., BARROS CSL., TOKARNIA CH. Histopathological aspects of bovine enzootic hematuria in Brazil. **Pesq. Vet. Bras.**, 2003, 23, 65-81.
12. SOUTO MAM., KOMMERS GD., BARROS CSL., PIAZER JVM., RECH RR., RIET-CORREA F., SCHILD AL. Neoplasias do trato alimentar superior de bovinos associadas ao consumo espontâneo de samambaia (*Pteridium aquilinum*). **Pesq. Vet. Bras.**, 2006, 26, 112-122.
13. SOUTO MAM., KOMMERS GD., BARROS CSL., RECH RR., PIAZER JVM. Neoplasmas da bexiga associados à hematúria enzoótica bovina. **Ciênc. Rural**, 2006, 36, 1647-1650.
14. TOKARNIA CH., BRITO MF., BARBOSA JD., PEIXOTO PV., DÖBEREINER J. **Plantas tóxicas do Brasil**. 2 ed., Helianthus, Rio de Janeiro 2012.
15. TOKARNIA CH., DÖBEREINER J., CANELLA CFC. Ocorrência de intoxicação aguda por samambaia

- (*Pteridium aquilinum* (L.) Kuhn) em bovinos no Brasil. **Pesq. Agropec. Bras.**, 1967, 2, 329-336.
16. TOKARNIA CH., DÖBEREINER J., CANELLA CFC. Ocorrência de hematúria enzoótica e de carcinoma epidermóides no trato digestivo superior em bovinos no Brasil. Parte II. Estudos complementares. **Pesq. Agropec. Bras.**, 1969, 4, 209-224.