



## Case Report

# Proventricular rupture associated with Psittaciforme 1 Bornavirus (PaBV) infection in a Major Mitchell Cockatoo (*Lophochroa leadbeateri*)

Jeann Leal de Araujo<sup>1\*</sup>, Quinci Plumlee<sup>1</sup>, Raquel R. Rech<sup>1</sup>, Andrea Winkel-Blair<sup>2</sup>,  
Sharman Hoppes<sup>2</sup>, Sarah M. Schneider<sup>1</sup>

<sup>1</sup>Department of Veterinary Pathobiology, Texas A&M University, College Station, Texas, USA.

<sup>2</sup>Department of small animal clinical sciences Texas A&M University, College Station, Texas, USA.

\* **Corresponding author:** Department of Veterinary Pathobiology, Texas A&M University, College Station, Texas, US. College of Veterinary Medicine & Biomedical Sciences Texas A&M University, 4467 TAMU. College Station, TX 77843-4467. E-mail: jleal@cvm.tamu.edu.m

Submitted May 19<sup>th</sup> 2016, Accepted June 17<sup>th</sup> 2016

## Abstract

This report describes a case of proventricular rupture associated with Psittaciforme 1 Bornavirus in a 10-year old Major Mitchell Cockatoo (*Lophochroa leadbeateri*) who presented with a 2-day history of weakness and weight loss. On necropsy, a fibrinonecrotizing coelomitis and an enlarged proventriculus with a 0.5 cm in diameter transmural perforation characterized the main findings. Histology confirmed the locally extensive, transmural necrotizing proventriculitis with coelomitis. Additionally, lymphoplasmacytic ganglioneuritis in the proventriculus, heart, small intestine, and adrenal gland, as well as lymphoplasmacytic encephalitis, hallmarks of proventricular dilatation disease. Psittaciform 1 bornavirus RNA was confirmed in the brain, proventriculus and ventriculus by RT-PCR. Avian Bornavirus antigen was identified by immunohistochemistry in the brain and heart.

**Key words:** Avian Bornavirus, psittacine birds, proventricular dilatation disease.

## Introduction

Psittaciforme 1 Bornavirus (PaBV) is a single-stranded RNA virus of the Bornaviridae family. Since 2008, has been recognized as the etiological agent of a fatal and important disease of psittacine birds known as proventricular dilatation disease (PDD) (18, 26). Avian Bornaviruses were recently taxonomic rearranged in 4 major species: Psittaciform 1 bornavirus, Passeriform 1 bornavirus, Passeriform 2 bornavirus and Waterbird 1 bornavirus (18). PDD affects several psittacine birds, including amazon and grey parrots, macaws, cockatiels and cockatoos (14, 22, 33). PDD has been reported in various countries, including the United States, Canada, Australia, Japan, South Africa, several European countries (3, 4, 11, 19, 28, 31, 33), and recently in Brazil (5, 7, 25).

Neurotropism is a remarkable feature of PaBV reflected in the histopathological presentation observed in affected birds, characterized by a lymphoplasmacytic encephalomyelitis and ganglioneuritis, particularly prominent in the enteric nervous system (27, 30, 31). PaBV infection can cause neurologic and/or gastrointestinal signs, including lethargy, ataxia, regurgitation, emaciation, and undigested seeds in the feces before finally culminating in death (2, 17, 24).

As the name suggests, the dilation of the proventriculus is the hallmark of PDD, and when present can be observed radiographically (8, 16, 27). Although rare, in some cases the proventricular wall can distend until it ruptures, causing the extravasation of food material into the coelomic cavity (27, 30).

This report describes the clinical, pathological, immunohistochemical and molecular biological findings

from an uncommon case of proventricular rupture associated with natural PaBV infection in a Major Mitchell Cockatoo (*Lophochroa leadbeateri*).

### Case report

A 10-year old female Major Mitchell Cockatoo (*Lophochroa leadbeateri*) was presented to the Texas A&M Zoologic Medicine Service for a 2 day history of weight loss and weakness. The patient was a breeding female, who previously had laid approximately 12 eggs per year but for the last 3-4 months had not produced any eggs.

On clinical evaluation, the patient presented with depression and ataxia, and was not able to appropriately grip the perch in her cage. Signs of dehydration, including sunken eyes, were observed and fecal staining was noted around the vent, indicating diarrhea.

Clinical pathology results indicated a moderate leukocytosis, monocytosis and lymphopenia, and increased enzymatic activity of aspartate aminotransferase (AST) and creatine kinase (CK).

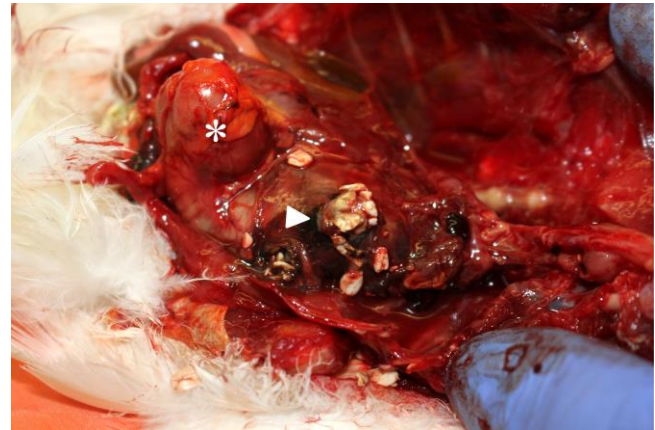Radiograph showed poor serosal detail and distention of the caudal coelomic cavity. Additionally, small intestine loops were distended by gas and an apparent mass effect displaced the intestine dorsally, rightward and cranially, with compression of the air sacs.

The patient was sent home; however, clinical condition worsened and she was presented to the referring veterinarian with respiratory distress, subsequently died, and was referred to Texas A&M pathology service for necropsy.

On necropsy, the proventriculus was markedly dilated with a proventricular to ventricular ratio of 1.5-2:1. On the ventral surface of the proventriculus was a 0.5 cm diameter, transmural perforation with locally extensive hemorrhage and necrosis. Proventricular contents and seeds were adhered to the serosa of intestinal organs and mixed with blood (Fig. 1). Caudal portion of the lungs were covered by proventricular contents and fibrin. A fibrinoncretizing coelomitis, most severely affecting the proventriculus and liver, airsacculitis of the cervicocephalic, cranial thoracic, caudal thoracic, and abdominal air sacs, were also observed. No significant lesions were observed in the remaining organs.

Histologic examination revealed a severe, locally extensive, subacute, transmural necrotizing proventriculitis and a fibrinohemorrhagic coelomitis (Fig. 2A) that involved the proventriculus, liver, heart, great vessels and adrenal glands. Locally extensive, acute, hepatic coagulative necrosis with hemorrhage, intralesional foreign material (seeds) and bacterial colonies obliterated the hepatic parenchyma adjacent to the proventriculus. Multifocal, subacute, lymphoplasmacytic ganglioneuritis was observed, severely affecting the proventricular and ventricular ganglia (Fig. 2), and mild to moderately affecting the ganglia of the heart (Fig. 3A), adrenal gland and small intestine. Within the brainstem was a mild,

multifocal, subacute lymphoplasmacytic encephalitis (Fig. 3B). Additionally, there was a lymphoplasmacytic airsacculitis and parabronchial hemorrhage and presumed secondary to the coelomitis.



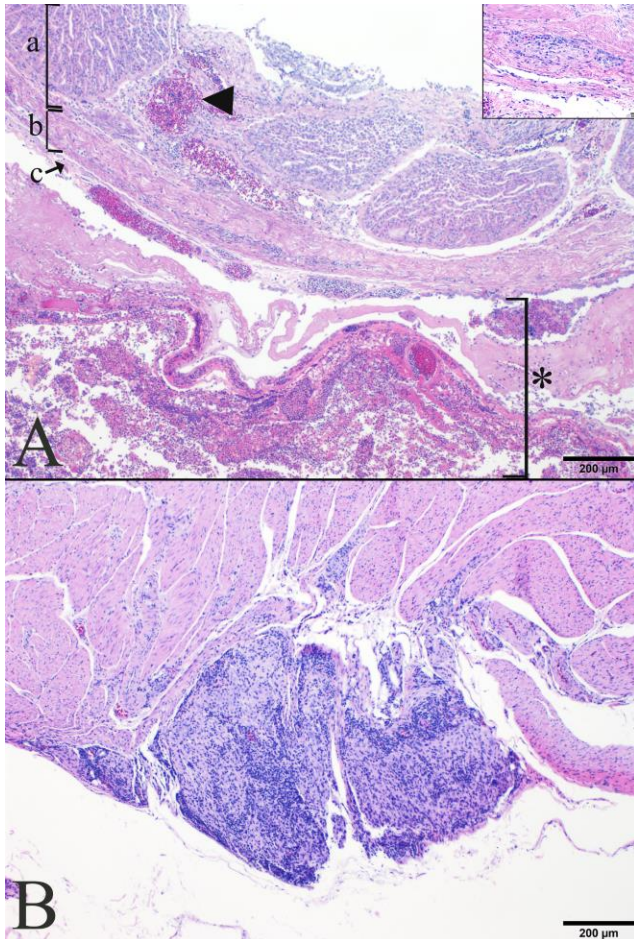
**Figure 1.** Gross Findings. Proventricular perforation and proventricular contents free in the coelomic cavity (arrowhead). An asterisk indicates the position of the ventriculus.

Immunohistochemistry was performed on the heart and brain using a rabbit polyclonal antibody against the PaBV N protein in a 1:1000 concentration, followed by incubation with an anti-mouse/rabbit polymer, and with diaminobenzidine being used as a chromogen. Intranuclear and intracytoplasmic neuronal staining was observed in ganglia of the heart (Fig. 3C) and also in neurons of the brainstem and cerebrum (Fig. 3D).

Additionally, RT-PCR for PaBV detection in fresh tissues was performed as previously described (11). Briefly, viral RNA was extracted from tissues using an RNeasy mini kit (Qiagen, Valencia, CA, USA), following manufacturer's instructions. Viral RNA was reverse transcribed using high capacity cDNA synthesis kit (Applied Biosystems, Foster City, CA, USA) and cDNA was generated using random primers. Finally, PaBV cDNA was amplified using the following primers targeting the M (Matrix) protein gene: PaBV M F (5-GGTAATTGTTCTGGATGG-3) and PaBV M R (5-ACACCAATGTTCCGAAGACG-3). Viral RNA was detected by RT-PCR, in samples from brain, proventriculus and ventriculus. Duck Embryo fibroblasts (DEF) infected with PaBV were used as a positive control.

### Discussion

Although a well-recognized disease, PDD still represents an important threat for psittacine birds in captivity, affects several endangered species (10, 34), and continues to lack any effective treatment. No commercial antiviral drugs have proved to be efficient *in vivo* thus far (20).

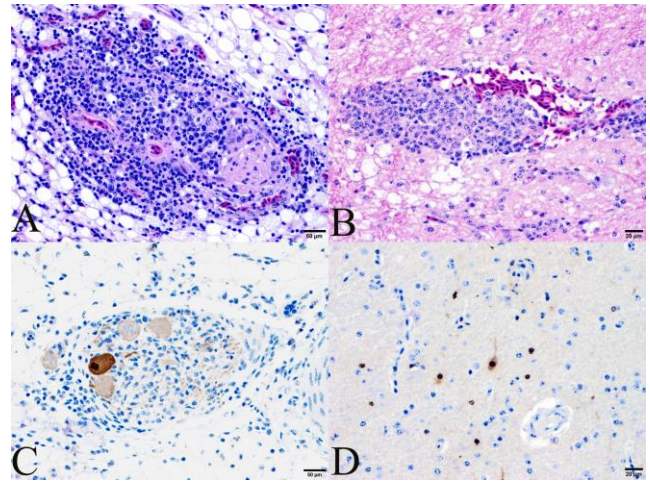


**Figure 2.** Histological findings. (A) Proventriculus. The mucosa, muscularis, and serosa are designated by a, b, and c, respectively. Adhered to the serosa is a thick layer of hemorrhage, necrotic debris, and fibrin (asterisk). Multifocally, within the lamina propria are foci of hemorrhage (arrowhead). Lymphocytes and plasma cells infiltrate a proventricular ganglion (Inset). (H&E stain). (B) Ventriculus. Lymphocytes and plasma cells diffusely infiltrate ganglia located in the serosa and within the muscular layer (H&E stain). Gross Findings. Proventricular perforation and proventricular contents free in the coelomic cavity

Lymphoplasmacytic inflammation in the myenteric ganglia and in the central nervous system (CNS) are the main lesions seen in PDD cases; however, lymphoplasmacytic infiltrates can also be observed in the heart, adrenal gland and spinal cord ganglia as well as in peripheral nerves such as sciatic and vagus nerves (4, 23, 33). Therefore, the organs that must be collected for PDD are brain, spinal cord, crop, heart, proventriculus, ventriculus, intestines, adrenal glands, and peripheral nerves (10, 23, 24). Crop biopsies are usually applied as an antemortem diagnostic tool, due to doable accessibility of this organ, however, the lymphoplasmacytic infiltrates are not as consistent as observed in the proventriculus and

ventriculus, and the absence of ganglioneuritis in a crop biopsy cannot rule out PDD (29).

Proventricular dilatation is a classical sign of PDD but not pathognomonic for PaBV infection. Other infectious conditions such as clostridiosis, gastric mycobacteriosis and fungal gastritis, can also cause proventricular dilatation in psittacine birds and must be included in the differential diagnoses (29). Proventricular dilatation is also commonly observed in cases of lead toxicosis in geese and psittacine birds (21, 27).



**Figure 3.** Histological and immunohistochemical findings. (A) Heart. Lymphoplasmacytic epicardial ganglioneuritis (H&E stain). (B) Brain. Perivascular infiltrate of lymphocytes expand Virchow-Robin's space in brain. There is mild spongiosis of the adjacent neuropil (H&E stain). IHC for PaBV shows intracytoplasmic and intranuclear staining in an isolated neuron of an epicardial ganglion (C) and in several neurons of the cerebrum (D).

Proventricular rupture is not a common event in birds, and when it occurs, it can be caused by physical, infectious, or parasitic etiologies (6, 9, 12, 15, 29). Proventricular impaction and subsequent rupture is more frequently seen in young psittacine birds and usually associated with foreign body ingestion (29). Mycotic proventriculitis caused by *Macrorhabdus ornitogaster* has been associated with proventricular rupture in budgerigars (*Melopsittacus undulatus*) (9) and gray partridges (*Perdix perdix*) (15). In poultry, transmissible viral proventriculitis is implicated to be a major cause of proventricular rupture, causing economic losses from carcass condemnation (12). Parasitic infections caused by spiruroids, such as *Geopetitia aspiculata* can also lead to perforation of the proventricular wall, especially in passerines (6).

Ruptured egg yolk material in the coelomic cavity has been described as a major cause of coelomitis (egg yolk coelomitis) in psittacine birds and ducks (32), and must be ruled out as the primary process in female birds presenting coelomitis.

Macroscopic and microscopic lesions were highly suggestive of PDD, which was confirmed by immunohistochemical and molecular methods. Although PDD has been described in the literature as a possible but rare cause of proventricular rupture (1, 27, 30), no case reports have been published so far to the authors' knowledge. This case represents the first published case of proventricular perforation and coelomitis associated with PDD caused by PaBV, and demonstrates the importance of careful examination of the proventriculus in cases where coelomitis is the major necropsy finding.

## References

1. DAHLHAUSEN R., OROSZ SE. Current understanding of Proventricular Dilatation Disease. **Proceedings of the 29th Annual Conference Avian Medicine and Surgery**. 2008, 15-22.
2. DE KLOET AH., KERSKI A., DE KLOET SR. Diagnosis of Avian bornavirus infection in psittaciformes by serum antibody detection and reverse transcription polymerase chain reaction assay using feather calami. **J. Vet. Diagn. Invest.**, 2011, 23, 3, 421-429.
3. DE KLOET SR., DORRESTEIN GM. Presence of avian bornavirus RNA and anti-avian bornavirus antibodies in apparently healthy macaws. **Avian Dis.**, 2009, 53, 4, 568-573.
4. DELNATTE P., MAK M., OJKIC D., RAGHAV R., DELAY J., SMITH DA. Detection of Avian bornavirus in multiple tissues of infected psittacine birds using real-time reverse transcription polymerase chain reaction. **J. Vet. Diagn. Invest.**, 2014, 26, 2, 266-271.
5. DONATTI RV., RESENDE M., FERREIRA FC., MARQUES MV., ECCO R., SHIVAPRASAD HL., DE RESENDE JS., MARTINS, NR. Fatal proventricular dilatation disease in captive native psittacines in Brazil. **Avian Dis.**, 2014, 58, 1, 187-193.
6. DORRESTEIN GM. Passerines. TULLY TN., DORRESTEIN GM (Eds). Handbook of Avian Medicine. 2 ed. W.B. Saunders, Edinburgh 2009, 169-208.
7. ENCINAS-NAGEL N., ENDERLEIN D., PIEPENBRING A., HERDEN C., HEFFELS-REDMANN U., FELIPPE PA., ARNS C., HAFEZ HM., LIERZ, M. Avian bornavirus in free-ranging psittacine birds, **Brazil Emerg. Infect. Dis.**, 2014, 20, 12, 2103-2106.
8. GANCZ AY., KISTLER AL., GRENINGER AL., FARNOUSHI Y., MECHANI S., PERL S., BERKOWITZ A., PEREZ N., CLUBB S., DERISI JL., GANEM D., LUBLIN, A. Experimental induction of proventricular dilatation disease in cockatiels (*Nymphicus hollandicus*) inoculated with brain homogenates containing avian bornavirus 4. **Virol. J.**, 2009, 6, 100.
9. GERLACH H. Megabacteriosis. **Seminars in Avian and Exotic Pet Medicine**. 2001, 10, 1, 12-19.
10. GRAY P., HOPPES S., SUCHODOLSKI P., MIRHOSSEINI N., PAYNE S., VILLANUEVA I., SHIVAPRASAD HL., HONKAVUORI KS., LIPKIN WI., BRIESE T., REDDY SM., TIZARD I. Use of avian bornavirus isolates to induce proventricular dilatation disease in conures. **Emerg. Infect. Dis.**, 2010, 16, 3, 473-479.
11. GUO J., PAYNE S., ZHANG S., TURNER D., TIZARD I., SUCHODOLSKI P. Avian bornaviruses: diagnosis, isolation, and genotyping. **Curr. Protoc. Microbiol.**, 2014, 34, 151 1 1-151 1 33.
12. GUY JS. Virally induced gastrointestinal diseases of chickens and turkeys. PERRY GC (Ed). **Avian Gut Function in Health and Diseases**. CABI, Wallingford 2007, 227-243.
13. HEFFELS-REDMANN U., ENDERLEIN D., HERZOG S., HERDEN C., PIEPENBRING A., NEUMANN D., MULLER H., CAPELLI S., MULLER H., OBERHAUSER K., GERLACH H., KALETA, EF., LIERZ M. Occurrence of avian bornavirus infection in captive psittacines in various European countries and its association with proventricular dilatation disease. **Avian Pathol.**, 2011, 40, 4, 419-426.
14. HOPPES S., GRAY PL., PAYNE S., SHIVAPRASAD HL., TIZARD I. The isolation, pathogenesis, diagnosis, transmission, and control of avian bornavirus and proventricular dilatation disease. **Vet. Clin. North. Am. Exot. Anim. Pract.**, 2010, 13, 3, 495-508.
15. JANSSON DS., BROJER C., MATTSSON R., FEINSTEIN R., MORNER T., HARD AF., SEGERSTAD C. Mycotic proventriculitis in gray partridges (*Perdix perdix*) on two game bird farms. **J. Zoo Wildl. Med.**, 2008, 39, 3, 428-37.
16. KELLER DL., HONKAVUORI KS., BRIESE T., LIPKIN WI., MUTHUSWAMY A., STEINBERG H., SLADKY KK. Proventricular dilatation disease associated with Avian bornavirus in a scarlet macaw (*Ara macao*). **J. Vet. Diagn. Invest.**, 2010, 22, 6, 961-965.
17. KISTLER AL., SMITH JM., GRENINGER AL., DERISI JL., GANEM D. Analysis of naturally occurring avian bornavirus infection and transmission during an outbreak of proventricular dilatation disease among captive psittacine birds. **J. Virol.**, 2010, 84, 4, 2176-2179.
18. KUHN JH., DURRWALD R., BAO Y., BRIESE T., CARBONE K., CLAWSON AN., DERISI JL., GARTEN W., JAHRLING PB., KOLODZIEJEK, J., RUBBENSTROTH D., SCHWEMMLE M., STENGLEIN M., TOMONAGA K., WEISSENBOCK H., NOWOTNY N. Taxonomic reorganization of the family Bornaviridae. **Arch. Virol.**, 2015, 160, 2, 621-632.

19. LAST RD., WEISSENBOCK H., NEDOROST N., SHIVAPRASAD HL. Avian bornavirus genotype 4 recovered from naturally infected psittacine birds with proventricular dilatation disease in South Africa. **J. S. Afr. Vet. Assoc.**, 2012, 83, 1, 938.
20. MUSSER JM., HEATLEY JJ., KOINIS AV., SUCHODOLSKI PF., GUO J., ESCANDON P., TIZARD IR. Ribavirin Inhibits Parrot Bornavirus 4 Replication in Cell Culture. **PLoS One**, 2015, 10, 7, e0134080.
21. OCHIAI K., JIN K., GORYO M., TSUZUKI T., ITAKURA C. Pathomorphologic findings of lead poisoning in white-fronted geese (*Anser albifrons*). **Vet. Pathol.**, 1993, 30 6, 522-528.
22. OGAWA H., SANADA Y., SANADA N., KUDO M., TUCHIYA K., KODAMA T., UETSUKA K. Proventricular dilatation disease associated with avian bornavirus infection in a Citron-crested Cockatoo that was born and hand-reared in Japan. **J. Vet. Med. Sci.**, 2011, 73, 6, 837-840.
23. OUYANG N., STORTS R., TIAN Y., WIGLE W., VILLANUEVA I., MIRHOSSEINI N., PAYNE S., GRAY P., TIZARD I. Histopathology and the detection of avian bornavirus in the nervous system of birds diagnosed with proventricular dilatation disease. **Avian Pathol.**, 2009, 38, 5, 393-401.
24. PAYNE S., SHIVAPRASAD HL., MIRHOSSEINI N., GRAY P., HOPPES S., WEISSENBOCK H., TIZARD I. Unusual and severe lesions of proventricular dilatation disease in cockatiels (*Nymphicus hollandicus*) acting as healthy carriers of avian bornavirus (ABV) and subsequently infected with a virulent strain of ABV. **Avian Pathol.**, 2011, 40, 1, 15-22.
25. PHILADELPHO NA., RUBBENSTROTH D., GUIMARAES MB., PIANTINO FERREIRA AJ. Survey of bornaviruses in pet psittacines in Brazil reveals a novel parrot bornavirus. **Vet. Microbiol.**, 2014, 174, 3-4, 584-590.
26. PIEPENBRING AK., ENDERLEIN D., HERZOG S., KALETA EF., HEFFELS-REDMANN U., RESSMEYER S., HERDEN C., LIERZ M. Pathogenesis of avian bornavirus in experimentally infected cockatiels. **Emerg. Infect. Dis.**, 2012, 18, 2, 234-241.
27. RINDER M., ACKERMANN A., KEMPF H., KASPERS B., KORBEL R., STAEHELI P. Broad tissue and cell tropism of avian bornavirus in parrots with proventricular dilatation disease. **J. Virol.**, 2009, 83, 11, 5401-5407.
28. SASSA Y., HORIE M., FUJINO K., NISHIURA N., OKAZAK, S., FURUYA T., NAGAI M., OMATSU T., KOJIMA A., MIZUGAMI M., UEDA K., IK H., EBISAWA K., TOMONAGA K., MIZUTANI T. Molecular epidemiology of avian bornavirus from pet birds in Japan. **Virus Genes**, 2013, 47, 1, 173-177.
29. SCHMIDT RE., REAVILL DR., PHALEN DN. Gastrointestinal System and Pancreas. **Pathology of Pet and Aviary Birds**. 2 ed. Wiley, New York 2015, 55-94.
30. STAEHELI P., RINDER M., KASPERS B. Avian bornavirus associated with fatal disease in psittacine birds. **J. Virol.**, 2010, 84, 13, 6269-6275.
31. WEISSENBOCK H., BAKONYI T., SEKULIN K., EHRENSPERGER F., DONELEY RJ., DURRWALD R., HOOP R., ERDELYI K., GAL J., KOLODZIEJEK J., NOWOTNY N. Avian bornaviruses in psittacine birds from Europe and Australia with proventricular dilatation disease. **Emerg. Infect. Dis.**, 2009, 15, 9, 1453-1459.
32. WILSON H., GRAHAM J. Management of egg-related peritonitis in a blue and gold macaw (*Ara ararauna*). **Compendium on Continuing Education for the Practicing Veterinarian**, 2003, 25, 1, 42-47.
33. WUNSCHMANN A., HONKAVUORI K., BRIESE T., LIPKIN WI., SHIVERS J., ARMIEN AG. Antigen tissue distribution of Avian bornavirus (ABV) in psittacine birds with natural spontaneous proventricular dilatation disease and ABV genotype 1 infection. **J. Vet. Diagn. Invest.**, 2011, 23, 4, 716-726.
34. WYSS F., DEB A., WATSON R, HAMMER S. Radiographic measurements for PDD diagnosis in Spix's macaws (*Cyanopsitta spixii*) at Al Wabra Wildlife Preservation (AWWP), Qatar. **Proceedings of the International Conference on Diseases of Zoo and Wild Animals**. 2009. 349-354.