BJVP
Brazilian Journal of Veterinary Pathology
ISSN 1983-0246

**Original full paper**

# Multidrug therapy for muscular dystrophy in a GRMD (Golden Retriever muscular dystrophy) model

Renata A. Fernandes[1], Paula Fratini[1], José L. Nogueira[1], Dilayla K. Abreu[1], David Feder[2], Ana Claudia O. Carreira[3], Maria A. Miglino[1]

[1]Department of Surgery, Faculty of the Veterinary Medicine and Animal Science, Universidade de São Paulo, São Paulo, Brazil.
[2]School of Medicine ABC, Santo Andre, SP, Brazil.
[3]Internal Medicine Department, School of Medicine and Institute of Chemistry, Universidade de São Paulo, São Paulo, SP, Brazil.
*__Corresponding author__: Paula Fratini. Universidade de São Paulo (USP) – Faculdade de Medicina Veterinária e Zootecnia – Departamento de Cirurgia; Av. Prof. Dr. Orlando Marques de Paiva, 87, Cidade Universitária; São Paulo – SP – Brasil. CEP: 05508-270;
Tel.: +55 11 3091 7690; Fax: +55 11 3091 7690; E-mail: fratini@usp.br

Submitted March 22nd 2016, Accepted August 22nd 2016

## Abstract

Golden Retriever muscular dystrophy (GRMD) is a degenerative, progressive and lethal genetic disease, homologous to human Duchenne muscular dystrophy (DMD). For both there is no cure and clinical interventions are limited to treating clinical signs. As potential treatment, we did a pilot study in GRMD and administered a cocktail of frequently used drugs that might work synergistically. Biochemical blood values were investigated and histology and real-time PCR of muscle biopsies were performed. Significant improvements occurred in experimental Golden Retrievers dogs in regard to the levels of alanine aminotransferase, neutrophils, lymphocytes and CK, which began to show values closer to normal ones when compared to control animals, as well as moderate inflammatory infiltrates in the musculature, according to histology. The drug cocktail seemed to work systemically, but did not interfere with the gene defect, thus having potential value for maintaining the health status and preventing the progression of muscular dystrophy in GRMD model.

**Key words:** treatment, disease of dogs, muscle diseases, canine dystrophy.

## Introduction

Duchenne muscular dystrophy (DMD) is a lethal human X chromosome genetic degenerative disease caused by a mutation in the gene encoding the protein dystrophin. Currently, clinical interventions are limited to treating symptoms and there is no cure. There are two common animal models, for this human disease, mdx mice and GRMD (Golden retriever muscular dystrophy) dogs. Although mdx mice are widely used, they show only minimal clinical signs and their lifespan is reduced only by 25% (7, 15). In contrast, GRMD dogs are regarded to better model the situation of human DMD, since the symptoms are much more severe than those in mdx mice. Thus, molecular, histological and clinical studies validated GRMD as an adequate model for understanding the course of human DMD (8, 9, 22). The severity of the dystrophy necessitates the search for drugs that ameliorate symptoms and improve quality of life (2). In particular available drugs with known toxicological profile (3) may be promising (12). As a potential treatment to slow down progression of the disease, we administered a combination of known drugs that could act synergistically. Seven drugs were selected: sildenafil, a drug with cardioprotective effect that may reduce the weakness of the diaphragm muscle and normalize the expression of TNF alpha (6, 18). Ursodeoxycholic acid which may inhibit the action of cytokine NF-kB, an important regulator of muscle regeneration (19); acetylcysteine which has antioxidant function and may also work in that regard; losartan

 All rights reserved 2007.

potassium which is known for cardioprotective effects and decreased fibrosis in mdx mice (4); and mycophenolate mofetil which inhibits T and B lymphocytes responses in tissue inflammation. We aim to identify differences in experimentally treated affected dogs in contrast to controls without treatment with this cocktail.

## Material and methods

Golden Retriever dogs with muscular dystrophy were identified during the neonatal period based on high levels of creatine kinase (CK) in blood tests and clinical signs of the disease (13). When the dogs were four weeks old, PCR genotyping was performed to confirm the clinical findings (10).

Animal experimentation was approved by the Ethics Committee for Animal Use of the School of Veterinary Medicine (CEUA), Universidade de São Paulo, São Paulo, Brazil, (FMVZ-USP) under protocol 1979/2010. The experimental treatments and the required care were administered by the colony veterinarians. The dogs were studied from two to ten months of age onwards.

Male Golden Retrievers with GRMD (n = 6) from the GRMD-Brazil colony were distributed into two groups: a control group (n = 2; dogs C1 and C2), which did not receive any treatment, and an experimental group (n = 4; Dogs E1, E2, E3 and E4), they received the following drugs daily: 5 mg/kg sildenafil (16), 10 mg/kg ursodeoxycholic acid, 40 mg/day acetylcysteine (20), 3.5 mg/kg losartan potassium (1), 10 mg/kg mycophenolate mofetil (12), 13 mg/kg thalidomide (11) and 1.5 mg/kg diltiazem. Blood evaluations were performed before treatment, during the experiments, i.e. on day 95 and after finalizing the treatment on day 216. Muscle samples collected at the same times were analyzed by reverse transcriptase PCR (qRT-PCR), according to Fratini (11). In addition, fragments of the femoral biceps were investigated histologically.

Muscles samples of all investigated animals were fixed in paraformaldehyde 4%, washed in phosphate buffered saline (PBS), dehydrated in a series of increasing ethanol concentrations (70% to 100%), diaphanized in xylene and included in paraffin. Sections 5 µm thick were obtained in an automatic microtome (Leica RM2165, Leica, Germany) and stained with hematoxylin and eosin (HE) and Masson's trichome staining. The morphological characteristics were photographed using photodocumented under a light microscope (Nikon Eclipse E800, Tokyo, Japan).

Serum biochemical analyses of the six individuals of the study included: creatinine, urea, alanine aminotransferase (ALT), creatine kinase (CK), albumin, alkaline phosphatase and total proteins. Mean values were calculated for each dog at the three time points and compared to canine reference values.

Total RNA was isolated from muscle tissues using TRIzol method according to the manufacturer`s instructions. cDNA synthesis and qRT-PCR assays were performed according to (11). The endogenous *Canis familiaris GAPDH* gene (AGTATGATTCTACCCACGGCAAA and CACAACATACTCAGCACCAGCAT) was used for data normalization. The following primers were used to assess mRNA expression: *dystrophin* (TGAACGAGCCCCTTCCTTTC and ACCGGCCAAATGACTTGTCT), *myostatin* (CTGAGACCCGTCAAGACTCC and AGGGATTCAGCCCATCTTCT), *utrophin* (TTTTGATGAATGCTCGTGGA and CAATTTGGGCTCTCTCCTCA), TNFα (CTTCTCGAACCCCAAGTGACAAG and ATCAGCTGGTTGTCTGTCA), *TGF-β* (AGTTAAAAGCGGAGCAGCATGTGG and GATCCTTGCGGAAGTCAATGTAGAGC) and *VEGF* (TTGCTGCTCTACCTCCACCAT and TGTGCTCTCCTCCTGCCATAG).

A dissociation cycle was performed after each run to check for non-specific amplification. All samples were tested in triplicate, and relative expression was calculated by the 2−ΔΔCP method (16).

## Results

Histologically, muscles of experimental animals compared to the controls showed a slightly better organization of muscle fibers, reduction of inflammatory infiltrates and less deposition of connective tissue and necrosis (Fig. 1). Blood values resulted in significant decrease of leukocyte levels as well as CK (Table 1). The expression of the *dystrophin, myostatin, utrophin, TGF-β, TGF-α* and *VEGF* were evaluated by qRT-PCR, but did not show significant differences between experimental and control individuals (data not shown). Clinical changes were not observed in the dogs studied, only biochemical and moderate histological changes were detected.

 All rights reserved 2007.

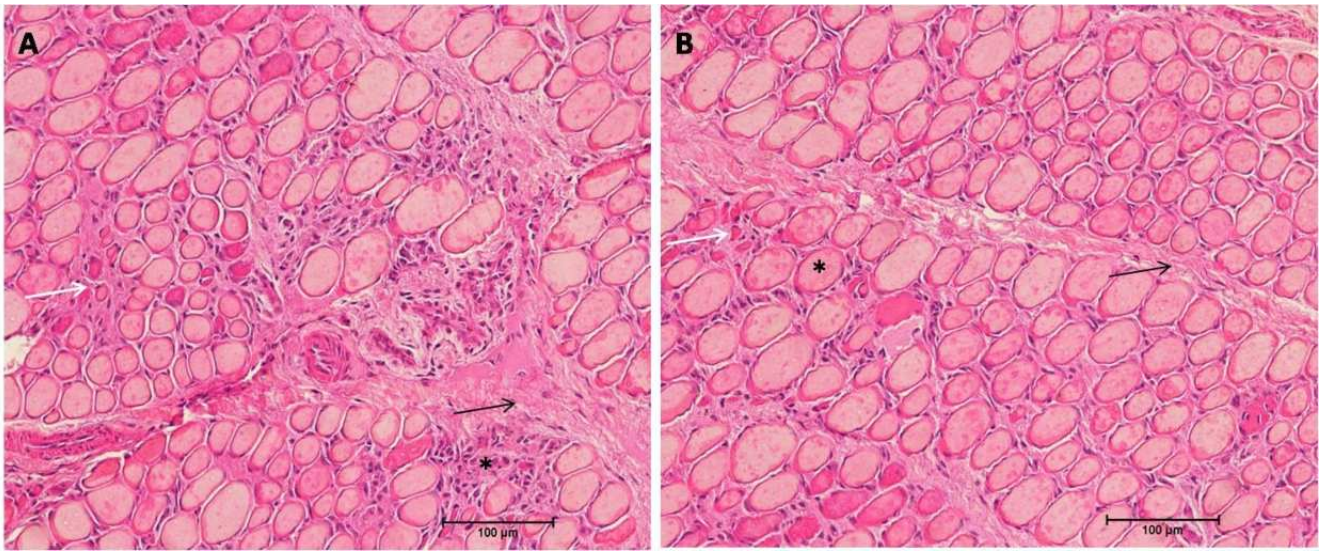


**Figure 1.** Muscle biopsy of the dogs. (A) Biceps femoralis muscle before treatment; there is disorganization of the fibers, perimysial presence of inflammatory infiltrates (black arrow), atrophic fibers (white arrow), fibers in phagocytosis (*). (B) Muscle from a treated dog; there is less perimysial infiltrates (black arrow), fewer atrophic fibers (white arrow), great amount of normal fibers (*), suggesting discrete improvement.

**Table 1.** Hematological and biochemical mean values of the control and experimental groups.

| Parameter (reference value) | Control group mean | Experimental group mean |
|---|---|---|
| Leukocytes (6-15 x $10^3$/$mm^3$) | 18.48 ± 1.43 | 13.97 ± 4.89 |
| Lymphocytes (1.5-5 x $10^3$/$mm^3$) | 6.89 ± 1.3 | 4.97 ± 1.9 |
| Hematocrit (37-54%) | 36.5 ± 2.66 | 30 ± 8.17 |
| Platelets (200-500 x $10^3$) | 675.83 ± 121.15 | 470.80 ± 196.18 |
| Urea (up to 40 mg/dL) | 28.23 ± 4.93 | 43.06 ± 15.91 |
| Creatinine (up to 1.3 mg/dL) | 0.53 ± 0.13 | 0.67 ± 0.2 |
| ALT (up to 50 U/L) | 325.9 ± 68.5 | 240 ± 80.72 |
| Alkaline phosphatase (up to 130 U/L) | 31.63 ± 11.12 | 31.06 ± 7.42 |
| CK (20-200 U/L) | 21.34 ± 8.30 | 11.56 ± 5.15 |
| Albumin (2.5-4.5 g/dL) | 3.03 ± 0.12 | 2.9 ± 0.13 |
| Total protein (5.5-8.0 g/dL) | 6.1 ± 0.21 | 6.1 ± 0.51 |

## Discussion

The drug cocktail seemed to work on a systemic level. Blood values showed that our treatment decreased inflammatory processes by inhibiting the lymphocyte response that is controlled by the pro-inflammatory cytokine TNF alpha. A similar reaction occurred in mdx mice treated with sildenafil only (6, 18). Thus, these drugs may contribute to arrest degenerative processes in dystrophic muscles. Boys suffering from DMD have high ALT values, but without the generally associated hepatic symptoms, indicating that muscular diseases also increase this marker (17). Thus, the decline of ALT in our experimental dogs indicated an improvement of the health status. Likewise this could be assumed for the observed increase of CK, because this enzyme is always highly expressed in muscular diseases and contributed to the diagnosis of muscular lesions (5). We supposed that especially acetylcisteine may be effective in reducing CK values and associated muscular lesions; similar to what is known for mdx mice treated with that drug (21). The above-mentioned improvements were supported by histological findings in our experimental animals that presented slight improvement in their musculature when

compared to controls, although it was not associated with clinical improvement. The relative similar expression of genes relevant for muscular dystrophy indicated that the drug cocktail did not interfere with the gene defect. Nevertheless, our pilot study suggests promising effects on improving animal health status and probably also on arresting the lethal phase of the disease, and thus further, clinically relevant studies seems to be promising.

**Acknowledgements**

We warmly thank our guest professor at USP, Andrea Mess, for helpful comments on a former version of this manuscript.

**References**

1. AMARAL SL., SANCHEZ LS., CHANG AJ., ROSSONI LV., MICHELINI LC. Time course of training-induced microcirculatory changes and of vegf expression in skeletal muscles of spontaneously hypertensive female rats. **Braz. J. Med. Biol. Res.**, 2008, 41, 424-431.
2. ANGELINI C., BONIFATI DM. New therapies in muscular dystrophy. **Neurol. Sci.**, 2000, 21, S919-S924.
3. BERGMAN RL., INZANA KD., MONROE WE., SHELL LG., LIU LA., ENGVALL E., SHELTON GD. Dystrophin-deficient muscular dystrophy in a Labrador Retriever. **J. Am. Anim. Hosp. Assoc.**, 2002, 38, 255-261.
4. BISH LT., SLEEPER MM., FORBES SC., MORINE KJ., REYNOLDS C., SINGLETARY GE. Long-term systemic myostatin inhibition via liver-targeted gene transfer in golden retriever muscular dystrophy. **Hum. Gene Ther.**, 2011, 12, 1499-1509.
5. BUSH BM. **Interpretação de resultados laboratoriais para clínico de pequenos animais**. Roca, São Paulo 2004: 368-372.
6. ADAMO CM., DAI DF., PERCIVAL JM., MINAMI E., WILLIS MS., PATRUCCO E., FROEHNER SC., BEAVO JA. Sildenafil reverses cardiac dysfunction in the mdx mouse model of Duchenne muscular dystrophy. **Proc. Natl. Acad. Sci. U S A**, 2010, 107, 19079-19083.
7. CHAMBERLAIN JS., METZGER J., REYES M., TOWNSEND D., FAULKNER JA. Dystrophin-deficient mdx mice display a reduced life span and resusceptible to spontaneous rhabdomyosarcoma. **FASEB J.**, 2007, 21, 2195-2204.
8. COOPER BJ., GALLAGHER EA., SMITH CA., VALENTINE BA., WINAND NJ. Mosaic expression of dystrophin in carriers of canine X-linked muscular dystrophy. **Lab. Invest.**, 1990, 62, 171-178.
9. COZZI F., CERLETTI M., LUVONI GC., LOMBARDO R., BRAMBILLA PG., FAVERZANI S., BLASEVICH F., CORNELIO F., POZZA O., MORA M. Development of musclepathology in canine X-linked muscular dystrophy. II. Quantitative characterization of histopathological progression during postnatal skeletal muscle development. **Acta Neuropathol.**, 2001, 101, 469-478.
10. DE LUCA A., PIERNO S., LIANTONIO A., CAMERINO DC. Pre-clinical trials in Duchenne dystrophy: what animal models can tell us about potential drug effectiveness. **Neuromuscul. Disord.**, 2002, 12, S142-S146.
11. FRATINI P., CARREIRA ACO., ALCÂNTARA D., SILVA FMO., RODRIGUES MN., MIGLINO MA. Endothelial differentiation of canine yolk sac cells transduced with VEGF. **Res. Vet. Sci.**, 2016, 104, 71-76.
12. ISSAC AJ., NOGUEIRA JL., AMBRÓSIO CE. Diagnóstico molecular por restriction fragment length polymorphism (RFLP) da distrofia muscular em Goldens Retrievers. Simpósio Internacional de Iniciação Científica (SIICUSP), 2011, 19 ed.
13. KORNEGAY JN., BOGAN J., BOGAN DJ., CHILDERS MK., GRANJE R. Golden retriever muscular dystrophy (GRMD): developing and maintaining a colony and physiological functional measurements. **Methods Mol. Biol.**, 2011, 709, 105-123.
14. LEE WS., SUZUKI Y., GRAVES SS., IWATA M., VENKATAKARAMAN GM., MIELCAREK M., PETERSON LJ., IKEHARA S., TOROK-STORB B., STORB R. Canine Bone Marrow Derived Mesenchymal Stromal Cells Suppress Allo-Reactive Lymphocyte Proliferation in Vitro but Fail to Enhance Engraftment in Canine Bone Marrow Transplantation. **Biol. Blood Marrow Transplant.**, 2011, 2, 1-11.
15. LI D., LONG C., YUE Y., DUAN D. Sub-physiological sarcoglycan expression contributes to compensatory muscle protection in mdx mice. **Hum. Mol. Genet.**, 2009, 18, 1209-1220.
16. LIVAK KJ., SCHMITTGEN TD. Analysis of Relative Gene Expression Data Using Real Time Quantitative PCR and the 22DDCT Method. **Methods**, 2001, 25, 402-408.
17. MCMILLAN HJ., GREGAS M., DARRAS BT., KANG PB. Serum transaminase levels in boys with Duchenne and Becker muscular dystrophy. **Pediatrics**, 2010, 127, 132-136.
18. PERCIVAL JM., ADAMS JM., WHITEHEAD NP., FROEHNER LS. Sildenafil reduces respiratory muscle weakness and fibrosis in the mdx mouse model of Duchenne muscular dystrophy. **J. Pathol.**, 2012, 228, 77-87.
19. PETERSON JM., GUTTRIDGE DC. Skeletal muscle diseases, inflammation, and NF-kappaB signaling: insights and opportunities for therapeutic intervention. **Int. Rev. Immunol.**, 2008, 27, 375-387.
20. TEO SK., EVANS MG., BROCKMAN MJ., EHRHART J., MORGAN JM., STIRLING DI.,

THOMAS SD. Safety Profile of Thalidomide after 53 Weeks of Oral Administration in Beagle Dogs. **Toxicol. Sci.**, 2001, 59, 160-168.

21. TERRIL JR., RADLEY-CRABB HG., GROUNDS MD., ARTHUR PG. N-Acetylcysteine treatment of dystrophic mdx mice results in protein thiol modifications and inhibition of exercise induced myofibre necrosis. **Neuromuscul. Disord.**, 2012, 22, 427-434.
22. VALENTINE BA., BLUE JT., SHELLEY SM., COOPER BJ. Increased serum alanine aminotransferase activity associated with muscle necrosis in the dog. **J. Vet. Intern. Med.**, 1990, 4, 140-143.

 All rights reserved 2007.