BJVP
Brazilian Journal of Veterinary Pathology
ISSN 1983-0246

Case Report

Congenital biliary atresia in a Beefmaster calf

Johnatan A. Ruíz-Ramírez[1], Luis J. García-Márquez[2]*, Mario A. Bedolla-Alva[1], Gerardo Salas-Garrido[1], Rafael Ramírez-Romero[3], Julio Martínez-Burnes[4], Alfonso López-Mayagoitia[5]

[1]Departamento de Patología. Facultad de Medicina Veterinaria y Zootecnia, Universidad Nacional Autónoma de México, Avenida Universidad 3000, Ciudad Universitaria, Delegación Coyoacán, Ciudad de México., 04510, Mexico.
[2]Centro Universitario de Investigación y Desarrollo Agropecuario (CUIDA), Facultad de Medicina Veterinaria y Zootecnia, Universidad de Colima, Carretera Colima-Manzanillo Km 40. Colonia: La Estación. CP. 28100 Tecomán, Colima, Mexico.
[3]Facultad de Medicina Veterinaria y Zootecnia de la Universidad Autónoma de Nuevo León. Francisco Villa S/N, Colonia: Ex Hacienda el Canadá, Escobedo, Nuevo León, Mexico.
[4]Facultad de MedicinaVeterinaria y Zootecnia "Dr. Norberto Treviño Zapata". Carretera Mante Km5. Ciudad Victoria, Tamaulipas, México.
[5]Department of Pathology and Microbiology Atlantic Veterinary College. University of Prince Edward Island, Charlottetown, PEI. Canada C1A 4P3.
* **Corresponding author:** Dr. Luis Jorge García Márquez; E-mail: ljgm_cmv@hotmail.com

Submitted May 21st 2016, Accepted August 16th 2016

Abstract

Biliary atresia is a congenital cholangiopathy characterized by a progressive fibrosis of the bile ducts leading to impaired biliary flow, hepatic failure, icterus and early death. This paper describes the gross and microscopic findings in a 4-week-old Beefmaster calf that unexpectedly died with severe jaundice. On postmortem examination, the liver was firm in texture and exhibited an orange-yellow discoloration. Microscopically, there were cholestasis, hyperplasia, fibrosis and obliteration of the bile ducts, and mural fibrosis of the gall-bladder. Masson's trichrome and Gomori's stain revealed excessive collagen deposition in the portal areas and biliary ducts, and occasionally around central veins. Immunohistochemistry confirmed biliary epithelial cells, not only lining the bile ducts but also were forming tubular-like structures devoid of a lumen. Blood test was negative for babesiosis and anaplasmosis. Based on these findings, the final diagnosis was congenital biliary atresia.

Key words: biliary atresia, congenital, jaundice, portal fibrosis, Beefmaster calf.

Introduction

Biliary atresia is a congenital cholangiopathy characterized by progressive fibrosing obliteration and disconnection of the bile ducts leading to impaired biliary flow and jaundice (1, 3, 5). In human neonatology, biliary atresia is the leading cause of cholestasis with an estimated incidence of 1 in 8,000-18,000 live births (3). Clinically, this congenital condition leads to hepatic failure, jaundice, acholic stools, and dark urine that ultimately culminates in premature death during the first few months of life (1-3, 5). According to some pediatric reports, biliary atresia is the most frequent reason for liver transplantation in children and without intervention, death ensues within the first few months or years of life (1, 5).

In veterinary medicine, congenital biliary atresia is particularly rare with only a few cases reported worldwide, most of them in Australia and to a much lesser extent Europe and United Sates (7, 9, 19, 22, 24, 25). This condition is most frequently reported in lambs, foals, calves, puppies, kittens and primates (4, 7, 9, 10, 19, 22, 25). The pathogenesis is still under investigation, but genetic, infectious and toxic factors are suggested as probable causes (12-14). The viral pathogenesis gained momentum when a multi-national pediatric study reported a possible link between biliary atresia and group C rotavirus, but conclusive validation is awaiting (18). In veterinary medicine, a toxic etiology was strongly suggested as the underlying mechanism when an outbreak of biliary atresia affected over 300 lambs and 7 calves in a

relatively short time (10). This outbreak was associated with a toxic plant and prompted researchers to propose lambs as an animal model for biliary atresia (11). There is also mounting evidence that a genetic defect may also be involved in ductal plate malformations (6, 17, 21, 23). In calves, the pathogenesis of biliary atresia remains unknown and at the same time, detailed description of hepatic lesions are scarce. In fact, biliary atresia is well recognized in the veterinary literature, but standard textbooks of veterinary pathology barely describe this condition (4).

The objective of this paper is to describe the gross and microscopic findings in a Beefmaster calf diagnosed with congenital biliary atresia.

Case report

A 4-week-old female Beefmaster calf was found dead on a cattle ranch located in the municipality of Tecomán, Colima, Mexico. According to the owner, this calf did not exhibit clinical signs before death, and at that time, there were 45 cows, one bull and 30 calves on the farm. The carcass was promptly submitted to the Diagnostic Laboratory, Faculty of Veterinary Medicine of the University of Colima for a post-mortem examination.

Externally, the calf did not show any significant abnormalities except for a conspicuous yellow discoloration of the oral, vulvar and conjunctival mucosae. Internally, the calf was found in good body condition with adequate body fat and muscle mass. Intense yellow discoloration was also noted in many tissues including mucosal membranes, fascial planes, thoracic and abdominal serosas, and adipose tissue (Fig. 1). The liver was notably enlarged with rounded borders and filling over 40% of the abdominal cavity (Fig. 1). Externally, the liver surface was smooth and unremarkable (Fig. 2). On cut surface, the hepatic parenchyma was conspicuously yellow-orange in color and had a hard texture on palpation (Fig. 3). The gallbladder and bile ducts were unusually small, and on further dissection, revealed a thick, viscous green fluid oozing from these structures (Fig. 2). Blood was collected from the heart and submitted for hemoprotozoal examination. Samples of various organs were fixed in 10% buffered formalin for histopathology and immunohistochemistry (IHC).

Fixed tissues processed and embedded in paraffin were cut at 4-5 µm and stained with Hematoxylin-Eosin. Also, liver and gallbladder were stained with Masson's trichrome for connective tissue, Hall's stain for bile, and Gomori's for reticulin fibers. For IHC, tissues were cut at 4-5 µm, placed on positive-charged glass slides, and stained using the avidin-biotin-peroxidase method and monoclonal antibodies for cytokeratin: clon AE-1/AE-3 (Dako, Carpinteria, California).

Microscopic lesions were restricted to the liver. The hepatic parenchyma showed an enhanced lobular pattern due to generalized hypercellularity within the portal areas (Fig. 4). Masson's trichrome and Gomori stain revealed excessive collagen deposition in the portal areas and biliary ducts, and occasionally around central veins (Fig. 4). Variable numbers of macrophages, lymphocytes, and plasma cells were infiltrating the portal and periportal connective tissue (Fig. 5).

The biliary ducts were expanded and lined by hyperplastic biliary epithelium and occasionally containing stagnated bile (Figs. 6 and 7).The use of IHC also revealed a notable proliferation of the bile ducts, many of which were hyperplastic, and bridging into the neighboring portal triads (Fig. 8). The IHC-positive cells not only lined the ducts but also were forming tubular-like structures devoid of a lumen (Fig. 8).

Overall, the cytoplasm of hepatocytes appeared pale, slightly vacuolated and sporadically contained bile pigment (Fig. 9). In some areas of the hepatic parenchyma, there were small groups of hepatocytes with intensely eosinophilic cytoplasm, and pycnotic and karyorrhectic nuclei (necrosis). Many bile canaliculi were distended with olive-green, Hall-positive, material consistent with bile (cholestasis) (Fig. 9). Gomori stain revealed a network of reticulin fibers and further highlighted the portal to portal bridging fibrosis (Fig. 10). The gallbladder wall was thickened, and Masson's trichrome staining confirmed that this thickening was mainly due to segmental deposition of collagen fibers (Figs. 11 and 12).

Discussion

Generalized malaise and acholic feces are characteristic signs that precede death in humans and animals with biliary atresia (5, 10), yet none of these two clinical manifestations apparently were evident in this calf. Although a subclinical presentation is conceivable, it is more reasonable to assume, given the degree of jaundice, a lack of close observation by the farmer. Clinical examination by a veterinarian and laboratory tests, particularly blood chemistry, would have undoubtedly yielded valuable information in this case (8, 22). Nonetheless, blood smears taken at the time of the necropsy were negative for babesiosis and anaplasmosis, two conditions commonly associated with bovine jaundice in Mexico. Pale or acholic feces are an early red flag for biliary atresia, and a color-stool card has been made available in pediatric medicine to evaluate the degree of bile obstruction in infants (2). Farmers, pet owners, and veterinary practitioners should routinely assess the color of feces for an early detection of biliary atresia in the live animal. Unlike pediatric cases, surgical intervention to correct biliary atresia would be unrealistic in farm animals (8).

Gross and microscopic changes were typical of biliary atresia (7, 20), which also explain why this calf was so severely icteric. Biliary atresia falls into two morphologic types based on the location where the impairment of bile flow occurs in the hepatobiliary system

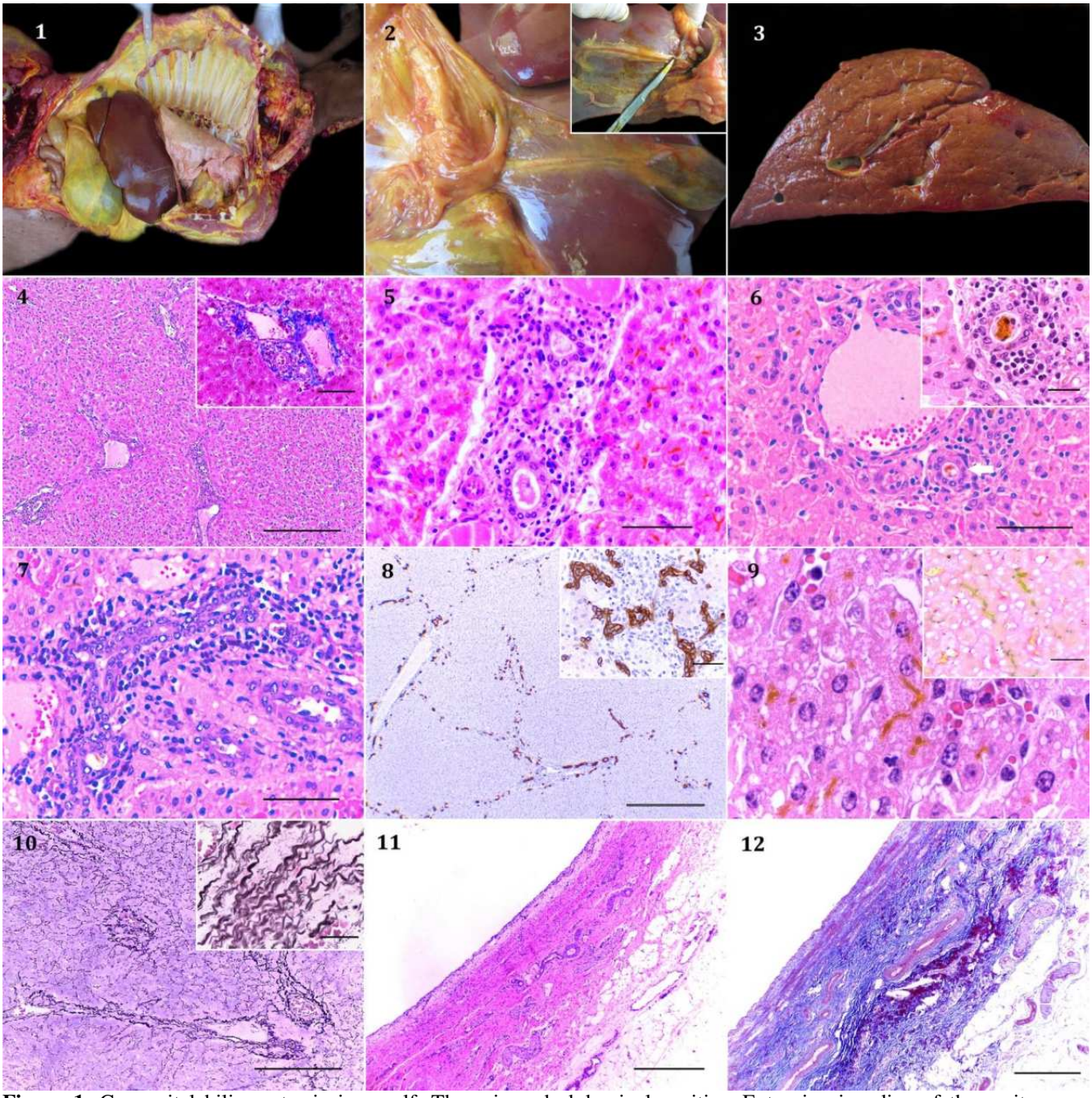

Figure 1. Congenital biliary atresia in a calf. Thoracic and abdominal cavities. Extensive jaundice of the peritoneum, pericardium and parietal pleura. Also, note enlarged liver occupying 40% of the abdominal cavity.
Figure 2. Liver and gall bladder. Biliary ducts (cysticus and choledocus) emptying into the small intestine. Also, note rounded borders of the lobes and smooth hepatic capsule. Inset: Note reduced size of the cysticus and choledocus ducts.
Figure 3. Liver. Cut surface showing slight yellow-orange discoloration of the hepatic parenchyma.
Figure 4. Liver. Note enhanced lobular pattern resulting from hypercellularity and fibrosis of the portal areas. Hematoxylin and eosin. Bar = 500 µm. Inset: Abundant collagen fibers in the portal area. Masson's trichrome. Bar = 50 µm.
Figure 5. Liver. Cluster of lymphocytes and plasma cells in the portal area. Hematoxylin and eosin. Bar= 50 µm.
Figure 6. Liver. Bile pigment in biliary duct (arrow). Hematoxylin and eosin. Bar = 50 µm. Inset: Close-up view of biliary duct. Bar = 25 µm.
Figure 7. Liver. Severe biliary hyperplasia with occlusion of the lumen. Also, few aggregates of lymphocytes in the periportal area. Hematoxylin and eosin. Bar = 50 µm.

Figure 8. Liver. Note the branching and bridging positive for cytokeratin. Immunostaining for cytokeratin AE-1/AE-3. Bar = 500 µm. Inset: Cluster of cells immune-positive for biliary epithelium. There is no evidence of lumen in this cluster of biliary cells. Bar = 50 µm.
Figure 9. Liver. Notable distention of the canaliculi with bile (cholestasis). Hematoxylin and eosin. Bar = 25 µm. Inset: Hall stain; bile plugs in canaliculi. Bar = 25 µm.
Figure 10. Liver. Note the branching and bridging of thin reticulin fibers following biliary epithelium. Gomori stain. Bar = 200 µm. Inset: Close-up view. Bar = 50 µm.
Figure 11. Gall bladder. Segmental thickening of the wall of the bladder. Hematoxylin and eosin. Bar = 200 µm.
Figure 12. Gall bladder. Segmental thickening of the wall of the bladder. Note abundant plaques of collagenous tissue along the wall. Masson's trichrome stain. Bar = 200 µm.

(3, 7, 8). In intrahepatic atresia, the obstruction centers in the intrahepatic bile ducts, while in extrahepatic atresia, the atresic lesions occur first and foremost in the main bile ducts that drain into the small intestine (8). In many cases, however, atretic lesions are simultaneously present in intrahepatic and extrahepatic ducts (5, 16, 19). The gross and microscopic findings in this Beefmaster calf shared similarities with both morphologic types. However, the fibrosis of the gallbladder and the narrowing of the main biliary ducts that anastomose into the cystic duct and ductus choleducus were most consistent with extrahepatic biliary atresia (8).

In reviewing veterinary cases of biliary atresia, evidence emerged that there is a wide-ranging assortment of microscopic changes that often make the final diagnosis challenging, especially because some lesions also occur in other congenital hepatic diseases (15, 26). For instances, congenital hepatic fibrosis, a distinct entity in humans and animals including calves, also manifests itself with hepatomegaly and portal or bridging fibrosis, but unlike biliary atresia, the bile flow is not obstructed and therefore jaundice is not seen in affected calves (26). For this main reason, congenital hepatic fibrosis was ruled-out from the differential diagnosis in the calf reported here. Besides jaundice, the calf also had unequivocal evidence of ductal biliary hyperplasia and fibrosis, two microscopic changes remarkably heightened by IHC and Masson's trichrome stain respectively.

It was impossible to ascertain or even speculate as to what could have been the underlying cause of biliary atresia in this calf. Realistically, the proposed triad of viral, genetic and toxic causes cannot be substantiated in most cases of human and animal biliary atresia (13). In all likelihood, there is not a single specific etiology for bovine biliary atresia, but rather a multifactorial etiology that translate into malformation of ductal plaque during embryogenesis (6, 17, 21).

References

1. BASSETT MD., MURRAY KF. Biliary atresia: recent progress. **J. Clin. Gastroenterol.**, 2008, 42, 720-729.
2. CHENG-HUI H., MEI-HWEI C., HUEY-LING C., HUNG-CHANG L., TZEE-CHUNG W., CHIEH-CHUNG L., YAO-JONG Y., AN-CHYI C., MAO-MENG T., BENG-HUAT L., CHIA-HSIANG C., MING-WEI L. Universal screening for biliary atresia using an infant stool color card in Taiwan. **Hepatology**, 2008, 47, 1233-1240.
3. CHUNG-DAVIDSON YW., YEH CY., LI WM. The sea lamprey as an etiological model for biliary atresia. **Biomed Res. Int.,** 2015, ID 832943, 17 p.
4. CULLEN MJ., STALKER JM. Liver and biliary system: extrahepatic biliary anomalies. MAXIE MG. (Ed), **Jubb, Kennedy, and Palmer's Pathology of domestic animals**. 6 ed., vol. 2. Elsevier, St. Louis, Missouri, 2016, 265-266.
5. DAVENPORT M. Biliary atresia: clinical aspects. **Sem. Pediatr. Surg.**, 2012, 21, 175-184.
6. DESMET VJ. Pathogenesis of ductal plate abnormalities. **Mayo Clin. Proc.**, 1998, 73, 80-89.
7. FRANKEN P., VAN DEN INGH TSGAM., KÖNIG CDW., WOUDA W. Biliary atresia in a Texelaar lamb: a case report. **Zentralblatt für Veterinär Medizin.**, 1981, 28, 276-281.
8. GUPTA L., GUPTA SD., BHATNAGAR V. Extrahepatic biliary atresia: correlation of histopathology and liver function tests with surgical outcomes. **J. Indian Assoc. Pediatr. Surg.**, 2012, 17, 147-52.
9. HAMPSON ECGM., FILIPPICH LJ., KELLY WR., EVANS K. Congenital biliary atresia in a cat: a case report. **J. Small Anim. Pract.**, 1987, 28, 39-48.
10. HARPER P., PLANT JW., UNGER DB. Congenital biliary atresia and jaundice in lambs and calves. **Aust. Vet. J.**, 1990, 67, 18-22.
11. JACKSON A. Livestock outbreak helps to unlock liver condition.**Aust. Vet. J.**, 2015, 93, 21.
12. LORENT K., GONG W., KOO KA., WAISBOURD-ZINMAN O., KARJOO S., ZHAO X., SEALY I., KETTLEBOROUGH RN., STEMPLE DL., WINDSOR PA., WHITTAKER SJ., PORTER JR., WELLS RG., PACK M. Identification of a plant isoflavonoid that causes biliary atresia. **Sci. Transl. Med.**, 2015, 7, 286ra67.
13. MIETHKE AG., HUPPERT SS. Fishing for biliary atresia susceptibility genes. **Gastroenterology**, 2013, 144, 878-881.
14. MOREIRA RK., CABRAL R., COWLES RA., LOBRITTO SJ. Biliary atresia: a multidisciplinary

approach to diagnosis and management. **Arch. Pathol. Lab. Med.**, 2012, 136, 746-760.

15. NAKANUMA Y., HARADA K., SATO Y., IKEDA H. Recent progress in the etiopathogenesis of pediatric biliary disease, particularly Caroli's disease with congenital hepatic fibrosis and biliary atresia. **Histol. Histopathol.**, 2010, 25, 223-235.
16. PETERSEN C., DAVENPORT M. Aetiology of biliary atresia: what is actually known? **Orphanet J. Rare Dis.**, 2013, 8, 128.
17. PILLAI S., CENTER SA., MCDONOUGH SP., DEMARCO J., PINTAR J., HENDERSON AK., COOPER J., BOLTON T., SHARPE K., HILL S., BENEDICT AG., HAVILAND R. Ductal plate malformation in the liver of Boxer dogs: clinical and histological features. **Vet. Pathol.**, 2016, 53, 602-613.
18. RIEPENHOFF-TALTY M., GOUVEA V., EVANS MJ., SVENSSON L., HOFFENBERG E., SOKOL RJ., UHNOO I., GREENBERG SJ., SCHÄKEL K., ZHAORI G., FITZGERALD J., CHONG S., EL-YOUSEF M., NEMETH A., BROWN M., PICCOLI D., HYAMS J., RUFFIN D., ROSSI T. Detection of group C rotavirus in infants with extrahepatic biliary atresia. **J. Infect. Dis.**, 1996, 174, 8-15.
19. ROSENBERG DP., MORECKI R., LOLLINI LO., GLASER J., CORNELIUS CE. Extrahepatic biliary atresia in a Rhesus monkey (*Macaca mulatta*). **Hepatology**, 1983, 3, 577-580.
20. ROY P., CHATTERJEE U., GANGULI M., BANERJEE S., CHATTERJEE SK., BASU AK. A histopathological study of liver and biliary remnants with clinical outcome in cases of extrahepatic biliary atresia. **Indian J. Pathol. Microbiol.**, 2010, 53, 101-105.
21. SAFWAN M., RAMACHANDRAN P., VIJ M., SHANMUGAM N., RELA M. Impact of ductal plate malformation on survival with native liver in children with biliary atresia. **Pediatr. Surg. Int.**, 2015, 31, 837-843.
22. SCHULZE C., ROTHUIZEN J., VAN SLUIJS FJ., HAZEWINKEL HA., VAN DEN INGH TS. Extrahepatic biliary atresia in a border collie. **J. Small Anim. Pract.**, 2000, 41, 27-30.
23. SHIMADERA S., IWAI N., DEGUCHI E., KIMURA O., FUMINO S., YOKOYAMA T. The inv mouse as an experimental model of biliary atresia. **J. Pediatr. Surg.**, 2007, 42, 1555-1560.
24. THIEL C., STEINBACH S., SCHMIDT M., AMORT K., ZAHN N., KRAMER M., MORITZ A. Extrahepatic biliary atresia in a 4-week-old Pug. **Vet. Surg.**, 2015, 44, 35-40.
25. VAN DER LUER RJT., KRONEMAN J. Biliary atresia in a foal. **Equine Vet. J.**, 1982, 14, 91-93.
26. YOSHIKAWA H., FUKUDA T., OYAMADA T. Congenital hepatic fibrosis in a newborn calf. **Vet. Pathol.**, 2002,39, 143-145.