



Case Report

Granulomatous leptomeningitis in a goat associated with infection by *Cryptococcus neoformans*

Fábio B. Rosa¹, Mara I. B. Rubin¹, Roberio G. Olinda², Paula V. Leal³, Stephanie C. Lima³,
Rayane C. Pupin³, Danilo C. Gomes³, Ricardo A. A. Lemos³, Tessie B. Martins³,
Aline Rodrigues-Hoffmann⁴, Claudio S. L. Barros^{3*}

¹Programa de Pós-Graduação em Medicina Veterinária, Centro de Ciências Rurais (CCR), Universidade Federal de Santa Maria (UFSM), Camobi, Santa Maria, RS 97105-900, Brazil.

²Laboratório de Patologia Animal, Hospital Veterinário, CSTR, Campus de Patos, Universidade Federal de Campina Grande Patos, PB, Brazil.

³Laboratório de Anatomia Patológica - Faculdade de Medicina Veterinária e Zootecnia (FAMEZ), Universidade Federal de Mato Grosso do Sul (UFMS), Av. Senador Filinto Müller 2443, Campo Grande, MS 79074-460, Brazil.

⁴Department of Veterinary Pathobiology, Texas A&M University, TX, USA.

*Corresponding author: Universidade Federal de Mato Grosso do Sul (UFMS), Av. Senador Filinto Müller 2443, Campo Grande, MS 79074-460, Brazil.
E-mail: claudioslbarros@uol.com.br

Submitted June 4th 2016, Accepted July 11th 2016

Abstract

A case of granulomatous leptomeningitis caused by *Cryptococcus neoformans* is described in a 2-year-old mixed-breed, female goat which presented acute neurological signs including ataxia, nystagmus, bilateral blindness, opisthotonus, hyperesthesia, and spastic paresis of forelimbs. Granulomatous inflammation was detected in the pia arachnoid covering the frontal, parietal and occipital lobes of the telencephalon; cerebellum, thalamus, mesencephalon, pons, medulla, and cervical and thoracolumbar segments of the spinal cord. Yeast-like organisms with morphology compatible with *Cryptococcus* spp. were observed. A 350 base pair sequence was amplified from DNA extracted from the formalin fixed paraffin embedded (FFPE) tissue. The amplified sequence matched 100% *Cryptococcus neoformans*. It is suggested that cryptococcal meningitis should be included in the differential diagnosis list of goat diseases with neurological signs such as ataxia, opisthotonus, nystagmus, hyperesthesia and spastic paresis.

Key words: goat diseases, central nervous system, leptomeningitis, mycosis, *Cryptococcus neoformans*.

Introduction

Cryptococcosis is a systemic mycosis more frequently found in cats and to a lesser extent in dogs (12). The disease is less frequently reported in several other animal species including horses (9, 11), cattle (16), sheep (13), goats (18, 19), and human beings (4).

Infection occurs when cryptococcal spores are inhaled and enter the alveolar lumina. In most, but not all, immunocompetent individuals, this infection either is cleared or remains dormant until an immune compromise leads the development of lesions induced by the yeast (2). When affecting individual with already compromised

immune system, the organism disseminates with particular tropism for the central nervous system (18).

Although affecting both human beings and animals, cryptococcosis is considered neither a zoonosis, nor an anthroozoonosis since the organisms cannot disseminated in the environment from tissue lesions neither of animals nor human beings (7).

Cryptococcosis is caused by two fungal species: (a) *Cryptococcus neoformans*, with the varieties *grubii* (serotype A) and *neoformans* (serotype D) and (b) *Cryptococcus gattii* (3). *C. neoformans* is commonly isolated from avian excreta particularly that of pigeons, occurs worldwide, and primarily cause disease in

immunocompromised patients (3). *C. gattii* primarily affects otherwise healthy individuals. Typically *Cryptococcus* spp. entry the body through the respiratory system, by the inhalation of infectious spores. In human beings, the agent can cause symptomatic or asymptomatic pulmonary infection followed by invasion of the central nervous system via the blood (16). Although both species of *Cryptococcus* may infect the central nervous system, *C. gattii* appears to do that more frequently than *C. neoformans* (3). The infection can disseminate to affect other organs causing cutaneous manifestations, osteomyelitis, septic arthritis, chorioretinitis, myocarditis, hepatitis, peritonitis, renal abscesses, prostatitis, myositis, mastitis and gastroenteritis (16).

C. neoformans has a worldwide distribution. It is isolated frequently from the droppings of birds, especially pigeons (1). *C. gattii* has not been isolated from bird droppings. Plant debris (especially *Eucalyptus* spp. but also from other plants) seems to be the natural reservoir for *C. gattii* (6). The report describes a case of caprine cryptococcal meningoencephalitis caused by *C. neoformans*.

Case report

A 2-year-old mixed-breed, female goat was presented to the Anatomic Pathology Laboratory (LAP) of the FAMEZ/UFMS with neurological signs of one-day duration that included ataxia, nystagmus, bilateral blindness, opisthotonus (Fig. 1), hyperesthesia, and spastic paresis of thoracic members. The goat was from a farm in the municipality of Bandeirantes (19°55'04" S / 54°21'50" W), in the central part of the state of Mato Grosso do Sul, Midwestern Brazil. The goat was part of a herd of 1,500 goats most of which were originally raised in the State of Bahia in the Northeastern Brazil, and then transported from there into the Bandeirantes farm in two occasions. The first movement of goats from Bahia to the Bandeirantes was in 2013 and the other on July 2014, the same time frame in which this case occurred. However the owner was unable to inform to which of those two lots this affected goat belonged. By the time the goat got sick, the farm in Bandeirantes was going through a long series of sanitary and husbandry problems such as, parasitism (haemonchosis), caseous lymphadenitis, and type D enterotoxaemia. These ailments claimed heavy losses in the heard.

The goat was euthanized for humanitarian reasons and necropsied on the same day of arrival at the APS. At necropsy, it was in good body conditions with well-preserved fat deposits. The leptomeninges of the brain and some segments of the spinal cord were mildly edematous, thicken and slightly opaque.

Several tissue samples (including the whole brain and spinal cord) were fixed in 10% formalin solution, processed routinely for histopathological examination, and stained with hematoxylin and eosin (HE). Sections from

several regions of the central nervous system (CNS) were additionally stained with Mayer's mucicarmine, Grocott's methenamine silver, periodic acid-Schiff (PAS), Alcian blue and Fontana Masson stains. Fresh samples from the encephalon were submitted to FA technique for rabies, and to the biological assay for rabies detection (intracerebral inoculation in neonate mice); both tests resulted negative.

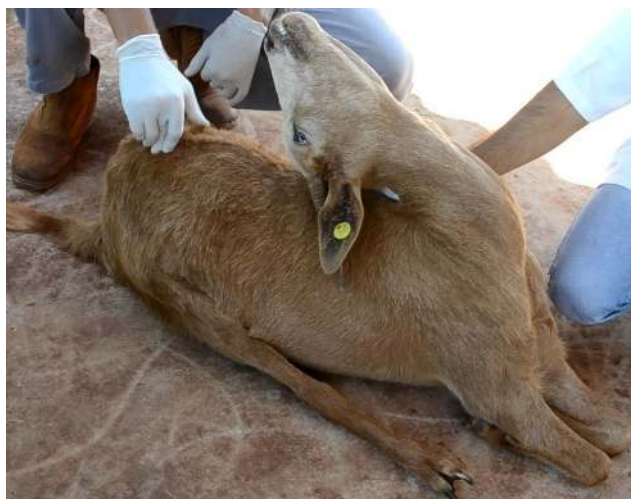

Figure 1. Goat. Opisthotonus associated with granulomatous leptomeningitis by *Cryptococcus neoformans*.

Microscopic lesions were observed in the leptomeninges covering the frontal, parietal and occipital lobes of the telencephalon, thalamus, mesencephalon, pons, medulla, and cervical and thoracolumbar segments of the spinal cord. In these regions, the leptomeninges displayed moderate inflammatory reaction consisting of macrophages, few multinuclear giant cells, lymphocytes, and plasma cells (Fig. 2). Numerous ovoid to spherical, thick-walled, yeast-like structures were observed amidst the cellular reaction and occasionally within the cytoplasm of macrophages (Fig. 3). These organisms measured 5-20 µm in diameter, occasionally had a single, narrow base budding and abundant non-staining capsular material corresponding to a clear halo surrounding the organisms which lends a "soap bubble" appearance to the lesion (Fig. 2).

The capsules stained positively with Alcian Blue (Fig. 4), Mayer's mucicarmine, and PAS. The wall of the yeast-like organisms stained strongly with Grocott's and Fontana Masson stains.

Fifty micrometers scrolls from a formalin fixed paraffin embedded (FFPE) tissue block were used for DNA extraction and polymerase chain reaction (PCR), as previously described (14). DNA was extracted and isolated from FFPE tissues using the BiOstic FFPE Tissue DNA isolation kit (MoBio Laboratories, Carlsbad, CA). PCR was performed using ITS3 (5'-GCATCGATGAAGAACGCAGC-3') and ITS4 (5'-

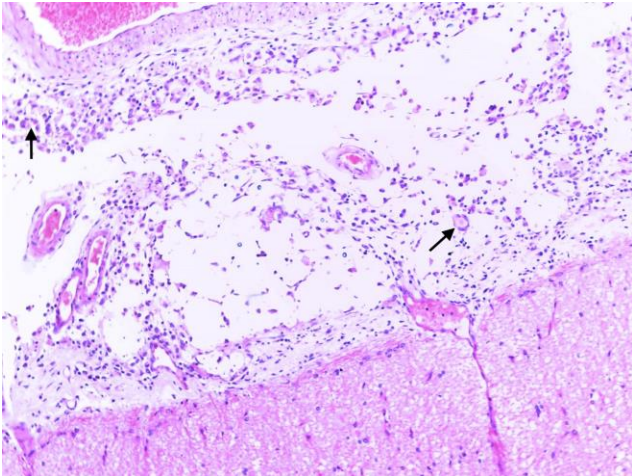


Figure 2. Goat. Leptomeninges. Cerebral cortex. Granulomatous leptomeningitis by *Cryptococcus neoformans*. Leptomeninges display moderate inflammatory reaction consisting of macrophages, lymphocytes, plasma cells, and multinucleated giant cells (arrows). Numerous, ovoid to spherical, 5-20 µm in diameter thick-walled, yeast-like structures are observed amidst the cellular reaction (HE stain). The abundant non-staining capsular material corresponds to clear halo surrounding the organism which lends a “soap bubble” appearance to the lesion.

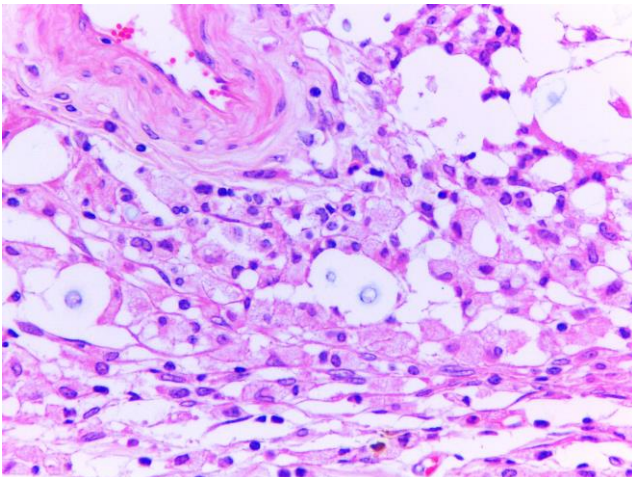


Figure 3. Goat. Leptomeninges. Granulomatous leptomeningitis cause by *Cryptococcus neoformans*. Higher magnification of Fig. 2. Intralésional *C. neoformans* organisms can be seen displaying a distinct clear halo (capsule) amidst the cellular infiltrate and occasionally with the cytoplasm of macrophages (HE stain).

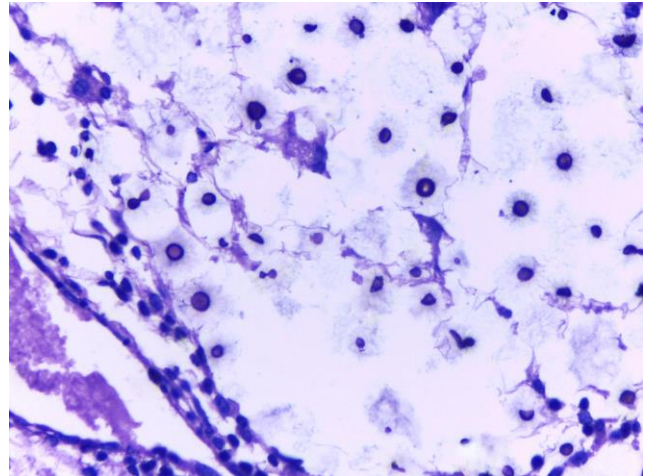


Figure 4. Granulomatous leptomeningitis in a goat. *Cryptococcus neoformans* observed in the leptomeninges by Alcian Blue stain.

TCCTCCGCTTATTGATATGC-3’) primers targeting the Internal Transcribed Spacer (ITS) region (found in all eukaryotes). Positive bands were submitted for sequencing at the Eton Bioscience Lab (San Diego, CA). Received sequences were trimmed for quality, joined as contigs using Sequencher, and classified at >97% identity match using the basic local alignment search tool (BLAST) against the GenBank database of ITS sequences.

The panfungal PCR amplified an approximately 350 base pair fragment from DNA extracted from the FFPE tissue block. The amplified sequence matched 100% to *Cryptococcus neoformans*. Further subclassification between *C. neoformans* var. *neoformans* and *C. neoformans* var. *gatii* was not possible, as the amplified sequence matched equally to both varieties.

Discussion

The diagnosis in the present case was based in the characteristic morphology of the organism which is consistent with descriptions for *Cryptococcus* spp. (7). Species was confirmed by panfungal PCR as *Cryptococcus neoformans*. The true polysaccharide capsule outside the organism cell wall is important for the evasion of the organism from the immune system (2, 10). This capsule does not stain with HE giving the characteristic clear halo surrounding the organism (7).

Caprine cryptococcal disease is uncommon. Published cases include pneumonia by *C. gatii* in Spanish goats (1), pneumonia caused by *C. neoformans* associated with *Mycobacterium bovis* infection (8), experimental and natural occurrence of mastitis by *C. neoformans* (15, 17), obstructive granulomatous rhinitis by *C. neoformans* (5), and granulomatous dermatitis and panniculitis by *C. gatii* (19); however, there is only one published case of cryptococcal meningitis in goats (18).

In caprine cryptococcal disease, *C. gatii* (1, 19) or *C. neoformans* may be involved (18). As confirmed by

panfungal PCR analyses the latter was involved in the case of this report.

The immune status of the goat of this report was unknown. However general sanitary conditions in the premises were less than adequate, and although no lesions of caseous lymphadenitis were detected at necropsy, the disease was endemic in this herd. *Corynebacterium tuberculosis* (18) and *Mycobacterium bovis* (8), have been described to facilitate cryptococcal disease in goats. Transportation can be a cause of stress and resulting immune compromise; there was a possibility that transportation had been a feature in the setting of this particular case.

The infection of *Cryptococcus* spp. is by inhalation of air-borne organisms and that systemic cryptococcosis will start in the nasal cavity or the lungs, although respiratory involvement usually does not result in clinical signs (18). Then, the infection results in dissemination via the bloodstream and spread to the CNS. No lung lesions were observed in the goat of this report, but the extension to the CNS can occur hematogenous or through the cribiform plate from a nasal asymptomatic focus (18). Again, no lesions were found in the nasal cavity of this goat, but we cannot rule out for sure that a tiny asymptomatic lesion in the nasal cavity could have been neglected at necropsy.

The blindness in this presented in the goat of this resort could be cortical due to pressure of meningeal cellular exudate or due to primary eye lesions, as chorioretinitis is frequently described in association with cryptococcosis (20). Although no, clinical or gross evidence of eye lesions were observed, the globes were not submitted for histopathological examination.

In conclusion, cryptococcal meningitis should be included in the differential diagnosis list of goat diseases with neurological signs such as ataxia, opisthotonus, nystagmus, hyperesthesia and spastic paresis.

Acknowledgments

One of the authors (CSLB) is funded by a fellowship from FUNDECT/CAPES.

References

1. BARÓ T., TORRES-RODRIGUEZ JM., MENDOZA MH., MORERA Y., ALÍA C. First identification of autochthonous *Cryptococcus neoformans* var. *gattii* isolated from goats with predominantly severe pulmonary disease in Spain. **J. Clin. Microbiol.**, 1998, 36, 458-61.
2. BOSE I., REESE AJ., ORY JJ., JANBON G., DOERING TL. A yeast undercover: The capsule of *Cryptococcus neoformans*. **Eukariotic cell**, 2003, 2, 655-663.
3. BOVERS M., HAGEN F., BOEKHOUT T. Diversity of the *Cryptococcus neoformans-Cryptococcus gattii* species complex. **Rev. Iberoam. Micol.**, 2008, 25, S4-S12.
4. CASWELL V., WILLIWAMS KJ. Infectious diseases of the respiratory system. MAXIE MG. (Ed) **Jubb, Kennedy, and Palmer's Pathology of Domestic Animals**. 6 ed., vol. 2. Elsevier, St. Louis, Missouri 2016, 523-591.
5. CHAPMAN HM., ROBINSON WF., BOLTON JR., ROBERTSON JP. *Cryptococcus neoformans* infection in goats. **Aust. Vet. J.**, 1990, 67, 263-265.
6. DE PAULA DAJ., ALMEIDA BPF., CRUZ FS., FURLAN FH., COLODEL EM., SOUSA VRF., NAKASATO L., DUTRA V. Occurrence and molecular characterization of cryptococcosis in dogs and cats in Brazil. **Pesq. Vet. Bras.**, 2014, 34, 2671-2672.
7. GALIZA GJN., SILVA TM., CAPRIOLI R., TOCHETTO C., ROSA FB., FIGHERA RA., KOMMERS GD. Características histomorfológicas e histoquímicas determinantes no diagnóstico da criptococose em animais de companhia. **Pesq. Vet. Bras.**, 2014, 34, 261-269.
8. GUTÉRREZ M., GARCIA MARIN JF. *Cryptococcus neoformans* and *Mycobacterium bovis* causing granulomatous pneumonia in a goat. **Vet. Pathol.**, 1999, 36, 458-461.
9. KOMMERS GD., SOUSA TM., MOREIRA SOUTO MA., DE LA CORTE FD., BARROS CSL. Criptococose pulmonar granulomatosa em equino. **Ciênc. Rural**, 2005, 35, 938-940.
10. KRONSTAD JW., ATTARIAN R., CADIEUX B., CHOI J., SOUZA CA., GEDDES JMH., HU G., JUNG WH., KRETSCHMER M., SALKIA S., WANG J. Expanding fungal pathogenesis: *Cryptococcus* breaks out of the opportunistic box. **Nature**, 2001, 9, 193-203.
11. LENARD ZM., LESTER NV., O'HARA AJ., HOPPER BJ., LESTER GD. Disseminated cryptococcosis including osteomyelitis in a horse. **Aust. Vet. J.**, 2007, 51-55.
12. MALIK R., DILL-MACKY E., MARTIN P., WIGNEY DI., MUIR DB., LOVE DN. Cryptococcosis in dogs: a retrospective study of 20 consecutive cases. **Med. Mycol.**, 1995, 33, 291-297.
13. MCGILL S., MALIK R., SAUL N., BEETSON S., SECOMBE C., ROBERTSON I., IRWIN P. Cryptococcosis in domestic animals in Western Australia: a retrospective study from 1995-2006. **Med. Mycol.**, 2009, 47, 625-639.
14. MEASON-SMITH C., EDWARDS E., OLDER CE., BRANCO M., BRYAN LK., LAWHON JS., SUCHODOLSKI G., GOMEZ JM., MANSELL A., RODRIGUES-HOFFMANN A. Panfungal PCR on formalin-fixed paraffin-embedded animal tissues: a complementary diagnostic tool to histopathology for classification of fungal pathogens. **Vet. Pathol.**, 2016 (In press).

15. PAL M., RANDHAWA HS. Caprine mastitis due to *Cryptococcus neoformans*. **Sabouraudia**, 1976, 14, 261-263.
16. RIET-CORREA F., KROCKNBERGER M., DANTAS AFM., OLIVIERA DM. Bovine cryptococcal meningoencephalitis. **J. Vet. Diagn. Invest.**, 2011, 23, 1056-1060.
17. SINGH M., GUPTA PP., RANA JS., JAND SK. Clinic-pathological studies on experimental cryptococcal mastitis in goats. **Mycopathologia**, 1994, 126, 147-155.
18. STILLWELL G., PISSARRA H. Cyptococcal meningitis in a goat - a case report. **BMC Vet. Res.**, 2014, 10, 84 (available at <http://www.biomecentral.com/1746-6148/10/84>).
19. VILARROEL A., MAGGIULLI TR. Rare *Cryptococcus gatii* infection in an immunocompetent dairy goat following a cesarean section. **Med. Mycol.**, 2012, 1, 91-94.
20. WILLCOK BP., NJAA BL., WILLIWAMS KJ. Cryptococcosis. MAXIE MG (Ed). **Jubb, Kennedy and Palmer's Pathology of Domestic Animals**. 6 ed., vol. 1. Elsevier, St. Louis, Missouri 2016: 450.