BJVP
Brazilian Journal of Veterinary Pathology
ISSN 1983-0246

**Case Report**

# Multiple congenital encephalic malformations in a calf

Lorena F. Silva[1], Rogério E. Rabelo[2], Guilherme P. Santos[2], Oton L. R. Aguiar[2], Luciana Sonne[3], Claudio S. L. Barros[4], Fabiano J. F. de Sant'Ana[1*]

[1]Universidade de Brasília (UnB), Hospital Veterinário de Grandes Animais, Laboratório de Diagnóstico Patológico Veterinário, Brasília, DF, Brazil.
[2]Universidade Federal de Goiás (UFG), Regional Jataí, Setor de Cirurgia de Grandes Animais, Jataí, GO, Brazil.
[3]Universidade Federal do Rio Grande do Sul (UFRGS), Departamento de Patologia Clínica Veterinária, Porto Alegre, RS, Brazil.
[4]Universidade Federal de Mato Grosso do Sul (UFMS), Faculdade de Medicina Veterinária e Zootecnia, Campo Grande, MS, Brazil.
[*]**Corresponding author:** Universidade de Brasília (UnB), Hospital Veterinário de Grandes Animais, Laboratório de Diagnóstico Patológico Veterinário, SRB, Área Especial, Galpão 04, Granja do Torto, 70636-020, Brasília, DF, Brazil. Phone: (+55) 61 3468-7255. E-mail: santanafjf@yahoo.com

Submitted June 9th 2016, Accepted July 18th 2016

**Abstract**

Multiple congenital malformations of the central nervous system are uncommonly described in domestic animals. A 7-days-old, female, Holstein calf was submitted for necropsy with a history of opisthotonus and permanent lateral recumbence. Clinical signs included apathy, abdominal breathing, occasional flexion of the forelimbs, and decreasing of the superficial and deep sensibility in all limbs. Necropsy and histopathology revealed cerebellar hypoplasia, stenosis of the mesencephalic aqueduct, fusion of the rostral and caudal colliculi, secondary hydrocephaly, villous hypertrophy of the choroid plexus and heterotopy of cerebellar cellular components. Immunohistochemical labeling for the antibody anti-BVDV in fragments of brain resulted negative, suggesting that this virus did not participate in the pathogenesis of these malformations.

**Key words:** diseases of calves, neuropathology, central nervous system, cerebellar hypoplasia.

## Introduction

Malformations of the central nervous system (CNS) are common in domestic animals, mainly in cattle, pigs, cats and sheep (3, 10). However, multiple congenital alterations affecting different regions of the CNS have rarely been described in cattle (1, 7). These malformations may account for up to 5% of all neonatal deaths and for an undetermined number of abortions in various species (12). The major causes of these congenital lesions include uterine exposure to microorganisms, mainly virus, teratogenic chemical agents, and other unknown factors. The most frequent CNS sporadic anatomic abnormalities are neural tube defects (2). The cerebellum is a region frequently affected by these congenital defects and the most frequent malformations include hypoplasia, abiotrophy, and dysplasia. Usually, these changes are caused by primary developmental defects or viral infection. The main examples of this latter situation include feline panleucopenia virus in cats, bovine virus diarrhea (BVDV) in cattle, hog cholera virus in pigs, and bluetongue virus in lambs. This report describes a rare case of multiple congenital encephalic malformations in a calf. Few previous reports of bovine congenital anomalies have documented the multiplicity and the severity of the lesions seen in the current case.

## Case report

A 7-days-old, female, Holstein calf was submitted for necropsy with a history of opisthotonus and permanent lateral recumbence since the first day of life (Fig. 1A). Treatment was performed by owner in the first hours using doramectin (Dectomax, Zoetis) and oxytetracycline (Terramicina, Pfizer), without improvement. In addition, clinical signs included apathy, abdominal breathing, occasional flexion of the forelimbs, and decreasing of the superficial and deep sensibility in all limbs, culminating

 All rights reserved 2007.

with spontaneous death. The calf was from a dairy farm located in the county of Jataí, southwestern region of the state of Goiás, Brazil and occurred at the dry season (September 2015). Similar cases were never detected previously in this farm. All cattle of this farm (including the cows) were vaccinated against foot-and-mouth disease and rabies.

Grossly, lesions were restricted to the brain. Moderate cerebellar hypoplasia was observed (Fig. 1B). There was fusion of the rostral and caudal colliculi, stenosis of the mesencephalic aqueduct and of the caudal region of the third ventricle, and secondary dilation of the lateral ventricles (hydrocephaly), at the level of the parietal and frontal telencephalon (Fig. 1C). Mild secondary atrophy of the hippocampus and of the parietal cortex was noted. Cut surfaces of the dorsal and ventral cerebellar vermis showed focally extensive, well-delimited, whitish areas (Fig. 2A). In addition, moderate villous hypertrophy of the choroid plexus (Fig. 1B) and seven smooth, whitish, 0.3-1.5cm nodules were observed projecting to the internal space of the lateral ventricles. The fresh whole brain was submitted for histopathological evaluation. After fixation with 10% buffered formalin, fragments were processed routinely and stained with hematoxylin and eosin and immunohistochemistry (IHC) using streptavidin-biotin-phosphatase complex, Protease XIV (Sigma) for 15 minutes and Permanent Red (Dakocytomation) as chromogen. For IHC the antibody anti-BVDV (monoclonal - IDEXX, 1:500, overnight) was applied. IHC sections were counterstained with Harris hematoxylin. Positive control for IHC consisted of cerebellum of a BVDV naturally-infected heifer. For negative control, the primary antibody was replaced with PBS. After the gross evaluation performed in this calve, uncoagulated blood was sampled from the jugular vein of the dam and a serum sample was submitted to virus-neutralization test (VNT) according to OIE modified recommendations (2015). The initial dilution of the serum was 1:5 follow to two fold dilutions, and it was challenge with 100-200 tissue culture infective doses ($TCID_{50}$) of BVDV-1.

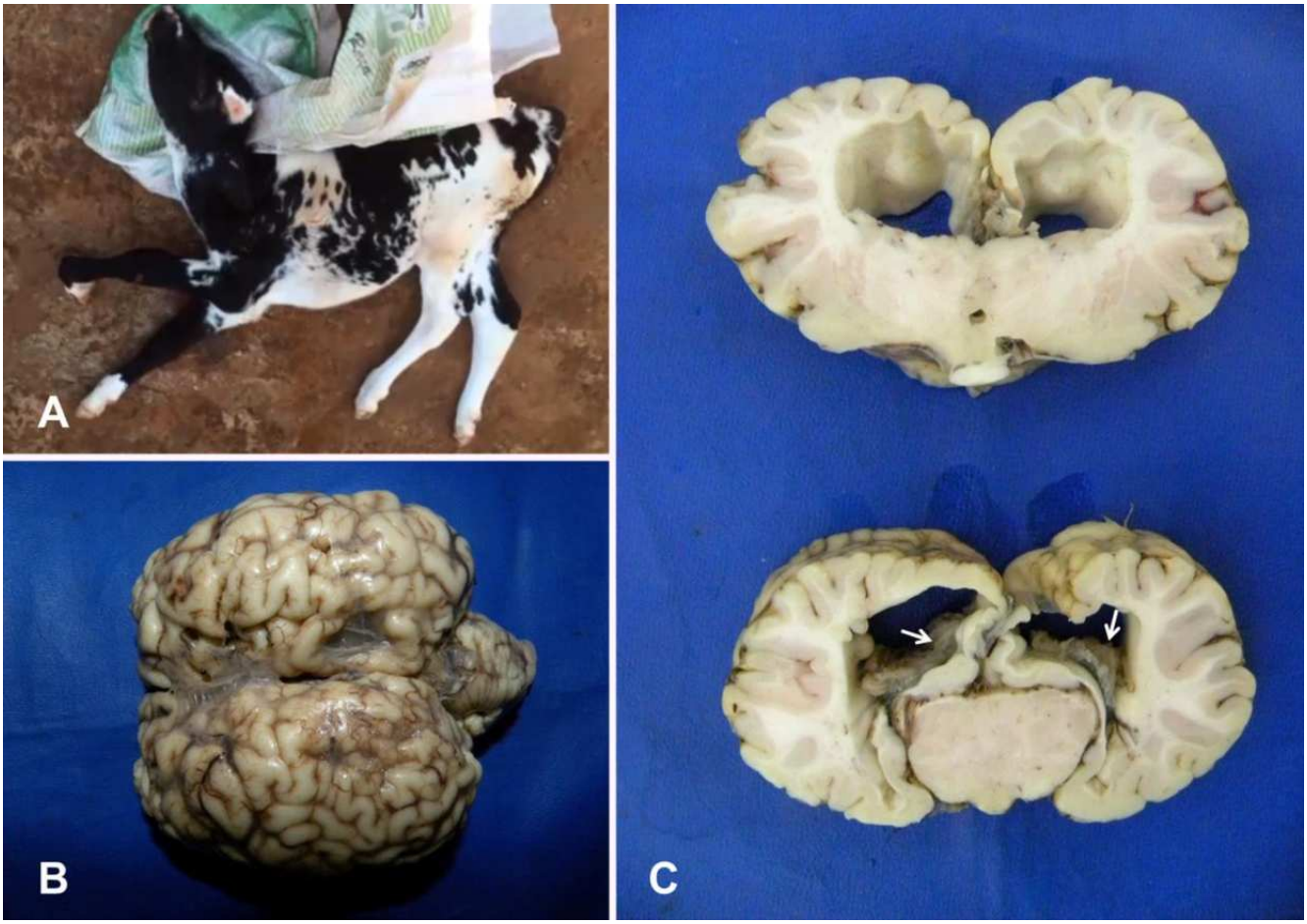


**Figure 1.** Multiple congenital encephalic malformations in a calf. Animal presents opisthotonus and lateral recumbency (A). Grossly, lesions included cerebellar hypoplasia (B), hydrocephaly, hypertrophy of the choroid plexus (arrows), and stenosis of the mesencephalic aqueduct (C).

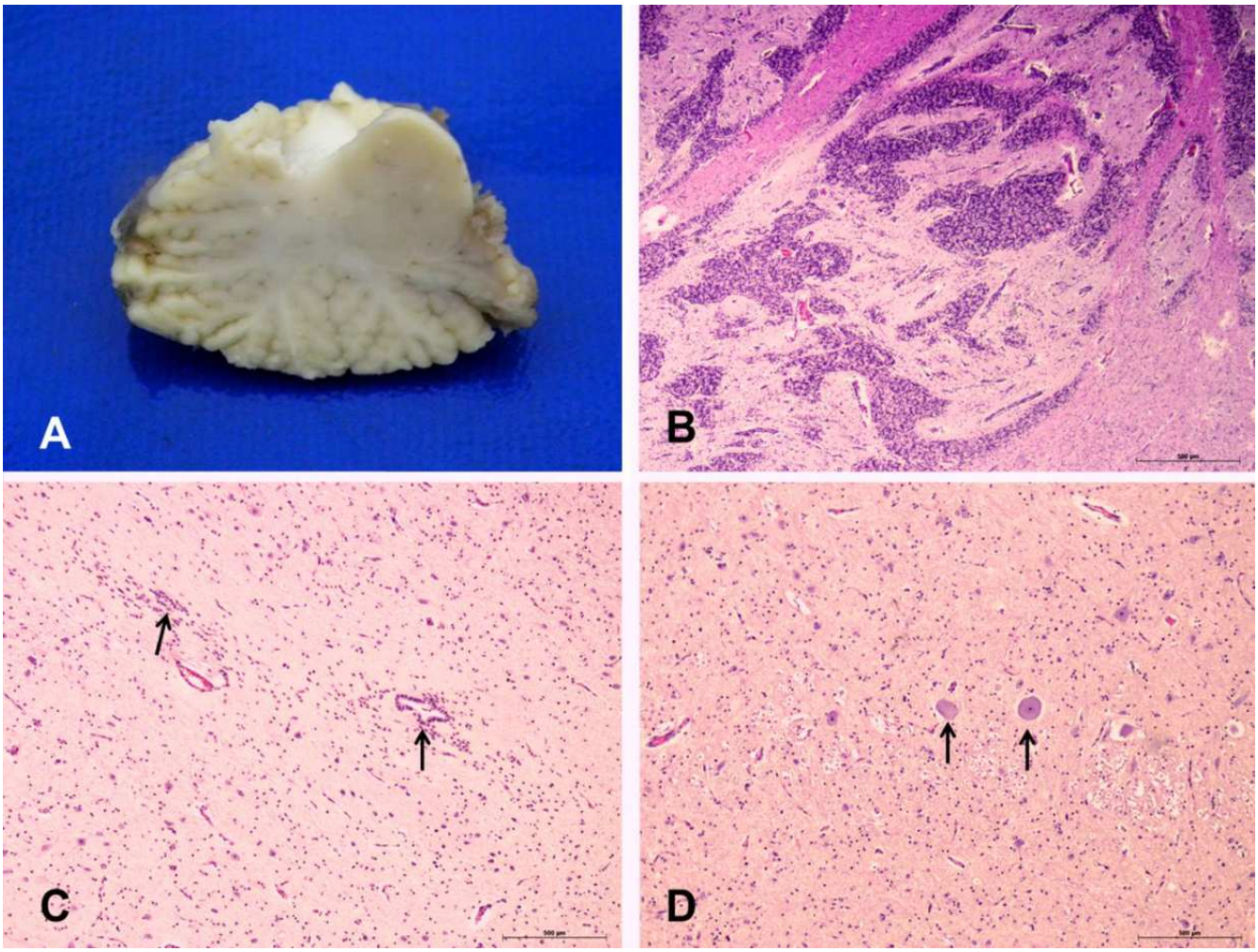


**Figure 2.** Multiple congenital encephalic malformations in a calf. A. There is a focally extensive, well-delimited, and whitish area in the cut surface of the cerebellar vermis. B. Cerebellum: microscopic view of this whitish area showing severe disorganization and blending of molecular, Purkinje cells, and granular layers (heterotopy) and subcortical white matter. C. Midbrain: note stenosis and two segments (arrows) of the mesencephalic aqueduct. D. Midbrain: there were few neurons in the oculomotor nucleus.

Histopathologically, there was severe stenosis of the mesencephalic aqueduct which was divided in three segments, loss of definition with few neurons in the oculomotor and red nuclei, and mild vacuolization of the parenchyma. There were focally extensive areas in the cerebellum consisting of severe disorganization, atrophy and blending of molecular, Purkinje cells, and granular layers (heterotopy) and subcortical white matter. The whitish nodules observed grossly peripheral to the lateral ventricles consisted of foci of proliferative neuroblasts surrounded by a moderate layer of white matter. At this region the lateral ventricle was not lined by ependymal cells. There was moderate villous hypertrophy of the choroid plexus that consisted of many irregular layers of epithelial cells projecting to the ventricles. Severe atrophy of the gray and white matter of the parietal and frontal telencephalon and hippocampus at the level of the hydrocephalic ventricles was noted. There was also moderate swelling of endothelial cells at the frontal cortex and basal nuclei. On IHC evaluation, there was no labeling for the antibody anti-BVDV. BVDV-1 titles shown by virus neutralization test were 1:40.

## Discussion

Usually, the diagnosis of congenital anomalies in domestic animals is made based in the clinical evaluation and imaging (radiography, computerized tomography, magnetic resonance) and it is confirmed by necropsy and histopathology (7, 8, 14). The localization and severity of the multiple congenital brain malformations detected in the calf of the current report were compatible with the neurological clinical signs displayed by the calf. These signs can vary according to localization or the anomaly in the affected CNS and frequently have an insidious onset. Blinding, apathy and incoordination were observed in a 3-

month-old calf with extensive congenital cerebrum encephalopathy (1). When the cerebellum is severely affected in these congenital cases, clinical signs such as ataxia, dysmetria, and intention tremors can be observed (5).

The cause of the developmental anomalies in the calf of the current case could not be determined. Many of such anomalies in cattle have been associated to genetic factors (7), environmental agents (toxins, viral infections, management) or a combination of those. Some authors suggest that calves produced by in vitro fertilization and by other reproduction advanced techniques can present higher probability of develop similar anomalies in the CNS and in other organs (13). In some cases, a genetic basis associated to simple autosomal recessive trait has been determined for bovine internal hydrocephalus (6). Necropsy and histopathology revealed this and other encephalic malformations. Based on the clinical signs, BVDV infection causing cerebellar hypoplasia was suspected but the negative labeling to antibody anti-BVDV in the brain observed by IHC suggests that BVDV did not participate in the pathogenesis of the malformations. The moderate positive serologic reaction of the dam to BVDV was interpreted previous contact this cow with the infectious agent and do not correlate with active viral infection. This type BVDV-serologic detection to BVDV viral antibodies are extremely common in Brazilian adult cattle (4). There was no information on the vaccination against BVDV in the herd.

The main malformations detected in the calf of this report included cerebellar hypoplasia, stenosis of the mesencephalic aqueduct, fusion of the rostral and caudal colliculus, secondary hydrocephaly, hypertrophy of the choroid plexus and cerebellar heterotopy. Some of these lesions are rarely described in cattle and the affected animals usually die early (as in the present report) or are euthanized *in extremis* (1, 5, 6, 7). It is possible that hypertrophy of choroid plexus has involvement with the hydrocephaly detected in the current case, but the stenosis of mesencephalic aqueduct was clearly an important predisposing lesion. Heterotopy of cerebellar cortex, as visualized in the present case, is a congenital lesion uncommonly detected in calves and has been attributed to Akabane virus, especially in Japan (11). This anomaly might be caused by inhibition of neuroblastic migration (11).

The congenital malformations found in the current case resemble Dandy-Walker syndrome, a condition described more frequently in humans and occasionally in domestic animals, such as calves, foals and lambs (8, 12, 14). Dandy-Walker syndrome has unknown etiology and is characterized mainly by agenesis of the cerebellar vermis, cystic dilation of the expanded fourth ventricle, enlargement of the caudal fossa and hydrocephalus (10, 12, 14).

**Acknowledgments**

The authors are grateful to Dr. Juliana Felipetto Cargnelutti (Setor de Virologia, UFSM, Santa Maria, RS, Brazil) for the technical assistance with the serology for BVDV.

**References**

1. BROWN CC., MACLACHLAN. Congenital encephalopathy in a calf. **Vet. Pathol.**, 1983, 20, 770-773.
2. CANTILE C., YOUSSEF S. Nervous system. MAXIE MG (Ed). **Jubb, Kennedy, and Palmer's Pathology of Domestic Animals**. 6 ed., vol. 1. Elsevier, St. Louis, Missouri 2016: 250-406.
3. DONE JT. Congenital nervous diseases of pigs: a review. **Lab. Anim.**, 1968, 2, 207-217.
4. FLORES EF., WEIBLEN R., VOGEL FSF., ROEHE PM., ALFIERI AA., PITUCO EM. A infecção pelo vírus da Diarréia Viral Bovina (BVDV) no Brasil - histórico, situação atual e perspectivas. **Pesq. Vet. Bras.**, 2005, 25, 125-134.
5. KORNEGAY JN. Cerebellar vermian hypoplasia in dogs. **Vet. Pathol.**, 1986, 23, 374-379.
6. LEIPOLD HW., DENNIS SM. Congenital defects of the bovine central nervous system. **Vet. Clin. North Am. Food Anim. Pract.**, 1987, 3, 159-177.
7. NEWMAN SJ., BAILEY TL., JONES JC., DIGRASSIE WA., WHITTIER WD. Multiple congenital anomalies in a calf. **J. Vet. Diagn. Invest.**, 1999, 11, 368-371.
8. NOUREDDINE C., HARDER R., OLBY NJ., SPAULDING K., BROWN T. Ultrasonographic appearance of Dandy Walker-like syndrome in a Boston Terrier. **Vet. Radiol. Ultrasound.**, 2004, 45, 336-339.
9. OIE. Bovine viral Diarrhoea. Chapter 2.4.8. OIE Terrestrial Manual 2015. Available from: http://www.oie.int/fileadmin/Home/fr/Health_standards/tahm/2.04.08_BVD.pdf. Accessed: April 18, 2016.
10. SUMMERS BA., CUMMINGS JF., DE LAHUNTA A. **Veterinary Neuropathology**. Mosby, St. Louis 1995: 68-94.
11. UMEMURA T., SATO H., GORYO M., ITAKURA C. Histopathology of congenital and perinatal cerebellar anomalies in twelve calves. **Jpn. J. Vet. Sci.**, 1987, 49, 95-104.
12. VANDEVELDE M., HIGGINS RJ., OEVERMANN A. **Veterinary Neuropathology, Essentials of Theory and Practice**. Wiley-Blackwell, West Sussex 2012: 92-105.
13. WALKER SK., HARTWICH KM., SEAMARK RF. The production of unusually large offspring following embryo manipulation: concepts and challenges. **Theriogenology**, 1996, 45, 111-120.

14. WONG D., WINTER M., HAYNES J., SPONSELLER B., SCHLEINING J. Dandy-Walker-like syndrome in a quarter horse colt. **J. Vet. Intern. Med.**, 2007, 21, 1130-1134.

Brazilian Journal of Veterinary Pathology. www.bjvp.org.br . All rights reserved 2007.