BJVP
Brazilian Journal of Veterinary Pathology
ISSN 1983-0246

Case Report

Hepatogenous chronic copper toxicosis associated with grazing *Brachiaria decumbens* in a goat

Fábio B. Rosa[1], Mara I. B. Rubin[2], Tessie B. Martins[3], Danilo C. Gomes[3], Ricardo A. A. Lemos[3], Michael D. B. Massena[3], Guilherme M. Marques[3], Claudio S. L. Barros[3*]

[1]Centro de Ciências Rurais (CCR), Universidade Federal de Santa Maria (UFSM), Bairro Camobi, Santa Maria, RS 97105-900, Brazil.
[2]Department of Large Animal Clinic, UFSM, Santa Maria, RS, Brazil.
[3]Faculty of Veterinary Medicine and Animal Husbandry (FAMEZ) Universidade Federal de Mato Grosso do Sul (UFMS), Campo Grande, MS, Brazil.
[*] **Corresponding Author:** Faculty of Veterinary Medicine and Animal Husbandry (FAMEZ), Universidade Federal de Mato Grosso do Sul (UFMS), Av. Senador Filinto Müller 2443, Campo Grande, MS 79074-460, Brazil. E-mail: claudioslbarros@uol.com.br

Submitted June 15th 2016, Accepted November 23rd 2016

Abstract

A case of hepatogenous chronic copper toxicosis associated with ingestion of *Brachiaria decumbens* in a 4-year-old female is reported in a goat from a herd of approximately 1,000 goats of different categories, all grazing in a pasture consisting exclusively of *B. decumbens.* The goat had chronic weight loss, dehydration, and apathy. Just prior to death it developed anemia, icterus and hemoglobinuria. Necropsy findings included marked icterus, enhanced lobular pattern and orange discoloration of the liver, pulmonary edema, distention of the gall bladder and hemoblobinuric nephrosis. Histopathological examination of the liver revealed marked random degeneration and necrosis of individual hepatocytes, marked bilestasis, intracytoplasmic hemosiderin in hepatocytes and Kupffer cells, birefringent crystals with bile staining in the lumen of bile ducts, and sparse, randomly distributed foamy macrophages. Severe multifocal tubular degeneration and necrosis associated with multiple hyaline and coarsely granular hemoglobin casts were observed in the kidneys. Copper levels determined in liver and kidney samples by atomic absorption spectrophotometry were 410 ppm of liver dry matter and 34.4 ppm (kidney, dry matter). The gross, histopathological findings and copper analysis in the tissues of this goat led to a final diagnosis of hepatogenous chronic copper toxicosis associated with grazing of *B. decumbens*.

Key words: diseases of goats, liver diseases, toxicosis, copper, poisonous plants.

Introduction

Copper toxicosis in livestock is described in acute and chronic forms. The latter is very common, mainly in sheep, and the former is rare. These two forms refer to the duration of copper exposure, as opposed to the onset of clinical signs (22). Acute toxicity occurs when large quantities of copper are ingested at once, e.g. from footbath, which triggers gastrointestinal disorders due to copper caustic properties; this is characterized by abdominal pain, diarrhea, emesis, anorexia, dehydration and shock. Chronic toxicity is the most important in domestic animals and can be (a) primary, caused by the consumption of feed containing high levels of copper; (b) phytogenous, associated with the consumption of pasture containing normal copper and reduced molybdenum levels; and (c) hepatogenous, when the copper accumulation results from liver damage caused by toxic plants (3, 14). The chronic form is characterized by a subclinical phase, during which copper accumulates within hepatocytes, for weeks or months, followed by an acute phase resulting from the release of the accumulated copper into the bloodstream, causing intravascular hemolysis, anemia, icterus and hemoglobinuria (11, 16). There is a significant variation in species susceptibility to copper toxicosis. Sheep is rather susceptible due to reduced biliary excretion of copper (9, 11, 16). Toxicosis in cattle and pigs are less common and due to abnormally high intake of the copper

 All rights reserved 2007.

(24). Goats are reportedly more resistant to copper intoxication than sheep (22). Consequently, there are few published reports of copper toxicosis in goats (1, 2, 7, 20).

In sheep, species in which the toxicosis is more common, there are reports of hepatogenous chronic copper poisoning associated with the ingestion of toxic plants containing pyrrolizidine alkaloids such as *Senecio* spp., *Echium plantagineum* and *Crotalaria retusa* (10, 19). However, there is no report of hepatogenous copper toxicosis in goats.

It is well known that ingestion of *Brachiaria* spp. by ruminants cause hepatogenous photosensitization and crystal-associated cholangiopathy (11). There is scarce documentation of naturally occurring chronic copper toxicosis in goats and to the authors' knowledge, this is the first report of caprine chronic hepatogenous copper toxicosis secondary to ingestion of *Brachiaria decumbens*. The current report describes the pathological aspects of this toxicosis.

Case report

A 4-year-old female mixed-breed goat died after presenting chronic weight loss, dehydration, mild icterus, and apathy; two days before its death the goat developed acute severe icterus and hemoglobinuria. The goat was part of a herd of a 1,000 goats of different categories. The farm is exclusively focused on meat production and the goats graze in a pasture consisting exclusively of *B. decumbens*. Necropsy changes included severe yellow discoloration (icterus) of oral, ocular and vaginal mucous membranes, subcutaneous tissue, muscle fascia and visceral fat; diffuse orange discoloration (Fig. 1) and enhanced lobular pattern in the liver; distension of the gallbladder; kidneys markedly and diffusely dark brown, with metallic appearance throughout the cut surface, and markedly yellow pelvic fat (Fig. 2). The bladder contained dark brown urine; the spleen was slightly increased in volume; and moderate amounts of foamy fluid oozed from the trachea (pulmonary edema). Samples from multiple organs, including brain, heart, liver, lung, spleen, kidney and intestine were fixed in buffered 10% formalin and processed routinely for histopathology and stained with hematoxylin and eosin.

Formalin-fixed fragments of liver and kidney were submitted to copper determination by atomic absorption spectrophotometry, and resulted in 410 ppm and 34.4 ppm, respectively. Copper concentration reference values in the liver and kidney of goats are much lower than those reported for sheep. They may be as low as 25–150 ppm for the liver and 3–6 ppm for the kidney, and 230 mg/kg in the liver and 12 mg/kg in the kidney are consistent with copper toxicosis in goats (7). In an outbreak of 3 goats with chronic copper poisoning (2), copper concentration for the 3 goats (given in ppm) were 436, 378, and 23.4 for the liver and 22.2, 17.6, and 17.1 for the kidney. Thus, the levels of copper in the goat of this report is in accordance with a diagnosis of chronic copper poisoning.

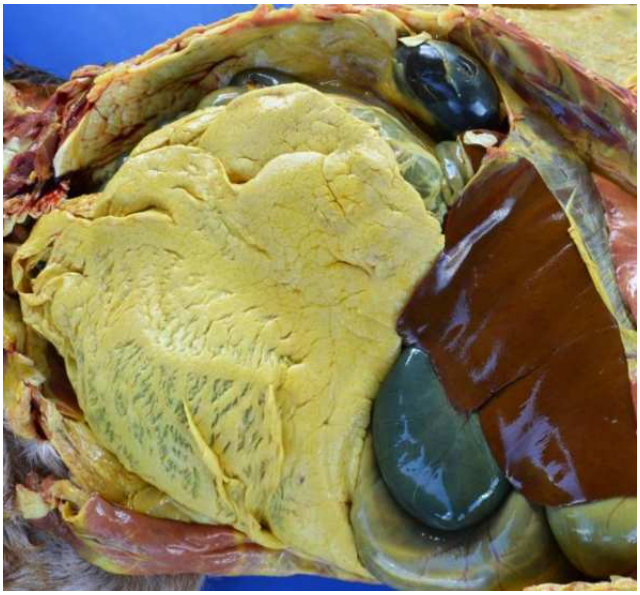

Figure 1. Goat. Chronic hepatogenous copper toxicosis. Exposed abdominal viscera. Severe icterus, dark brown kidneys, and orange discolored liver. The fat of the omentum is markedly yellow (icterus). All these are signs of hemolytic crisis.



Figure 2. Goat. Chronic hepatogenous copper toxicosis. Kidney. Cut surface. The parenchyma is dark brown with metallic appearance. The fat of renal pelvis is markedly yellow (icterus).

Histological findings in the liver consisted of multiples bile casts in bile canaliculi and bile-stained birefringent crystals in the lumen of bile ducts (Fig. 3),

random hepatocellular degeneration and necrosis and randomly distribute foamy macrophages (Fig. 4), intracytoplasmic hemosiderin in the cytoplasm of hepatocytes and Kupffer cells. The renal cortex had severe diffuse tubular degeneration and necrosis associated with multiples hyaline and coarsely granular hemoglobin casts. Multifocally, epithelial tubular cells contained intracytoplasmic dark brown pigment (hemosiderin) and there were tubular ectasia (Fig. 5). The spleen had numerous hemosiderin-laden macrophages. There were no microscopic changes related to the intoxication in other organs.

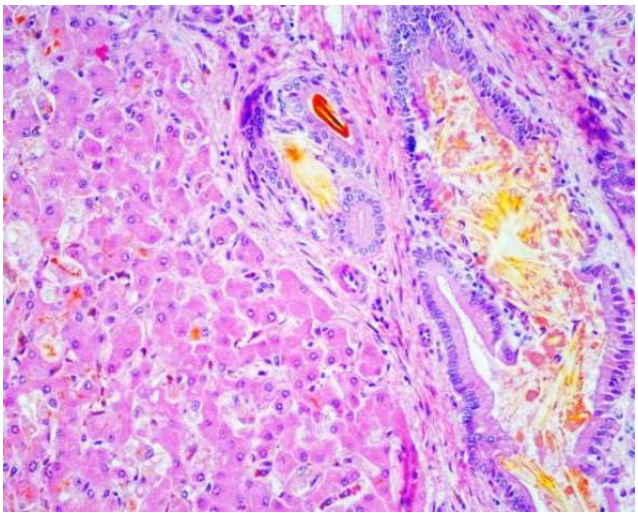

Figure 3. Goat. Chronic hepatogenous copper toxicosis. Histology of the liver. Multiple bile ducts filled with bilirubin-embedded refringent crystals. Mild hepatocellular degeneration and marked cholestasis. Hematoxylin and eosin, obj.40x.

Discussion

Diagnosis of hepatogenous chronic copper toxicosis induced by liver damage due to ingestion of *B. decumbens* was based on excluding exposure to exogenous sources of copper, and in clinical-pathologic findings and levels or copper in liver and kidney. Although feedstuffs were not tested for copper levels, there was no history of administration of copper containing hematinics, copper oxide-containing boluses, exposure to swine or poultry litter, copper-containing footbaths, copper plumbing, or chemicals. The only hepatoxic, or toxic for that matter, plant present was *B. decumbens*. Ideally, all components of the diet should be analyzed for trace element content in instances of suspected copper toxicosis, and a careful assessment should be made of the proportions of those components in the diet. However, there were logistical and financial constraints on the number of possible sources of copper and/or mineral imbalances that could be investigated.

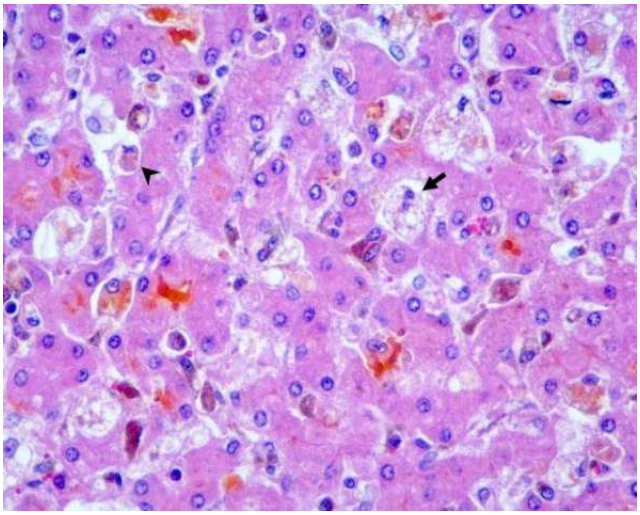

Figure 4. Goat. Chronic hepatogenous copper toxicosis. Histology of the liver. Individual hepatocellular necrosis (arrow head) and marked cholestasis. Foamy macrophages (arrow) are seen within sinusoids. Hematoxylin and eosin, obj.40x.

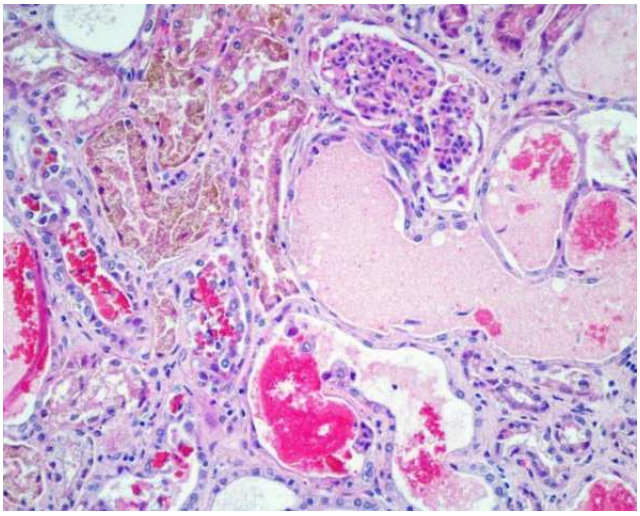

Figure 5. Goat. Chronic hepatogenous copper toxicosis. Histology of the kidneys. Some tubules are dilated and filled by granular (hemoblobin) and homogenous eosinophilic casts. Multifocally, the tubular epithelial cells contain intracytoplasmic golden-brown pigment (hemosiderin). Tubular ectasia can also be observed. Hematoxylin and eosin, obj.40x.

In most reports of copper toxicosis in goats, there is an association with high intake of dietary copper or the cause is undetermined (1, 2, 7). There are few reports regarding caprine chronic copper intoxication in goats (1, 2, 7, 8) and there is no uniformly accepted maximum tolerable levels of dietary concentration of copper for goats (15). Similar to what occurs in sheep, it is known that caprine susceptibility to chronic copper toxicosis varies with breed (5, 6, 15). Adult goats and Boer crosses are

 All rights reserved 2007.

generally considered resistant, especially to the hemolytic stage of the toxicosis (2), which is at odds with the results of the current report that describes a case of copper toxicosis in an adult goat.

Hepatogenous chronic copper toxicosis is rare in sheep (10) and it has never been documented in goats. Reports of hepatogenous chronic copper toxicosis in sheep are associated with the ingestion for several months of toxic plants containing pyrrolizidine alkaloids such as *Senecio* spp., *Echium plantagineum* and *Crotalaria retusa* (10, 19). These plants predispose to excessive liver uptake of copper. It has been postulated that pyrrolizidine alkaloids increase the avidity of liver cells for copper, ultimately leading to the hemolytic crisis of chronic copper toxicity (10, 12). In such cases, despite the chronic liver injury, animals die from loss of kidney function and anemia due to acute hemolytic crisis. Clinical signs may include photosensitization, chronic weight loss, hepatic encephalopathy followed by icterus and hemoglobinuria (12). With exception of photosensitization and hepatic encephalopathy, all of these clinical signs were observed in the case of this report. But then, a clinical syndrome of progressive weight loss and death, without photosensitization, has been reported in cattle poisoned by *B. decumbens* (17), and probably the goat of this report is included in this syndrome.

The liver damage observed in this goat was due to ingestion of *B. decumbens.* Protodioscin is the toxic principle of *Brachiaria* spp. This substance is a lithogenic steroidal saponin that induces pathologic changes in liver parenchyma and biliary ducts, disturbing clearance of phylloerythrin, a photodynamic pigment (4). The sequence of chemical transformations of the lithogenic steroidal saponins (LSS) resulting in liver damage is as follows. The LSS ingested in the forage go through hydrolysis in the rumen yielding the sapogenins diosgenin and yamogenin. These two sapogenins are respectively converted to smilagenin and sarsasapogenin. Following this conversion these compounds go through epimerization resulting in their respectively isomers epismilagenin and episarsapogenin (13). These isomers are absorbed and transported via blood to the liver where they conjugate with glucuronic acid giving rise to epismilagenin and episarsapogenin glucoronides that bound to calcium ions forming insoluble calcium salt crystals which precipitate in the hepatic parenchyma and in the bile ducts damaging those structures (14). Multiple crystals were observed within bile ducts in this current case. We believe that the normal flow of bile was compromised by the crystals, resulting in diminished excretion of copper through the bile. When the hepatocytes die (either spontaneously or in response to environmental stress or dietary changes), the release of large amounts of copper in the bloodstream ensues (9). However, the mechanism that relates stressful events to the release of copper by hepatocytes is unknown. The excess of copper in circulation causes denaturation of hemoglobin and direct oxidative damage to the cell membrane of red blood cells with subsequent intravascular hemolysis. The abrupt destruction of erythrocytes (hemolytic crisis) causes necrosis of hepatocytes, which releases even more copper in circulation, creating a vicious cycle of hemolytic crises and hepatic necrosis (23).

Gross and histopathological findings in the goat of this case are typical and similar to those previously described for chronic copper toxicosis in small ruminants (1, 2, 7, 8, 10, 11, 18). The hepatic lesion induced by *B. decumbens* described above may have contributed to the mild icterus initially observed but the icterus suddenly noted was due to acute phase of copper release, i.e., hemolytic crisis. The bile stasis observed histologically may also have been induced by *B. decumbens* ingestion but certainly was most likely a sequel to hemolysis. Therefore, the gross lesions such icterus and orange discoloration of the liver (due to bile stasis and hemosiderin) are a superposition of both mechanisms. In addition, the bile stasis could have also contributed to the excessive hepatic copper accumulation because of impaired biliary excretion of copper (9). The kidney showed a dark brown discoloration due to the high amounts of intratubular hemoglobin casts and intracytoplasmic hemosiderin in tubular epithelial cells observed histologically. It is known that hemoglobin is not nephrotoxic itself. In copper toxicosis, animals affected generally have secondary renal ischemia due to hypovolemic shock or severe anemia and the hemoglobinuria may have additional deleterious effect on the tubular epithelium already compromised by ischemic necrosis (6). However, high concentrations of this element in blood serum and glomerular filtrate may exacerbate tubular necrosis occurring as a result of ischemia (6, 16).

The main differential diagnosis for chronic copper toxicosis is yellow lamb disease, caused by *Clostridium perfringes* type A, wherein both icterus and hemoglobinuria are present. The other differential diagnoses for hemoglobinuria in goats include leptospirosis (*Leptospira interrogans* serovars pomona, icterohemorrhagica and hardjo), babesiosis (*Babesia ovis* and *B. motasi*), bacillary hemoglobinuria (*Clostridium haemolyticum)*, and poisoning by plants of *Brassica* genus (16). The differentiation from the listed diseases can be done by history, clinical signs, combination of gross and microscopic lesions of the kidney and other organs, demonstration of infectious agents when appropriate, by histological findings and, in most cases, by the determination of copper levels in affected animal tissues.

Acknowledgements

The authors are grateful to the financial support of FUNDECT which supports the fellowship of Visiting Professor (FUNDECT/CAPES 05/2014 – PVMS) for one of the authors (CSLB).

References

1. ADAM SEI., WASFI IA. Chronic copper toxicity in Nubian goats. **J. Comp. Pathol.**, 1977, 87, 623-627.
2. BOZYNSKI CC., EVANS TJ., KIM DY., JOHNSON DC., HUGHES-HANKS JM., MITCHELL WJ., ROTTINGHAUS GE., PERRY J., MIDDLETON JR. Copper toxicosis with hemolysis and hemoglobinuric nephrosis in three adult Boer goats. **J. Vet. Diagn. Invest.**, 2009, 21, 395-400.
3. BREMNER I. Manifestations of copper excess. **Am. J. Clin. Nutr.**, 1998, 67, 1069-1073.
4. BRUM KB., HARAGUCHI M., LEMOS RAA., RIET-CORREA F., FIORAVANTI MCS. Crystal-associated cholangiopathy in sheep grazing *Brachiaria decumbens* containing the saponin protodioscin. **Pesq. Vet. Bras.**, 2007, 27, 1, 39-42.
5. BURKE JM., TERRILL TH., KALLU RR., MILLER JE., MOSJIDIS J. Use of copper oxide wire particles to control gastrointestinal nematodes in goats. **J. Anim. Sci**., 2007, 85, 2753-2761.
6. CIANCIOLO TE., MOHR FC. Urinary system. MAXIE MG. (Ed). **Jubb, Kennedy, and Palmer's Pathology of Domestic Animals**. 6 ed., vol. 2. Saunders Elsevier, Philadelphia 2016: 476-464.
7. CORNISH J., ANGELOS J., PUSCHNER B., MILLER G., GEORGE L. Copper toxicosis in a dairy goat herd. **J. Am. Vet. Med. Assoc.**, 2007, 231, 586-589.
8. CREGAR LC., WIEDMEYER CE., RINGEN DR., EVANS TJ., JOHNSON GC., KUROKI K. Copper toxicosis in a Boer goat. **Vet. Clin. Pathol.**, 2012, 41, 502-508.
9. CULLEN JM., STALKER MJ. Liver and biliary system. MAXIE MG. (Ed). **Jubb, Kennedy, and Palmer's Pathology of Domestic Animals**. 6 ed., vol. 2. Saunders Elsevier, Philadelphia 2016: 342-343.
10. ILHA MRS., LORETTI AP., BARROS SS., BARROS CSL. Intoxicação espontânea por *Senecio brasiliensis* (Asteraceae) em ovinos no Rio Grande do Sul. **Pesq. Vet. Bras.**, 2001, 21, 123-138.
11. LEMOS RAA., RANGEL JMR., OSÓRIO ALAR., MORAES SS., NAKAZATO L., SALVADOR SC., MARTINS S. Alterações clínicas, patológicas e laboratoriais na intoxicação crônica por cobre em ovinos. **Ciência Rural**, 1997, 27, 457-463.
12. MÉNDEZ MC., RIET-CORREA F. In: RIET-CORREA F., SCHILD AL., LEMOS RAA., BORGES JRJ. **Doenças de ruminantes e equinos**. 3 ed., vol. 2. Palloti, Santa Maria, 2007: 62-68.
13. MILES CO., WILKINS AL., ERASMUS GL., KELLERMAN TS. Photosensitivity in South Africa. Ovine metabolism of *Tribulus Terrestris* saponins during experimentally induced geeldikkop. **Onderstepoort J. Vet. Res.**, 1994, 61, 4, 351-359.
14. MILES CO., WILKINS AL., ERASMUS GL., KELLERMAN TS., COETZER JAW. Photosensitivity in South Africa. Chemical composition of biliary crystals from a sheep with experimentally induced geeldikkop. **Onderstepoort J. Vet. Res.**, 1994, 61, 3, 215-222.
15. National Research Council. **Nutrient requirements of small ruminants sheep, goats, cervids, and new world camelids**. National Academies Press, Washington, DC; 2007:126-129.
16. NAVARRE CB., PUGH DG. Diseases of the gastrointestinal system. PUGH DG. (Ed.). **Sheep and Goat Medicine**. Saunders Company, Philadelphia 2002: 100-101.
17. RIET-CORREA G., RIET-CORREA F., SCHILD AL., DRIEMEIER D. Wasting and death in cattle associated with chronic grazing of *Brachiaria decumbens*. **Vet. Hum. Toxicol.**, 2002, 44, 179-180.
18. ROUBIES N., GIADINIS ND., POLIZOPOULOU Z., ARGIROUDIS S. A retrospective study of chronic copper poisoning in 79 sheep flocks in Greece (1987-2007). **J. Vet. Pharmacol. Therap.**, 2007, 31, 181-183.
19. SEAMAN JT. Hepatogenous chronic copper poisoning in sheep associated with grazing *Echium plantagineum*. **Aust. Vet. J.**, 1985, 62, 7, 247-248.
20. SOLAIMAN SG., MALONEY MA., QURESHI MA., DAVIS G., D'ANDREA G. Effects of high copper supplements on performance, health, plasma copper and enzymes in goats. **Small Rumin. Res.**, 2001, 41, 2, 127-139.
21. SOLI NE., NAFSTAD I. Effects of daily oral administration of copper to goats. **Acta. Vet. Scand.**, 1978, 19, 4, 561-568.
22. GUPTA RC. (Ed.). **Veterinary Toxicology**. Saunders Elsevier, New York 2007: 427-429.
23. VALLI VEO. The hematopoietic system. MAXIE MG. (Ed). **Jubb, Kennedy, and Palmer's Pathology of Domestic Animals**. 6 ed, vol. 3. Saunders Elsevier, Philadelphia 2016:126.