BJVP
Brazilian Journal of Veterinary Pathology
ISSN 1983-0246

Case Report

Ectopic Pregnancy in a California sea lion (*Zalophus californianus*)

Mauricio Seguel[1*], Barbara Halaska[2], Shawn Johnson[2], Nicole Gottdenker[1]

[1]Department of Pathology, College of Veterinary Medicine, University of Georgia, Athens Georgia, USA.
[2]The Marine Mammal Center, 2000 Bunker RD, Sausalito, California, USA.
***Corresponding author**: Department of Pathology, College of Veterinary Medicine, University of Georgia, Athens Georgia, 30602, USA.
Tel: +17065830476 E-mail: mseguel@uga.edu

Submitted September 3rd 2016, Accepted October 2nd 2016

Abstract

Ectopic pregnancies have been rarely reported in animals and little is known in wildlife species regarding the capacity of the placenta to support extrauterine fetal development. An adult, female, free-ranging California sea lion (*Zalophus californianus*) died suddenly after four weeks in a rehabilitation center. At necropsy, a partially mummified fetus, covered by light-brown membranes occupied the lower third of the abdominal cavity. The maternal uterus was intact and a prominent corpus luteus enlarged the right ovary. The fetal membranes epithelium had immunohistochemical profile identical to normal sea lion placenta but was different from the staining profile of sea lion omentum. The findings in this case suggest that partial placentation occurred in the abdominal cavity, highlighting the potential of otariids placenta to support ectopic fetal development. Acute toxic shock with disseminated intravascular coagulation was considered the most likely cause of death of the adult female sea lion.

Key words: California sea lion, ectopic pregnancy, pathology, placenta, *Zalophus californianus*.

Introduction

The term "ectopic pregnancy" has been used in the veterinary and medical literature to denote the presence of a fetus elsewhere in the body rather than within the uterine cavity (3, 5, 8). The most common places of extra-uterine fetal location are the oviduct in primates (tubal ectopic pregnancy) and the abdominal cavity in domestic animals (3, 5, 8).Abdominal ectopic pregnancies can be classified as primary or "true ectopic pregnancies" when there is implantation, placentation and development of an embryo in the peritoneal cavity; or secondary when the conceptus is moved from the uterus to the abdominal cavity, usually as a consequence of trauma (5).

Ectopic pregnancy is a rare condition in animals with a few anecdotal reports in non-human primates, cows, horses, sheep, cats, hamsters, rats, mice and rabbits (3, 5, 8). Among wild animals, there is a report of an abdominal fetus in a Steller sea lion (*Eumatopias jubatus*) and the description of a mummified fetus in the abdominal cavity of northern fur seal (*Callorhinus ursinus*), however further studies to confirm viability of the fetus or fetal membranes were not reported (9, 10), and it is unknown if those events represented only translocation from the conceptus into the uterus due to dystocia or trauma, or if partial fetal development occurred in the abdomen. A recent report on a California sea lion (*Zalophus californianus*) described a case of ectopic pregnancy in a captive old female as consequence of choriocarcinoma (4). Although the mentioned study included immunohistochemical assessment of the tumor for pancytokeratin it did not provide additional information on the vitality of fetal membranes and immunohistochemical markers useful to differentiate placental tissue from similar structures in pinnipeds. We describe the occurrence of an ectopic pregnancy in a free-ranging California sea lion (CSL) with histologic and immunohistochemical evidence of abdominal placentation.

 All rights reserved 2007.

Case report

An adult female CSL was found stranded on July 2014 in San Luis Obispo County, California, United States of America. The animal presented occasional seizures and was given 7.4 mg Lorazapam intramuscular (IM), 294 mg Phenobarbital IM and 14.7 mg dexamethazone IM at the San Luis Obispo Satellite facility. The animal was transported to the main Marine Mammal Center (TMMC) facility at Sausalito, California, where she was placed on the domoic acid toxicosis treatment protocol which included 294 mg Phenobarbital IM twice a day for 7 days and 7.4 mg dextamethazone IM once a day for 3 days. During the 4 weeks of stay at TMMC the sea lion neurological scores improved notoriously (6), and the animal met the criteria for release (clinically normal with hematology and serum chemistry values within reference rage) (6). However, a day before the scheduled release the sea lion was found dead.

A complete postmortem examination was performed a few (2-4) hours after the animal death. At necropsy, a partially mummified fetus occupied the lower third of the abdominal cavity (fetal standard length 53 cm). Thick light-brown membranes with prominent blood vessels covered the fetus and were firmly attached to the greater omentum, mesentery and the caudal portion of the liver capsule (Fig.1a). The ventral abdominal wall of the fetus was markedly attached to the external membranes and the omentum (Fig.1b), precluding complete dissection of the umbilical cord; however prominent blood vessels (assumed to be umbilical vessels) were directed towards the fetal umbilical region and penetrated partially into the intact fetal abdominal cavity. Fetal internal organs were partially mummified but in normal number and location. The adult female uterus was intact and a 2.0 x 3.0 cm corpus luteus enlarged the right ovary.

Maternal tissues (lung, liver, kidney, reproductive organs, spleen, mesenteric lymph nodes, small intestine, omentum, brain, thyroids, adrenal glands), fetal sections of skin, liver, lung, spleen and intestine, and all membranes that covered the fetus were fixed in 10% buffered formalin and routinely processed for histopathology. Selected sections of maternal lung were stained with Giemsa, toludine blue, Luna and Gram stains and Periodic Acid Schiff reaction. Immunohistochemical staining was performed in the membranes that covered the fetus and the maternal omentum, mesentery and intestine usingseveral antibodies and protocols detailed in Table 1. Additionally, a section of sea lion placenta from a female with normal late-term pregnancy was included as positive control.

Sterile swabs, collected from the maternal lung, liver and spleen, were plated in blood and McConkey agar. There was no bacterial growth after 48 hours of incubation in any of the plates.

The membranes covering the fetus consisted of numerous villous projections of fibrovascular stroma lined by a simple cuboidal epithelium with rare syncytial cells (Fig. 1c). The stroma contained numerous, prominent congested blood vessels and scattered lymphocytes, plasma cells, macrophages, mineral debris, siderophages, plump fibroblasts and occasionally, syncytial cells with up to 20 nuclei. The mesentery and omentum were lined by plump mesothelial cells. The fetal skin was viable while most other tissues were partially autolyzed (mummified). In the maternal right ovary there was a prominent, well-developed corpus luteum and the endometrium had histologic features of embryonic diapause and pregnancy according to histologic criteria for CSL described by Colegrove et al. (2).

The epithelium of the membranes covering the fetus and the control CSL placenta had marked, diffuse, cytoplasmic positive staining for cytokeratin 5&6;

Table 1. Detail of antibodies and methods used for immunohistochemical stains.

Antibody	Antibody clone	Antigen retrieval method	Dilution primary antibody
Cytokeratin 5&6[a]	Mouse, anti-human, monoclonal	Citrate pH 6.0	RTU
Cytokeratin 8&18[b]	Mouse, anti-human, monoclonal	Pepsin	1:100
Cytokeratin HMW[a]	Mouse, anti-human, monoclonal	Reveal	1:100
Vimentin[c]	Mouse, anti-human, monoclonal	Citrate pH 6.0	1:3000
CD18[d]	Mouse, anti-dog, monoclonal	Citrate pH 6.0	1:50
Iba1[e]	Rabbit, anti-human, polyclonal	Citrate pH 6.0	1:400
Alpha-Inhibin[b]	Mouse, anti-human, monoclonal	Citrate pH 6.0	1:400

Manufacturers: a=Cell Marque®, b= Biocare®, c=Biogenex®,d= Dr. Peter Moore, e=Wako Chemicals®
RTU= Ready to use antibody, not dilution needed.

moderate, multifocal, cytoplasmic positive staining for vimentin and in some areas occasionalepithelial cells had moderate, diffuse, cytoplasmic staining with cytokeratin 8/18. Epithelial and stromal syncytial cells had a similar cytokeratin immunohistochemical profile but they were negative for vimentin (Fig. 1e), Iba-1, and CD18 and positive for alpha-inhibin (Fig. 1f). The omentum and mesentery mesothelium had marked diffuse cytoplasmic positive staining for cytokeratin 8/18, high molecular weight cytokeratins and vimentin; mild, multifocal positive cytoplasmic staining for cytokeratin 5&6; and they were negative for Iba-1, CD18 and alpha inhibin

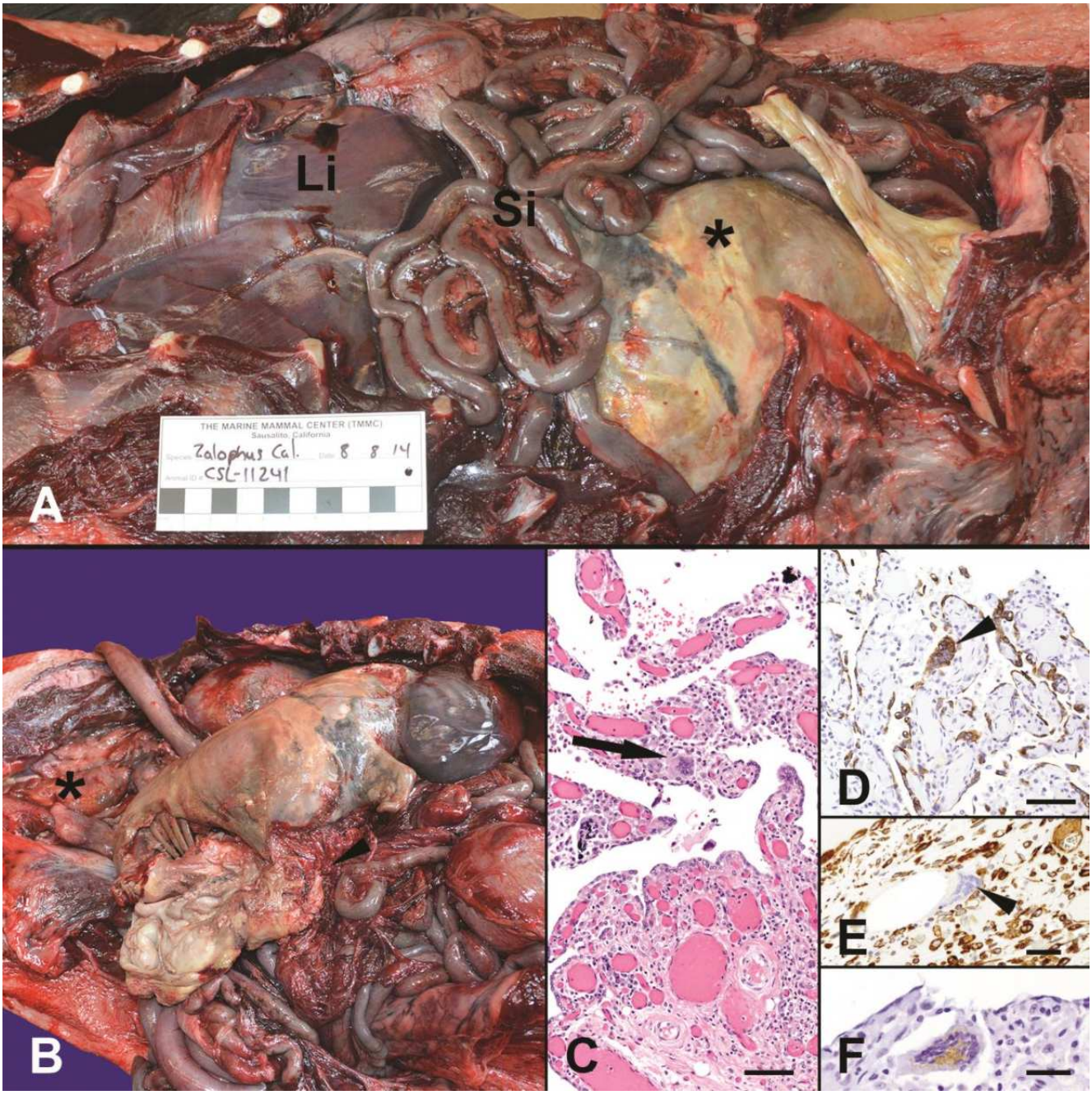

Figure 1. Ectopic pregnancy in a California sea lion (*Zalophus californianus*). A, There is a partially mummified full-term fetus in the abdominal cavity covered by thick light-brown membranes (asterisk) attached to the small intestines (Si) mesentery and caudal portion of the liver (Li) capsule. B, The ventral abdominal wall of the fetus is markedly attached to the external membranes and the omentum. Note the prominent blood vessels in the fetus umbilical region and the intact uterus (asterisk). C, The fetal membranes are composed of villous fibrovascular projections lined by cuboidal epithelium and occasional syncytial cells (arrow). Hematoxylin and eosin stain. Bar = 80 µm. D, The fetal membranes epithelium and syncytial cells (arrow head) have marked, diffuse cytoplasmic positive staining for cytokeratin 5&6. Immunohistochemistry

for cytokeratin 5&6 counterstained with hematoxylin. Bar = 25 µm. E, Syncytial cells (arrow head) are negative for vimentin staining and adjacent leukocytes have marked, diffuse, cytoplasmic positive staining. Immunohistochemistry for Vimentin antigen counterstained with hematoxylin. Bar = 25 µm. F, Occasional syncytial cells have moderate cytoplasmic positive staining for alpha-inhibin. Immunohistochemistry for alpha-inhibin antigen counterstained with hematoxylin Bar = 50 µm.

Additional histologic findings in the adult female CSL included a severe acute fibrinohemorrhagic broncopneumonia with microvascular fibrin thrombi, multifocal glomerular and adrenocortical hemorrhages with fibrin thrombi, moderate microfilaremia (*Dipitalonema odendhali*) and mild to moderate hippocampal and parietal cortex neuronal loss with microgliosis (compatible with previous domoic acid toxicosis).

Discussion

Macroscopic, histological and immuno-histochemical assessment of maternal and fetal tissues suggests that the fetus was covered by vital placenta. However it is unclear if the placenta and the fetus partially developed in the abdominal cavity or if they were transferred from the uterus once completely developed. Although the uterus was intact we cannot completely rule out a rupture weeks before the necropsy as the uterus can healvery quickly. Despite this fact, the vitality of fetal membranes suggest that in pinnipeds an endometrial-placenta interaction is not necessary to maintain proper circulation to the placenta and could at least in part sustain fetal demands.

Ectopic pregnancies have been rarely reported in wild animals and to our knowledge the 3 cases mentioned in the literature with suspected or confirmed ectopic pregnancies, also occurred in otariids (4, 9, 10). However, in two of those cases the animals had twin pregnancies with one fetus in the uterus and other in the abdominal cavity and in other the ectopic pregnancy was the result of a choriocarcinoma. Additionally these reports did not report on the vitality of normal fetal membranes. Twin pregnancies and uterine neoplasms are extremely rare in pinnipeds and in this case there was no evidence of earlier implantation of other fetus in the uterine mucosa or any histological abnormality in the multiple sections of uterus examined. The overrepresentation of otariids in reports of abdominal fetuses in wildlife could be due to more necropsies being performed in this animal group compared to other wildlife species or physiological predisposition. Sea lions have a lobulated, zonary, labyrinthine endotheliocorial placenta which in theory does not require specific interaction between trophoblast and endometrium for implantation (7). Additionally, implantation in pinnipeds is delayed between 2 and 3 months (embryonic diapause) (1), increasing the possibility of embryo transfer to the abdomen. Furthermore, otariids have long gestation periods and late pregnancy overlaps with the reproductive season in rookeries (1), increasing the likelihood of trauma and translocation of the conceptus to the abdominal cavity.

Abdominal radiographs, which could have identified the abdominal fetus pre-mortem, were not performed in this case. A premortem diagnosis of ectopic pregnancy probably would have changedthe clinical managementat the rehabilitation center (e.g. electing euthanasia due to the attachment of the fetus to major organs).

Postmortem findings indicate that the adult female CSL died most likely of acute toxic shock with disseminated intravascular coagulation. It is possible that autolyzed fetal tissues could have caused toxemia to the mother, although other sources of septic shock such as the hyperacute bacterial bronchopneumonia cannot be totally ruled out, however the negative lung culture results and lack of bacteria microscopically make this possibility less likely.

This report highlights the capability of otariid seals to present with ectopic pregnancy. In this case, as described in primates, the ectopic fetus was a serious condition with likely lethal consequences for the mother..

References

1. BONES DJ., CLAPHAM PJ., MESNICK SL. Life histories and reproductive strategies. HOELZEL AR (Ed). **Marine mammal biology: an evolutionary approach.** John Wiley & Sons, Oxford 2009: 278-324.
2. COLEGROVE KM., GULLAND F., NAYDAN DK., LOWENSTINE LJ. The normal genital tract of the female California sea lion (*Zalophus californianus*): Cyclic changes in histomorphology and hormone receptor distribution. **Anat. Rec.**, 2009, 292, 1801-1817.
3. CORPA JM. Ectopic pregnancy in animals and humans. **Reproduction**, 2006, 131, 631-640.
4. FRAVEL V., LOWENSTINE L., KOEHNE A. Ectopic pregnancy with associated gestational choriocarcinoma in a California sea lion (*Zalophus californianus*). **Dis. Aquat. Organ.**, 2016, 120, 159–164.
5. GIL PS., PALAU BP., MARTÍNEZ JM., PORCEL JO., ARENAS JMC. Abdominal pregnancies in farm rabbits. **Theriogenology**, 2004, 62, 642-651.
6. GULLAND FMD., HAULENA M., FAUQUIER D., LANGLOIS G., LANDER ME., ZABKA T., DUERR R. Domoic acid toxicity in Californian sea lions

 All rights reserved 2007.

(*Zalophus californianus*): clinical signs, treatment and survival. **Vet. Rec.**, 2002, 150, 15, 475-480.

7. NORÉN H., LINDBLOM BO. A unique case of abdominal pregnancy: what are the minimal requirements for placental contact with the maternal vascular bed? **Am. J. Obstet. Gynecol.**, 1986, 155, 394-396.
8. ROSSET E., GALET C., BUFF S. A case report of an ectopic fetus in a cat. **J. Feline Med. Surg.**, 2011, 13, 610-613.
9. SPRAKER TR., LANDER ME. Causes of mortality in northern fur seals (*Callorhinus ursinus*), St. Paul Island, Pribilof Islands, Alaska, 1986-2006. **J. Wildl. Dis.**, 2010, 46, 450-473.
10. TALENT L., TALENT C. Extrauterine Fetus in Steller Sea Lion, *Eumetopias-jubata*. **California Fish and Game**, 1975, 61, 233-234.

 All rights reserved 2007.