Braz J Vet Pathol, 2017, 10(1), 2 – 9. DOI: 10.24070/bjvp.1983-0246.v10i1p2-9

BJVP
Brazilian Journal of Veterinary Pathology
ISSN 1983-0246

Original full paper

Canine tarsal gland epitheliomas and adenomas: a retrospective study of 290 cases in Brazil

Juliana Werner[1,2]*, Christiane M. C. Moura[1,2], Pedro R. Werner[2], Fabiano Montiani-Ferreira[1]

[1]Universidade Federal do Paraná (UFPR), Departamento de Medicina Veterinária, Curitiba, PR, Brazil.
[2]Werner & Werner Veterinary Pathology Laboratory, Curitiba, PR, Brazil.
***Corresponding Author:** R. Tomazina, 363 - Curitiba, PR, Brazil. CEP 80540-160. Phone: 55 41 3352-7271, Fax: 55 41 3352-7271.
E-mail: juliana.werner56@gmail.com

Submitted December 16th 2016, Accepted February 13th 2017

Abstract

A total of 290 cases of tarsal gland adenomas and epitheliomas from canine patients were analyzed to determine the frequency and to better characterize their histopathological features. Tissue samples were examined in two veterinary pathology laboratories in Curitiba, Brazil, which receive samples from all over the country. Tarsal epitheliomas were significantly more frequent than tarsal adenomas (77.9% and 20.7%, respectively). In four cases (1.4%), the lesion contained both types of neoplasms. A total of 39 breeds were represented. The most common breeds were: English cocker spaniel (12.4%), poodle (10.3%) and Labrador retriever (9.3%). Mixed breed dogs represented 13.1% of the total. The upper eyelids were most commonly affected (65.2%), males and females were equally represented and there did not appear to be a predilection for either side of the face. Mitotic figures were most common in epitheliomas. The pigmented subtype was the most common form of epithelioma (59.7%). Whereas within the adenomas, the classic subtype (without inflammation or pigmentation) was the most common form (61.7%); and the inflamed subtype was also highly represented (20.0%).

Key words: adenoma, epithelioma, histopathology, tarsal gland, dog.

Introduction

The eyelids of dogs can be affected by a variety of neoplasms that are typically minimally invasive and respond well to simple surgical excision (1, 22). The two most commonly diagnosed eyelid neoplasms in dogs are the tarsal adenomas and epitheliomas (25), also known as tarsal gland adenomas and epitheliomas (Fig. 1). The tarsal glands (*glandulae tarsales*) are modified sebaceous glands of the eyelids responsible for producing the lipid phase of the tear film (12), and neoplastic transformation of these glands can affect ocular health. Disorders such as hordeolum or chalazion can secondarily occur if there is obstruction and/or inflammation of the ducts of affected tarsal glands; lagophthalmos, if eyelid closure is impaired; and keratitis or less commonly ulcers also may develop as a direct result of the tumor rubbing the corneal surface. Removal of these tumors is indicated (14, 17) to avoid such potential complications and to allow analysis and histopathological diagnosis of the tumor (10).

In the past tarsal gland tumors and cutaneous sebaceous tumors were essentially studied together (9). Sebaceous adenomas and sebaceous epitheliomas of the skin are benign tumors, but sebaceous epitheliomas can be locally aggressive and in some cases recur after surgical excision (9). Even though tarsal gland tumors are histologically similar to cutaneous sebaceous tumors (13), most authors currently consider tarsal tumors separately from its cutaneous counterparts, mainly because all reported instances of metastases from epitheliomas have been from cutaneous sebaceous epitheliomas (9) and not from canine tarsal epitheliomas (13, 22).

 All rights reserved 2007.

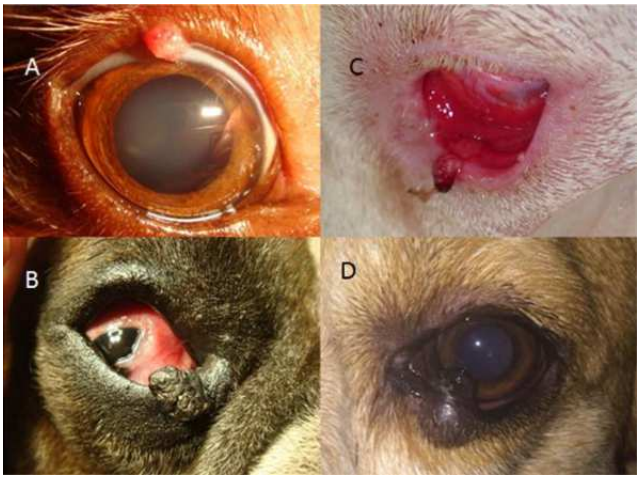

Figure 1. Representative clinical photos of adenomas and epitheliomas of the tarsal gland. (A) An eight-year old female poodle with a small (3 mm diameter), exophytic and unpigmented tarsal adenoma in the right superior eyelid. (B) A six year old male boxer with a pigmented and relatively large tarsal adenoma (6 mm in diameter) in the right lower eyelid. (C) An eight-year old Great Dane with a small (2 mm diameter), exophytic and focally ulcerated tarsal epithelioma. (D) A seven-year old mixed-breed dog with a large (8 mm diameter) and pigmented tarsal epithelioma. Note that the clinical appearance alone is not a good parameter to differentiate between these two types of tarsal gland tumors.

Macroscopically, tarsal adenomas and epitheliomas of the eyelid are very similar and are firm lobular nodules extending from the eyelid margin, rarely exceeding 5 mm in diameter (9) with or without pigmentation, inflammation and/or ulceration of the overlying skin. Microscopically, both tumor types have nodules of epithelial cells extending to the dermis/substantia propria. Tarsal gland adenomas consists of lobules of grouped meibocytes (sebocytes) with abundant vacuolated cytoplasm, showing gradual and orderly maturation with a prevalence of completely "lipidized" (mature) cells. In tarsal adenomas it is common to observe degeneration of mature meibocytes (meibum formation) in the center of the neoplastic lobes due to the holocrine nature of the gland (9). tarsal epitheliomas, however, consist of lobules composed of sheets and anastomosing trabeculae of predominantly smaller and more tightly packed reserve cells with random foci of orderly sebaceous maturation (4, 10). Either type of tumor can be endophytic, exophytic or both. Ulceration, inflammation and pigmentation can be observed histologically in both types of tumors, but pigmentation is considered more common in tarsal epitheliomas than in the tarsal adenomas (4, 10). The scientific literature reports that in dogs' eyelids, the prevalence of tarsal adenomas is higher than that of epitheliomas in the United States of America (USA) and South America (2, 7, 8, 11, 15, 20, 22). Some authors even consider tarsal epitheliomas uncommon or rare (7). However, in two veterinary pathology services in Brazil the reverse was observed with eyelid tarsal gland epitheliomas being much more common than adenomas - a finding reported in a previous study of only 40 cases (18).

In order to confirm the higher frequency of tarsal epitheliomas than adenomas in the eyelids of dogs in Brazil and to better establish the standard histopathological features of these neoplasms, a larger survey was conducted combining data from two veterinary pathology laboratories over a longer period of time and including a significantly larger number of cases.

Materials and methods

Records of 290 cases of eyelid tarsal gland adenomas and epitheliomas in dogs diagnosed in samples submitted to two Brazilian veterinary pathology laboratories offering ocular pathology services were compiled and analyzed. One of these centers is a private laboratory (Laboratory Werner & Werner, Curitiba-PR); and the other is linked to the Federal University of Paraná (Comparative Ophthalmology Laboratory, Curitiba-PR). Samples were submitted between 2008 and 2015 from all over Brazil, and included male and female dogs of many different breeds and ages.

Samples were fixed in 10% neutral buffered formalin for 2 to 7 days. After macroscopic examination, which included the measurement of the largest axis of the tumor, all fixed surgical samples were trimmed, the fragments were embedded in paraffin and 5 μm sections were stained with hematoxylin and eosin (H&E). The neoplasms were classified as tarsal gland epitheliomas or adenomas according to standard histological diagnostic criteria (9). By definition, reserve cells have scant, eosinophilic cytoplasm and slightly hyperchromatic, ovoid nuclei with inconspicuous nucleoli. Mature sebocytes have moderate, clear cytoplasm with numerous, delicate lipid vacuoles with more centrally-located nuclei with crenated margins and small nucleoli. The same pathologist reviewed all the samples. Other factors were considered such as tumor growth patterns, differentiation and cell maturation patterns and forms (presence of reserve cells, mature cells and lipidized cells); cell organization patterns (presence of trabeculae or lobules); number of mitotic figures per 10 high-power fields (400x); and other changes such as the presence of skin ulceration, inflammatory reaction or pigmentation. When reserve and mature cells were present in equal proportions a diagnosis of tarsal epithelioma was made. In order words: this was the cut-off point, less mature cells than that makes it an epithelioma and more than that an adenoma. Mitotic figures were evaluated and expressed as the mean of 10 high power fields analyzed (Olympus BX-45 diagnostic microscope, high power field diameter of 0.52 mm). Ordinal grade cut-offs for mean

mitotic figure counts were then created: Absent (Grade 0); Mean 0-0.9 (Grade 1); Mean 1-1.9 (Grade 2): Mean 2-3 (Grade 3). When inflammation or pigmentation was present, tumors were further divided into "inflammatory" or "pigmented" subtypes. When inflammation and pigmentation were not prominent features, the neoplasm was considered "classic". The typical type of inflammation present was lipogranulomatous. A diagnosis of tarsal adenoma and epithelioma in the same sample was made in samples in which different lobules within a tumor showed a predominance of basaloid reserve cells whereas in other lobules differentiated cells predominated.

Results were tabulated and statistically analyzed using the chi-square test. Data were deemed significant when *P* values were less than 0.05.

Results

The number of cases from the official geopolitical region of Southern Brazil, which comprises the States of Rio Grande do Sul (RS), Santa Catarina (SC) and Paraná (PR) (221/290 cases, or 76.2%) was significantly higher (*P*= 0.0001) than the numbers from the rest of the country combined (69/290 cases, or 23.8%). Fig. 2 provides the number of cases of eyelid tarsal gland adenomas and epitheliomas according to geographical location within Brazil.

The diagnosis of tarsal epitheliomas was significantly more common not only in the south area of Brazil – PR+SC+RS (175/221) as well as in the rest of the country (50/64) P≤ 0.006 as well (Fig. 2).

The diagnosis of adenomas and epitheliomas together corresponded to (290/797) 36.4% of the laboratory´s canine ocular pathology caseload. In 177 cases the affected side of the face was reported, 92/177 (52.0%) occurred on the left (10 adenomas and 82 epitheliomas) and 85/177 (48.0%) on the right side (19 adenomas and 66 epitheliomas). There were 143 (49.3%) submissions from males and 142 (49.0%) from females, in five cases the sex of the patient was not reported. There were no significant differences between reported sexes or the side of the face affected, either for epitheliomas or for adenomas (*P* > 0.05).

Of the 178 of the cases for which anatomic information was available, 116 (65.2%) were removed from the upper eyelid, and 62 (34.8%) from the lower eyelid. This difference was statistically significant (*P* = 0.0002).

The mean largest axis of the adenomas was 6.3 ± 1.9 mm and of the epithelioma was 6.7 ± 3.3 mm. Adenomas and epitheliomas had the same median and mode, 6 and 5 mm, respectively. There were no significant differences between the mean of the largest axis of the two tumors (*P* = 0.60).



Figure 2. Distribution of the 285 cases of eyelid tarsal gland adenomas and epitheliomas in dogs submitted from 2008 to 2015 according to the state of origin within Brazil. The total number of cases was 290; however, in one case there was no information about the geographic origin. AM- Amazonas; PA- Pará; BA- Bahia; CE- Ceará; GO- Goiás; MA- Maranhão; MS- Mato Grosso do Sul; MG- Minas Gerais; PB- Paraíba; PR- Paraná; PE- Pernambuco; RJ- Rio De Janeiro; RN- Rio Grande Do Norte; SC- Santa Catarina; SP- São Paulo; SE- Sergipe. The numbers in brackets represent the total number of cases from that state, followed by the numbers of adenomas (Ad) and epitheliomas (Ep). In the South, in the state of Paraná (PR), the city of Curitiba where the two veterinary pathology laboratories are located, is marked with an asterisk (*).

The average age of the animals in this study was 9.4 years, median and mode of 10 years; with minimum age of 3 years and maximum age of 16 years. The most commonly affected breeds were: cocker spaniel (35 cases, 12.1%); poodle (32 cases, 11.0%); Labrador retriever (28 cases, 9.7%); and mixed breed dogs (38 cases, 13.1%). In nine cases, the breed was not reported, and the remaining 148 cases were distributed among 36 other different breeds. Epitheliomas were diagnosed in 33 (94.3%) samples of the cocker spaniels, in 28 (82.1%) of the Labrador retrievers and in 25 (78.1%) of the poodles. Additionally, within samples from shih-tzus and Lhasa apsos combined (33 animals), 29 (90.6%) received a diagnosis of epithelioma.

Table 1 shows the descriptive statistical analysis for the histological characteristics found in the survey. The tarsal epitheliomas (n = 226) were present at significantly higher numbers (*P* = 0.00001) than the tarsal adenomas (n = 60). The classic subtype (without inflammation or pigmentation) was the most common form of tarsal adenoma (*P* = 0.002). When inflammation was recognized, it was significantly more common in adenomas than in

epitheliomas (P = 0.04). The pigmented epithelioma (Fig. 3C) was significantly more common than any other type of epithelioma (P < 0.05), followed by the classic type (no inflammation or pigmentation). Pigmented and inflamed epitheliomas were significantly less common (p < 0.05). Pigmented epitheliomas were significantly more common than pigmented adenomas (P = 0.004).

Table 1. Prevalence of canine eyelid tarsal epithelioma, tarsal adenoma or both tumors in the same sample at two laboratories (Werner & Werner Laboratory and Comparative Ophthalmology Laboratory at UFPR) in Brazil, during a seven-year period (2008 to 2015).

Neoplasia	Histopathological subtypes	Number	Subtype % within all samples	Subtype % within the adenomas/epitheliomas
Adenoma	Classic	37	12.8	61.7
	Inflamed	12	4.1	20.00
	Pigmented	8	2.8	13.3
	Pigmented + Inflamed	3	1.03	5.00
	TOTAL ADENOMAS	60	20.7	100.00
Epithelioma	Classic	53	18.3	23.4
	Inflamed	21	7.2	9.3
	Pigmented	135	46.5	59.7
	Pigmented + Inflamed	17	5.9	7.5
	TOTAL EPITHELIOMAS	226	77.9	100.00
	ADENOMAS + EPITHELIOMAS	286	98.6	100.00
Adenoma and Epithelioma	Adenoma and epithelioma in the same sample	4	1.4	100.00
	TOTAL	290	100.00	100.00

The classic subtype (without inflammation or pigmentation) (Fig. 3A) was the most common form of tarsal adenoma (P = 0.002). Nevertheless, the inflamed type (Fig. 3B) occurred significantly more commonly in adenomas than in epitheliomas (P = 0.04).

Concerning the mitotic index analysis, no atypical mitoses were observed in any of the adenomas or epitheliomas. In 57 cases of the 60 adenomas evaluated, no mitotic figures were found (Grade 0). In the three remaining samples, a Grade 1 mitotic index was found. From the 226 epitheliomas analyzed, 32, 162, 21 and 14 tumors had Grade 0, 1, 2, 3 respectively. Thus, a significantly higher number of adenomas showed no mitotic figures compared to epitheliomas (P = 0.0001). In the same manner, the presence of 1 or more mitotic figures per high power field (classified here as tumors of Grades 1-3) was significantly more common in epitheliomas than in adenomas (P = 0.0001). Regarding the tumor samples containing both adenomas and epitheliomas, one was Grade 0, two were classified as Grade 1 and one as Grade 2.

Discussion

The large number of samples submitted from southern states of the country probably reflects the fact that the laboratory is located in this area and generally receive more cases from geographically closer locations.

The significantly higher incidence of tarsal gland neoplasia (epitheliomas and/or adenomas) on the upper (rather than lower) eyelid reported in this study is consistent with literature reports and is probably due to a higher density of tarsal glands in the upper eyelid (16).

Dogs affected by tarsal gland neoplasia were middle-aged to old as reflected by the mean age in our study and in previous studies. This result confirms data from the literature in which a typical age of 9 - 10 years is reported (1, 7, 10, 14, 17, 18, 21).

The breeds most affected by these eyelid tumors are poodles and cocker spaniels (4, 17). This finding was confirmed by the present study in which these two breeds were also the most prevalent, accounting for 22.7% of all diagnosed cases. However, it is possible that this higher prevalence merely reflects a higher prevalence of certain

 All rights reserved 2007.

breeds in the general dog population in a particular region. Considering the reference population from the laboratory, the diagnosis of tarsal epithelioma is indeed over-represented shih-tzus and Lhasa apsos since it is not a common breed listed in the laboratory´s caseload of ocular lesions. There is no convincing data in the literature of a sex predisposition for eyelid tumors and in this study; we report a similar prevalence between the sexes.

Inflammation is significantly more common in adenomas than in epitheliomas. The inflammatory reaction is caused by the presence of free keratosebaceous material (sebum or meibum) in the dermis/substantia propria (Fig. 3B). tarsal adenomas have more sebaceous differentiated cells (which can release lipids) and hence sebum accumulates in glands and ducts, frequently causing distention and rupture. The release of sebum into the dermis incites a severe foreign body inflammatory reaction (lipogranuloma).

The pigmented subtype was the most common form of epithelioma (Fig. 3C), and epitheliomas were more likely than adenomas to be pigmented. It is clear that epitheliomas have a significantly greater population of basal cells, which defines this tumor type. It is known that melanocytes are distributed throughout the reserve cells of an epithelium, including the epidermis and the foliculosebaceous units, pigment in epitheliomas is not located just in melanocytes but also within the basaloid reserve cells themselves (and melanophages) (9) and these facts may explain the greater numbers of epitheliomas being pigmented.

In this study, the results relating to age and breed of affected animals and the location of tarsal adenomas and epitheliomas are similar to those reported in the literature, including in the United States of America (USA). However, there is a notable difference from those studies from the USA in that the number of tarsal gland epitheliomas was much higher than adenomas in our study. According to the literature, tarsal gland adenomas are the most prevalent neoplasia in dogs' eyelids (2, 7, 11, 15, 20, 22). However, in the present investigation as well as in the previous pilot study from the same group (18), tarsal gland epitheliomas were significantly more prevalent than the tarsal gland adenomas (77.9% and 20.7%, respectively). In order to possibly explain the difference between the data obtained here and the data published in the literature, the authors hypothesize two scenarios: 1) the amount of ultraviolet (UV) radiation received in the individuals from different populations investigated and 2) the different criteria used by pathologists in the histopathological classification of the tarsal tumors, both of which are discussed below.

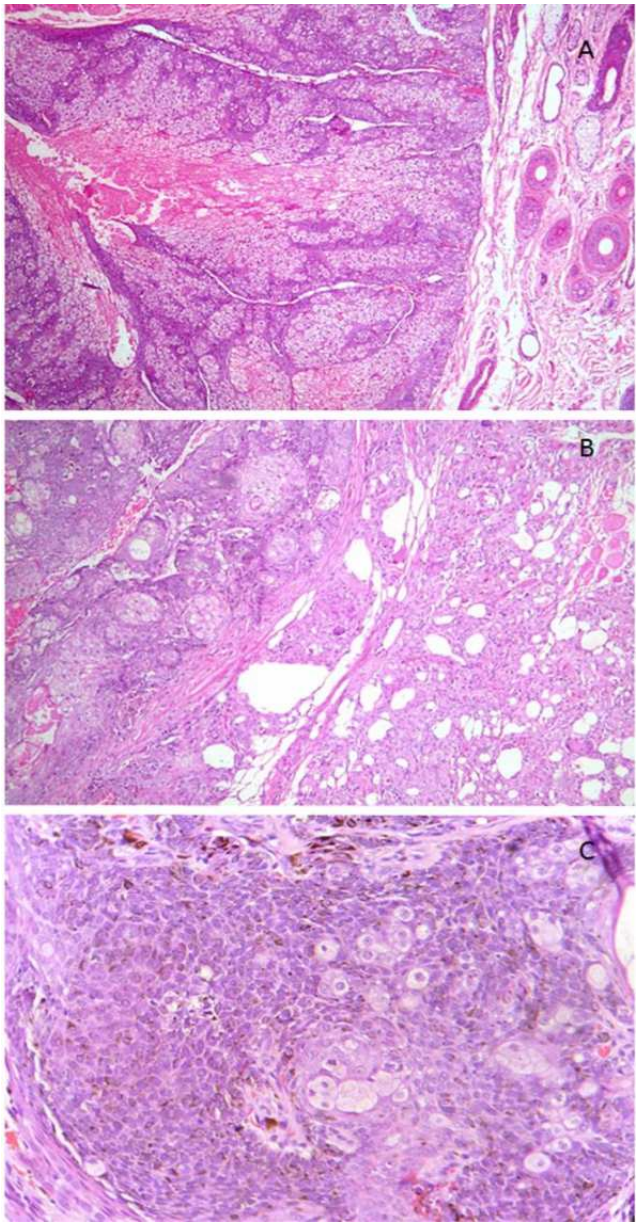

Figure 3. Photomicrographs of representative cases tarsal tumors reported here. (A) Sebaceous adenoma from the tarsal gland of the eyelid of a dog. A well demarcated neoplastic mass composed mostly of well-differentiated lipidized (clear) cells forming lobules expands the substantia propria of the eyelid. Hematoxylin and eosin (100x). (B) Inflamed sebaceous adenoma from the tarsal gland of the eyelid of a dog. An accumulation of numerous macrophages surrounding clear spaces (lipid lakes) lies adjacent to the adenoma (lipogranulomatous inflammation). Hematoxylin and eosin (100x). (C) Pigmented tarsal epithelioma in a dog. Note that the majority of cells are smaller, more tightly packed reserve cells, many of which are pigmented, and smaller numbers of well-differentiated sebocytes/meibocytes with abundant vacuolated cytoplasm. Hematoxylin and eosin (200x).

It is evident that hyperplasia and neoplasia are not always easily distinguishable. Even though the pathogenesis of tarsal gland hyperplasia is not well understood and its origin as either a reactive or neoplastic process is not well established, it is at least known that ultraviolet radiation is a cofactor (among others) for the development of sebaceous gland hyperplasia of the skin (26). These studies are from the medical literature (human medicine), there are no similar studies in small animals to reflect the effect of UV light on the development of tarsal gland tumors in dogs. The country of Brazil is located in the tropical and subtropical areas of the southern hemisphere, where solar radiation is intense and ozone concentrations are naturally lower (3). The ultraviolet radiation index (UVI) indicates the amount of UV radiation at any given time and ranges from low (1 – 2 UVI) to extreme (11+ UVI) with the higher values being more dangerous. UVIs observed in Brazil are high (between 5 and 11 or higher), reaching the highest UVI scales reported by the World Health Organization (WHO) (3). The Brazilian UVIs are similar to the Australian ones, being much higher than those observed in countries of the northern hemisphere (3, 5), since the Earth's orbit brings countries in the southern hemisphere closer to the sun the southern summer than countries in the northern hemisphere during northern summer (5). Therefore, the authors believe that it would be interesting to investigate the prevalence of both types of canine eyelid neoplasms in other countries that experience high levels of UVIs.

Although tarsal adenomas and tarsal epitheliomas are clinically similar, histopathologically they are quite distinct. In classic tarsal adenomas most proliferating cells are mature and are completely "lipidized" i.e. the cells exhibit features of mature meibocytes and are organized into defined lobes (Fig. 3A). On the other hand, in tarsal epitheliomas, the majority of cells typically resemble the basaloid reserve cells at the periphery of normal tarsal glands with only individual cells or clusters of cells showing sebaceous maturation. In epitheliomas, there is no formation of distinct sebaceous lobules, and mitotic figures are more common in epitheliomas than in adenomas (17). It is important to bear in mind that the distinction between adenomas and epitheliomas is highly subjective, thus it depends on the pathologist. Objective standards to differentiate tarsal adenomas and epitheliomas are yet to be established. As an “unwritten rule”, epitheliomas should have a substantial number of basal cells. For skin tumors, however, some authors use a threshold of up to 90% of the tumor cells being of the basal type to deserve the diagnosis of tarsal epithelioma (6, 9, 13). Nevertheless, in samples seen at veterinary histopathology laboratories, a significant percentage of tarsal gland eyelid neoplasms show similar proportions of reserve and mature cells. In these cases, the authors believe that a diagnosis of tarsal epithelioma should be made. It is possible that in such cases other pathologists opt for the diagnosis of tarsal adenoma. However, it is important to remember that in the skin low-grade epitheliomatous sebaceous carcinoma is histologically similar to sebaceous epithelioma and consequently tarsal epithelioma (9), making it difficult to differentiate between them at times. In these cases, it is possible that some pathologists opt for the diagnosis of low-grade epitheliomatous sebaceous carcinoma. The authors believe that the diagnosis of low-grade epitheliomatous tarsal carcinoma should only be made in the presence of obvious signs of malignancy, in particular the presence of infiltrative margins and/or invasion of the underlying subcutis. Nevertheless, it is impossible to examine margins in many eyelid tumors since they are submitted in several fragments, so for those samples, they would be unable to be diagnosed as either benign or malignant.

As observed here, mitoses may be quite frequent in tarsal epitheliomas. However, other features of malignancy are usually not observed (13). This is an important feature to be remembered for the diagnosis of this type of tumor and it is worth mentioning that some tumors that should be diagnosed as tarsal epitheliomas have been published as carcinomas based on the number of mitoses (13, 19, 24).

The histopathological classification of sebaceous tumors is still far from being well established in both animals and people. In people, some authors suggest classifying the sebaceous tumors into six categories: 1) sebaceoma, 2) trichoblastoma with sebaceous differentiation, 3) apocrine poroma with sebaceous differentiation, 4) low grade sebaceous carcinoma, 5) sebaceous carcinoma, and 6) basal carcinoma with sebaceous differentiation (16). In veterinary dermatopathology the term "sebaceoma" has not been adopted. Moreover, human low-grade sebaceous carcinoma is very similar to what veterinary pathologists define as sebaceous epithelioma (9). It is worth mentioning that eyelid tumors in general are quite rare in humans, especially sebaceous gland carcinoma, representing 1–5.5% of all the eyelid malignancies (23).

This difficulty in establishing histopathological parameters and standards supports the hypothesis that the benign sebaceous and tarsal tumors and those of low-grade malignancy in reality may be part of a continuum (9), i.e. different morphological manifestations of the same neoplastic process from the same source and with the same causes. In this investigation, the diagnosis of four cases of simultaneously occurring tarsal adenoma and epithelioma in the same sample (Table 1) reinforces this possibility. We recognize, however, as a matter of semantics, some authors do not consider different lobules with basaloid reserve cells and lobules with differentiated cells predominate, necessarily as different tumor. Thus, a plausible hypothesis is that tarsal gland adenoma, epithelioma and low-grade epitheliomatous carcinoma reflect a spectrum of histopathological patterns of the same neoplasia. Furthermore, that spectrum can vary from tumor to tumor and even within the same tumor, depending on

the portion analyzed histopathologically. One factor that could help prove this hypothesis would be better understanding of the progression and evolution of these neoplasms. Nevertheless, such data are lacking in the literature and, for this study, there was no information as to how long tumors had been present before excision and histopathological diagnosis.

This study concludes that the frequency of tarsal epithelioma is significantly greater than tarsal adenoma in canine eyelids in Brazil. Breeds in which epitheliomas are overrepresented are Labradors, poodles, cocker spaniels, shi tzus and lhasa apso. Tarsal tumors are more likely to develop in the upper eyelids. Mitotic figures are more common in epitheliomas than in adenomas. Inflammation is more common in tarsal adenomas than in epitheliomas and pigmented cells are more common in tarsal epitheliomas than in adenomas. Some of these features have not been reported before in the veterinary ophthalmology and veterinary pathology literature. This study contributes to the knowledge of canine eyelid tumors.

References

1. Aquino SM. Management of eyelid neoplasms in the dog and cat. Clin Tech Small Anim Pract. 2007;22:46-54.
2. Bedford PGC. Diseases and surgery of the canine eyelid. In: Gelatt KN, editor. Veterinary Ophthalmology. 3rd ed. Philadelphia: Lippincott Williams & Willkins; 1999. p. 561-78.
3. Corrêa MP. Solar ultraviolet radiation: properties, characteristics and amounts observed in Brazil and South America. An Bras Dermatol. 2015;90:297-313.
4. Dubielzig RR, Ketring KL, McLellan GJ, Albert DM. Diseases of the eyelids and conjunctiva. In: Dubielzig RR, Ketring KL, McLellan GJ, Albert DM, editors. Veterinary ocular pathology: a comparative review. Philadelphia: Saunders Elsevier; 2010. p. 143-99.
5. Gies P, Roy C, Javorniczky J, Henderson S, Lemus-Deschamps L, Driscoll C. Global Solar UV Index: Australian measurements, forecasts and comparison with the UK. Photochem Photobiol. 2004;79:32-39.
6. Goldschmidt MH, Dunstan RW, Stannard AA, Von Tscharner C, Walder EJ, Yager JA. Histological Classification of Epithelial and Melanocytic Tumors of the Skin in Domestic Animals. Armed Forces Institute of Pathology. Washington; 1998. p. 106.
7. Grahn BH, Peiffer RL. Fundamentals of veterinary ophthalmic pathology. In: Gelatt KN, editor. Veterinary Ophthalmology. 4th ed. Oxford: Blackwell; 2007. p. 355-437.
8. Grahn BH, Sandmeyer LS. Diagnostic Ophthalmology. Can Vet J. 2009;50:1199-200.
9. Gross TL, Ihrke PJ, Walder EJ, Affolter VK. Sebaceous tumors. In: Gross TL, Ihrke PJ, Walder EJ, Affolter VK, editors. Skin diseases of the dog and cat. Clinical and histopathologic diagnosis. 2nd ed. Oxford: Blackwell Publishing; 2005. p. 641-64.
10. Herrera D. Enfermidades palpebrais. In: Herrera D, editor. Oftalmologia Clínica em Animais de Companhia. São Paulo: MedVet; 2008. p. 89-100.
11. Hesse KL, Fredo G, Guimarães LLB, Reis MO, Pigatto JAT, Pavarini SP, Driemeier D, Sonne L. Ocular neoplasms and annexes neoplasms in dogs and cats in Rio Grande do Sul: 265 cases (2009-2014). Pesq Vet Bras. 2015;35:49-54.
12. Jones TC. Órgãos especiais dos sentidos. In: Jones T, Hunt RD, King NW, editors. Patologia Veterinária. São Paulo: Manole; 2000. p. 1322-53.
13. Labelle AL, Labelle P. Canine ocular neoplasia: a review. Vet Ophthalmol. 2013;16:3-14.
14. Maggs DJ. Eyelids. In: Maggs D, Miller P, Ofri R, Saint Louis MO, editors. Slatter's fundamentals of veterinary ophthalmology. 5th ed. Philadelphia: Elsevier Saunders; 2013. p. 110-39.
15. Martin CL. Ophthalmic disease in veterinary medicine. London: Manson Publishing; 2009. 512p.
16. Misago N, Mihara I, Ansai S, Narisawa Y. Sebaceoma and related neoplasms with sebaceous differentiation: a clinicopathologic study of 30 cases. Am J Dermatopathol. 2002;24:294-304.
17. Montiani-Ferreira F, Wouk AFPF, Lima AS, Klein JA, Muzolon P. Neoplasias oculares. In: Daleck CR, Nardi AB, Rodaski S, editors. Oncologia em Cães e Gatos. São Paulo: Roca; 2008. p. 293-309.
18. Olbertz L, Dea RC, Souza ALG, Kleiner JA, Pachaly JR, Montiani-Ferreira F. Estudo retrospectivo de 40 epiteliomas e adenomas das glândulas sebáceas tarsais nos anexos oculares de cães da cidade de Curitiba, Paraná. Medvep: Ver Cient Med Vet Peq Anim Estim. 2013;10:338-41.
19. Peiffer RLJ, Simons KB. Ocular Tumors in Animals and Humans. Iowa State University Press; 2002. p. 461.
20. Roberts SM, Severin GA, Lavach JD. Prevalence and treatment of palpebral neoplasms in the dog: 200 cases (1975-1983). J Am Vet Med Assoc. 1986;189:1355-9.
21. Samuelson DA. Ophthalmic anatomy. In: Gelatt KN, editor. Veterinary Ophthalmology. 4th ed. Hoboken: Wiley-Blackwell; 2007. p. 47-63.
22. Stades FC, Van Der Woerdt A. Diseases and surgery of the canine eyelid. In: Gellat KN, Gilger BC, Kern TJ, editors. Veterinary Ophthalmology. 5th ed. Hoboken: Wiley-Blackwell; 2013. p. 832-93.
23. Wali UK, Al-Mujaini A. Sebaceous gland carcinoma of the eyelid. Oman J Ophthalmol. 2010;3:117-21.
24. Wilcock BP. Eye and ear. In: Maxie MG, editor. Pathology of Domestic Animals. Philadelphia: Elsevier-Saunders; 2007. p. 459-552.
25. Young KM, Prasse KW. Os olhos e as estruturas associadas. In: Cowell RL, Tyler RD, Meinkoth JH, Denicol DB, editors. Diagnóstico citológico e

hematologia de cães e gatos. São Paulo: Medvet; 2009.

26. Zouboulis CC, Boschnakow A. Chronological ageing and photoageing of the human sebaceous gland. Clin Exp Dermatol. 2001;26:600-7.

 All rights reserved 2007.