



Original Full Paper

Protective effect of intraportal infusion of hypothermic hydrogen-rich saline solution on hepatic warm ischemia/reperfusion injury in rat model

Hannaneh Golshahi¹, Abbas Tavasoly^{1*}, Seyed Hossein Mardjanmehr¹, Khosrou M. Abdi²,
Mohammad Mehdi Dehghan³, Saeed Farzad Mohajeri³

¹Department of Pathology, Faculty of Veterinary Medicine, University of Tehran, Tehran, Iran.

²Department of Radiopharmacy and Medicinal Chemistry, Faculty of Pharmacy, Tehran University of Medical Sciences, Tehran, Iran.

³Department of Surgery and Radiology, Faculty of Veterinary Medicine, University of Tehran, Tehran, Iran.

*Corresponding author: Department of Pathology, Faculty of Veterinary Medicine, University of Tehran, Tehran, Iran. Tel: +98-2161117060, Fax: (98)2166933222, Email: atavasoli@ut.ac.ir.

Submitted September 29th 2016, Accepted January 22nd 2017

Abstract

The aim of the present study was to investigate the effects of intraportal administration of hypothermic hydrogen-rich saline solution (HRSS) on hepatic ischemia/reperfusion (I/R) injury. Thirty rats were divided equally into six groups; 1) sham, no I/R or transfusion, 2) I/R injury (60 minutes ischemia + 120 minutes reperfusion), 3) I/R injury + normal saline 24°C, 4) I/R injury + normal saline 4°C, 5) I/R injury + HRSS 24°C, 6) I/R injury + HRSS 4°C. In groups 3-6, 1 mg/kg normal saline (NS) and/or HRSS were administered into the vein of the left lateral and median lobes of the liver (upper the site of clumping) 10 minutes before finishing of ischemic period. The harvest time points were at 2 hours post reperfusion in all groups. Cell death, sinusoidal dilatation, congestion, hemorrhage, and neutrophil infiltration were observed in I/R group, while these histopathological changes were attenuated in the hypothermic HRSS administrated groups ($P < 0.01$). The level of alanine aminotransferase, aspartate aminotransferase, malondialdehyde, interleukin 6, tumor necrosis factor α , and caspase-3 were increased significantly by I/R injury and hypothermic HRSS administration reduced all these markers ($P < 0.01$). SOD level was low in I/R group whereas it tended to increase in the hypothermic HRSS administrated groups ($P < 0.01$). The present study demonstrated that hypothermic hydrogen-rich saline solution effectively protected the hepatic tissue against cellular injury and organ dysfunction through the mechanisms that decrease the effect of oxidative stress, inflammation, apoptosis and necrosis.

Key words: hydrogen-rich saline solution, hypothermia, ischemia/reperfusion injury, liver, rat.

Introduction

Ischemia/reperfusion (I/R) injury is related to the morbidity and mortality after organ transplantation, myocardial and brain infarction, diabetes, major trauma, shock, and surgery under vascular occlusion in various organs (e.g. liver) (19, 32). Hepatic I/R injury is a relatively severe deleterious postsurgical complication in partial hepatic resection, hemorrhagic shock, lobectomy, liver transplantation, and trauma settings (44).

Several factors are involved in the pathophysiology of hepatic I/R injury. These include oxidative and/or nitrosative stress, endoplasmic reticulum stress, calcium overload, toll-like receptor system, leukocyte cascades, increase in the levels of adhesion molecules, separation of sinusoidal endothelial cells, activation of Kupffer cells, autophagy, apoptosis, and necrosis (2, 23, 26). Several hepatic preconditioning strategies to reduce irreversible hepatic injury have been widely studied, including ischemic preconditioning, and

postconditioning, modifications of vascular exclusion methods, pharmacological treatments (e.g. antioxidants, anti-inflammatory agents, vasodilators), and gene-therapy (6, 19, 43). Though, many antioxidants have been tested in experimental studies, non-selective antioxidants may lead to oxidant/antioxidant imbalance and interfere with the normal physiological effects of oxygen free radicals (22), so, clinically beneficial methods to attenuate hepatic I/R injury is still limited and it is important to improve clinical outcome.

Recently, researchers have been revealed that hydrogen gas, the lightest and most abundant chemical component in nature, displays a strong therapeutic and prophylactic effects against several organ injuries induced by oxidative stress and inflammation (25, 40, 57). It is indicated that molecular hydrogen can selectively decrease the levels of hydroxyl radical ($\cdot\text{OH}$) and peroxynitrite (ONOO^-), the most cytotoxic reactive oxygen species (ROS), but it is not disrupt the metabolic oxidation-reduction reactions or disturb ROS mediated cell signaling like superoxide and hydrogen peroxide (7). Also, due to its low molecular weight; it can simply penetrate biomembranes and diffuse into the nucleus, mitochondria, and cytosol (39). Hydrogen displays valuable efficacy in several diseases model such as I/R injury, inflammatory disease induced by oxidative stress, sepsis, metabolic disorders, multiple organ dysfunction syndrome, organ transplantation, Parkinson's disease, oxidative stress-induced cognitive decline, cancer and the toxicity of several drugs through its efficient antioxidant, anti-inflammatory, anti-apoptotic, anti-allergy properties and stimulation of cell proliferation (7, 24, 64, 36, 37, 40, 63). In compare to other therapeutic but potentially toxic antioxidant gases (e.g. carbon monoxide, hydrogen sulfide, nitric oxide, and ozone), H_2 is less expensive and more safe for clinical use (36). However, due to the explosion hazards of H_2 + air mixtures > 4.6% (v/v), hydrogen gas treatment cannot be use in clinical practice (56). Thus, due to its safety and convenience, hydrogen-rich saline solution (HRSS) is more appropriate for clinical application.

In situ hypothermic perfusion (HP) of the liver during total vascular exclusion (TVE) is a route to reduce hepatic I/R injury during extensive liver resections and lets prolongation of the duration of TVE and subsequent safe performance of hepatectomies. This protective effect is probably based on reduced metabolism and reduced energy and oxygen demand. So, in situ hepatic hypothermic perfusion is associated with an improved tolerance to ischemia, a recovered postoperative liver function, and a lower morbidity rate (1, 9).

The aim of the present study was to evaluate the biochemical and histologic effects of in situ infusion of hypothermic HRSS (HHRSS) on hepatic I/R injury.

Materials and methods

Animals

Thirty male Wistar rats (*Rattus norvegicus*), specific pathogen free (SPF), weighing 180~200 g, were used in the present study. Rats were given standard rat chow and tap water ad libitum. They were housed in caging system in an air-conditioned room with 12 hours light-dark cycles, where the temperature ($22 \pm 2^\circ\text{C}$) and relative humidity (60-65%) were kept constant. All animal experiment procedures were approved by the Animal Ethics Committee of the Faculty of the Veterinary Medicine, University of Tehran, Tehran, Iran. The animal protocol was planned to minimize pain and discomfort to the animals and every effort was made to minimize animal suffering. This study was conformed to the rules of the Protection of Vertebrate Animals Used for Experimental and other Scientific Purposes (8).

Preparation of hydrogen-rich saline

Hydrogen-rich saline was prepared as described previously (56). We prepared the HRSS in the Faculty of Pharmacy, Tehran University of Medical Sciences. Briefly, high-purity H_2 gas was injected into the 50 mL physiological saline for 12 hours under high pressure (0.4 MPa) at 4°C to harvest HRSS. The saturated HRSS was stored under atmospheric pressure at 4°C in an aluminum container with no dead volume. HRSS was freshly prepared to ensure a lowest concentration of 0.6 mmol/L and was used the same day when it was prepared. Gas chromatography was used to confirm the content of hydrogen in saline as described by Ohsawa et al. (40).

Study design

Rats in the current study were randomly divided into the following six groups with five rats in each group: Group 1: (Sham, n = 5), the liver was manipulated after the laparotomy, and no occlusion of the vessels of the liver was performed. Group 2: (I/R, n = 5), the partial (70%) hepatic warm ischemia model was induced after the laparotomy for 60 minutes followed by 120 minutes of reperfusion. Group 3 (I/R+ normal saline 24°C , n = 5), 1 mL/kg normal saline (NS) 24°C was injected slowly into the vein of the left lateral and median lobes of the liver 10 minutes before hepatic reperfusion. Further procedures were the same as those of group 2. Group 4 (I/R+ normal saline 4°C , n = 5), 1 mL/kg NS 4°C was injected slowly into the vein of the left lateral and median lobes of the liver 10 minutes before hepatic reperfusion. Further procedures were the same as those of group 2. Group 5 (I/R+ HRSS 24°C , n = 5), 1 mL/kg HRSS 24°C was injected slowly into the vein of the left lateral and median lobes of the liver 10 minutes before hepatic reperfusion. Further procedures were the same as those of group 2. Group 6 (I/R+ HRSS

4°C, n = 5), 1 mL/kg HRSS 4°C was injected slowly into the vein of the left lateral and median lobes of the liver 10 minutes before hepatic reperfusion. Further procedures were the same as those of group 2.

Establishment of animal models

A model of segmental (70%) warm hepatic I/R was performed in the present study. Briefly, the abdominal region sterilized with povidine-iodine solution and a midline laparotomy was performed under surgical anesthesia using intra peritoneal ketamine (75 mg/kg) and xylazine (7.5 mg/kg). The animals were kept supine for the duration of the experiments. Rectal temperature was maintained between 36-37°C by a heating pad throughout all procedures. The liver was freed from its ligaments. Complete ischemia of median lobes and left lateral lobe (LLL) was achieved by clamping of the portal veins, hepatic arteries, and biliary branches using atraumatic microvascular clip for 60 minutes. This method induced ischemia in approximately two-thirds of the liver and the remaining right lateral and caudate lobes taken whole portal and arterial blood supply. This model of partial hepatic I/R injury can avoid splanchnic congestion and any confusing effects resulting from bowel ischemia or hemodynamic disturbances (50). Discoloration of the liver was used as a positive marker for hepatic ischemia. During clamping, the liver was replaced into the abdominal cavity and the incision was closed temporarily to decrease evaporative loss. In the groups which intraportal administration was needed, solutions were injected by a 32 gage needle into the vein of the left lateral and median lobes of the liver (upper the site of clumping) 10 minutes before finishing of ischemic period. After that, the clamps were removed to allow organ reperfusion. Reperfusion was confirmed by an immediate color change.

Temperature control and measuring

Rats were kept in supine position on a heat pad. Environmental temperature was 24°C, maintained by air conditioners. The temperature of the surface of the liver was measured 0, 30, 60 minutes after induction of ischemia and, 15, 30, and 120 minutes after perfusion by an infrared ray thermometer.

Sample collection

The harvest time points were at 2 hours post reperfusion in all groups. The right ventricle was punctured, and 2 mL blood was aspirated with sterile syringes without anticoagulant and centrifuged to separate the serum and was stored into microcentrifuge tubes. Subsequently, the animals were sacrificed to perform hepatectomy. The left lob samples represented ischemic tissue and the right lobe represented non-ischemic tissue were collected and specimens were either: 1) fixed in 10%

phosphate-buffered formalin solution for further histopathologic evaluation and 2) immediately frozen in liquid nitrogen, then stored at -80°C for further analysis. Blood samples were centrifuged (1,791 g for 15 minutes at 4°C) to separate serum for storage at -80°C with subsequent analyses.

Tissue preparation and histological evaluation

Samples from the liver were fixed in 10% phosphate-buffered formalin solution and embedded in paraffin wax. Sections were cut at 5-µm thickness, deparaffinized and stained with hematoxylin and eosin (H&E) according to standard methods to evaluate the morphology.

Immunohistochemical staining

Four-µm thickness sections were heated to 60°C for 30 minutes, deparaffinized and hydrated in three changes of xylene and serial alcohol. Sections were sequentially incubated in 3% hydrogen peroxide at 37°C for 10 minutes to block the nonspecific protein activity. A rabbit polyclonal antibody against active caspase-3 (cat#ab13847, Abcam) (diluted 1:100) was added to the slides and incubated at 4°C overnight and then incubated with secondary antibody, goat anti-rabbit IgG (diluted 1:100) one hour at room temperature in the dark. Hematoxylin was used for counterstain and positive reaction was detected by the light microscope in 5 randomly selected areas at a magnification of ×400. The cleaved caspase-3 positive rate was expressed as the ratio of brown cells to blue cells. A pathologist examined all sections using a single blind.

Light microscopic examination

As there was no generally accepted grading system, we used a modification method introduced by Stangl et al. (46). Slides were evaluated independently by two expert pathologists. Any disagreements (<5%) were reviewed, followed by definitive decision. Ten areas of each slide were examined under a ×20 objective. The severity of the damages was semi-quantitatively evaluated. Assessed histopathologic changes were: congestion, vacuolar degeneration, necrosis, apoptosis, leukocyte infiltration, and tissue hemorrhage. These pathologic alterations were scored as follows: 0, no alteration; 1+, less than 10%; 2+, less than 50%; 3+, more than 50% of the cells are affected. The maximal score attainable by any individual sample was 18. All sections were studied using light microscopy.

Measurement of liver function

The serum alanine aminotransferase (ALT), aspartate aminotransferase (AST), activities were

determined by specific commercial kits, and expressed as unit per liter. All samples were tested in duplicate.

Cytokine measurement in serum

The levels of serum TNF- α and IL-6 were measured with commercial ELISA kits according to the instructions of the manufacturer (Rat IL-6 Elisa Kit Bioscience, Cat No: SK00110-02; Rat TNF-alpha Elisa Kit Bioscience, Cat No: SK00109-02, respectively). Concentrations were expressed in pictogram per milliliter. Standards and samples were run in duplicate.

Measurement of hepatic oxidative stress

Malondialdehyde (MDA) concentrations were determined by the thiobarbituric acid reaction according to the method of Buege and Aust (4) and superoxide dismutase (SOD) activities were evaluated by the xanthine oxidase method by the method of Sun et al. (49). The absorbance was measured at 535 and 550 nm for MDA and SOD, respectively, with a spectrometer. MDA concentrations and SOD activities were expressed as nanomoles per milligram of protein and units per milligram of protein, respectively.

Statistical analysis

For all analysis, the analyzers were blinded to study group. The measurement data are expressed as the mean \pm SD. Statistical analyses and evaluations were performed using Windows-compatible SPSS 18.0 software. The distribution of groups was analyzed using the Kolmogorov-Smirnov test. The normality test showed the data were consistent with a normal distribution. Differences between the experimental and control groups were assessed by either the analysis of variance (ANOVA) or Student's *t* test, as applicable. For analyses of histopathological alteration, the Kruskal-Wallis variance was used and the group medians were compared by Mann-Whitney U (Bonferroni) test when differences between them were detected. A *P* value of less than 0.05 was considered to be statistically significant.

Results

4°C HRSS and 24°C HRSS administration alleviated oxidative stress

As shown in Table 1, oxidant stress in hepatic tissue was evaluated by measuring hepatic MDA levels 120 minutes after reperfusion. The rats subjected to hepatic I/R exhibited an increase of the MDA levels compared with the sham-operated rats (*P* < 0.01). Administration of 4°C HRSS and 24°C HRSS to the rats with hepatic I/R resulted in a marked reduction of the MDA levels compared with the hepatic I/R group (*P* < 0.01 and

P < 0.01, respectively). Also there was no significant difference between the MDA level after administration 4°C HRSS and 24°C HRSS groups (*P* > 0.05). No significant variance was detected between 4°C HRSS and 24°C HRSS groups and sham group (*P* > 0.05 and *P* > 0.05, respectively). Administration of 4°C NS, and 24°C NS did not reduce the MDA levels significantly (*P* > 0.05 and *P* > 0.05, respectively).

4°C HRSS and 24°C HRSS administration improved antioxidant enzymatic activity

Antioxidant enzymatic activity was assessed by measuring hepatic SOD levels 2 hours after reperfusion. The rats subjected to hepatic I/R exhibited a decrease of the SOD levels compared with the sham-operated rats (*P* < 0.01). 4°C HRSS, 24°C HRSS, 4°C NS, and 24°C NS administration significantly increased hepatic SOD levels compared with the hepatic I/R group (*P* < 0.01, *P* < 0.01, *P* < 0.01, and *P* < 0.05, respectively). In the 4°C HRSS and 24°C HRSS groups the most improvement in the hepatic SOD level was noticed, though, there was no significant difference between the SOD level of 4°C HRSS and 24°C HRSS groups (*P* > 0.05). No significant difference was identified between 4°C HRSS and 24°C HRSS groups and sham group (*P* > 0.05 and *P* > 0.05, respectively) (Table 1).

4°C HRSS and 24°C HRSS administration decreased pro-inflammatory cytokine levels

As shown in Table 1, hepatic I/R injury induced systemic inflammatory responses, verified by the increases in serum levels of TNF- α , IL-6 compared to the sham group (*P* < 0.01 and *P* < 0.05, respectively). In the 4°C HRSS, 24°C HRSS, and 4°C NS groups, TNF- α concentrations in serum were significantly lower than those in the I/R group (*P* < 0.01, *P* < 0.01, and *P* < 0.05, respectively). Administration 24°C NS could not decrease the level of TNF- α concentrations in serum compared with the hepatic I/R injury (*P* > 0.05). No significant differences were identified about the TNF- α concentrations in serum of 4°C HRSS and 24°C HRSS groups with sham group (*P* > 0.05 and *P* > 0.05, respectively). In hepatic I/R group and 24°C NS the concentrations of IL-6 in serum was higher than the sham group (*P* < 0.01 and *P* < 0.01, respectively). However administration of 4°C HRSS, 24°C HRSS, and 4°C NS attenuated the concentration of IL-6 compared with the I/R group, no significant differences were detected (*P* > 0.05, *P* > 0.05, and *P* > 0.05, respectively) (Table 1).

4°C HRSS and 24°C HRSS administration alleviated plasma liver enzymes

The activities of AST and ALT were significantly higher in rats exposed to hepatic I/R injury compared with

Table 1. Effects of 24°C NS, 4°C NS, 24°C HRSS, and 4°C HRSS administration on MDA, SOD, TNF- α , IL-6, ALT, and AST levels in rats exposed to liver IR.

Group	Group 1 (Sham)	Group 2 (Hepatic I/R injury)	Group 3 (I/R+ 24°C NS)	Group 4 (I/R+ 4°C NS)	Group 5 (I/R+ 24°C HRSS)	Group 6 (I/R+ 4°C HRSS)
Parameter						
SOD (U/mg protein)	31.58 \pm 1.03	22.14 \pm 0.90 ^{ac*dc}	24.60 \pm 1.00 ^{ab*c}	26.39 \pm 1.51 ^{abc}	29.93 \pm 0.67 ^{bcd}	31.44 \pm 0.88 ^{bcd}
MDA (nmol/g tissue)	6.98 \pm 0.60	8.85 \pm 0.34 ^{ac}	8.71 \pm 0.23 ^{ac}	8.42 \pm 0.39 ^{ac}	7.24 \pm 0.22 ^{bcd}	6.91 \pm 0.44 ^{bcd}
TNF-α (pg/ml)	138.84 \pm 3.76	158.65 \pm 6.98 ^{ad*c}	161.40 \pm 2.73 ^{ade}	147.26 \pm 7.69 ^{b*c}	140.96 \pm 2.48 ^{bc}	138.26 \pm 2.09 ^{bc}
IL-6 (pg/ml)	39.64 \pm 2.85	50.79 \pm 3.61 ^a	51.06 \pm 4.76 ^a	46.71 \pm 6.29	44.23 \pm 1.56	43.27 \pm 4.00
ALT (U/l)	46.33 \pm 1.32	70.84 \pm 1.88 ^{ac}	71.48 \pm 2.13 ^{ac}	69.36 \pm 3.27 ^e	51.18 \pm 2.91 ^{bcd}	49.45 \pm 3.67 ^{bcd}
AST (U/l)	65.97 \pm 4.90	82.09 \pm 3.90 ^{ac}	82.13 \pm 3.10 ^{ac}	75.08 \pm 5.90	66.22 \pm 6.67 ^{bc}	62.62 \pm 3.08 ^{bcd}

^aCompared with that of the Group 1. P < 0.01.

^bCompared with that Group 2. P < 0.01; ^{b*}Compared with that Group 2. P < 0.05.

^cCompared with that Group 3. P < 0.01; ^{c*}Compared with that Group 3. P < 0.05.

^dCompared with that Group 4. P < 0.01; ^{d*}Compared with that Group 4. P < 0.05.

^eCompared with that Group 4. P < 0.01.

Table 2. Comparison of the effect of 24°C NS, 4°C NS, 24°C HRSS, and 4°C HRSS administration on microscopic damage in rats exposed to liver IR.

Group	Total injury score
Group 1 (Sham)	0.0 (0.0- 1.0)
Group 2 (Hepatic I/R injury)	18.0 (14.0-18.0) ^a
Group 3 (I/R+ 24°C NS)	16.0 (13.0-16.0) ^a
Group 4 (I/R+ 4°C NS)	12.0 (10.0-14.0) ^{ab}
Group 5 (I/R+ 24°C HRSS)	3.0 (2.0- 3.0) ^{bc}
Group 6 (I/R+ 4°C HRSS)	2.0 (1.0-2.0) ^{bcd}

Values are median (minimum-maximum).

^aSignificantly increased in groups 2-4 compared with that in group 1. (P < 0.01).

^bSignificantly decreased in groups 4-6 compared with that in group 2. (P < 0.05, P < 0.01, P < 0.01, respectively).

^cSignificantly decreased in groups 5-6 compared with that in group 4. (P < 0.01).

^dNot significant compared with group 5. (P > 0.05).

sham-operated rats ($P < 0.01$ and $P < 0.01$, respectively). A similar magnitude of ALT and AST increase was seen following administration of 24°C NS with I/R treatment ($P < 0.01$ and $P < 0.01$, respectively). Treatment with 4°C HRSS and 24°C HRSS significantly reduced ALT level compared with hepatic I/R injury group ($P < 0.01$ and $P < 0.01$, respectively). Similar attenuation was detected about the level of AST in the 4°C HRSS and 24°C HRSS group compared with the I/R injury group ($P < 0.01$ and $P < 0.01$, respectively) (Table 1).

4°C HRSS and 24°C HRSS administration attenuated apoptosis after hepatic I/R in rats

The number of cleaved caspase-3- positive cells in the I/R group was significantly increased compared with the sham group ($P < 0.01$) (Fig. 1A and 1B). The percentage of cleaved caspase-3-positive cells was decreased markedly in group 5 and group 6 compared with I/R group, 4°C NS, and 24°C NS administrated groups ($P < 0.01$) (Fig. 1C, 1D, 1E, and 1F).

Temperature measuring

All groups of rats presented a declining curve of the liver temperature, although the 4°C NS group and 4°C HRSS group demonstrated a significant lower temperature of the hepatic tissue compared to the sham-operated group ($P < 0.01$), hepatic I/R injury group ($P < 0.01$) and 24°C NS group and 24°C HRSS group ($P < 0.05$). No significant difference was seen between the 4°C NS group and 4°C HRSS group and/or 24°C NS group and 24°C HRSS group ($P > 0.05$).

Discussion

During liver surgery the hepatic pedicle often is clamped to decrease blood loss by Pringle's maneuver, which prompts hepatic I/R that can induces substantial hepatic parenchyma injury, ranging from a slight decrease in liver function and elevation of liver enzyme plasma levels to lethal organ failure. So, there is considerable interest in the prevention of hepatic I/R injury (51). Various clinical conditions including liver transplantation, hepatic resections, hepatic trauma, and hemorrhagic shock involve liver I/R injury (62).

Hepatic I/R injury is characterized by endothelial and Kupffer cell swelling, vasoconstriction, leukocyte infiltration, and platelet aggregation in the sinusoids. Moreover, activation of Kupffer cells and neutrophils leads to the release of inflammatory cytokines cascades and free radicals that damage the liver severely (42).

To develop a new approach to decrease liver I/R injury, we designed the present study to evaluate the effects of intraportal administration of hypothermic hydrogen-rich saline solution prior to the reperfusion stage on liver in rat model. In hepatic surgery, the possibilities of

treating hepatic I/R injury are limited frequently to the few minutes before reperfusion (14), so, in the present study we used hypothermic HRSS 10 minutes before reperfusion.

However antioxidant therapies is expected to have the clinical importance for oxidative injuries, antioxidants have been restricted therapeutic success (47). Antioxidant compounds have not displayed appropriate effect on preventing myocardial infarction, cancer, atherosclerosis, and also do not decrease mortality (18, 20, 47). An ideal antioxidant for use in clinical practice should be economical, safe, penetrable to the cytoplasm and nucleus, to alleviate excess oxidative stress, but not interrupt the redox homeostasis and reduce signaling molecules like H₂O₂ but should efficiently diminish oxidants such as •OH (41). Antioxidants such as vitamin C, which has a strong reducing power, can eradicate all ROS, which disturbs the signal transduction pathways in the body. Moreover, vitamin C produces ingredients with strong oxidative power after redox reactions, leads to further DNA damage (35). Recent studies showed that H₂ and/or HRSS have an effective therapeutic role in various conditions such as, organ transplantation, stroke, sepsis, multiple organ disorder syndrome, metabolic syndrome, atherosclerosis, neurodegenerative diseases and I/R injury in various organs (3, 16, 59, 60).

Another important issue is that molecular hydrogen has not been described to be toxic at effective doses, and even overdoses are improbable due to surplus hydrogen can be expired via the lungs. Additionally, the tissue compatibility of hydrogen is quite proved because it is an endogenous substance that is continuously produced in the human intestine (21, 53). Also, it can be used in chronic diseases caused by ROS with daily oral or inhaled hydrogen intake (31, 54). Furthermore, the ability of HRSS to protect the nuclear DNA and mitochondria suggests that it could reduce the risk of lifestyle-related diseases (52). The safety of hydrogen therapy has been indicated in humans who consumed hydrogen-rich water (HRW) and showed decreased levels of total ALT, AST, bilirubin, and γ -glutamyl transferase (22). Also, no tolerance established when animals were treated with HRSS constantly. There are various methods to use hydrogen (e.g. inhalation, drinking water, injection of saturated salt water, diffusion through the skin and endogenous hydrogen production by *Escherichia coli* (45). HRSS infusion and H₂ inhalation are most frequently used in clinical practice (17). Though, the different pharmacokinetics between hydrogen gas and hydrogen saline are not clear exactly, the advantages of HRSS over hydrogen gas are the safety issues, the easiness of application, and the possible higher concentrations of hydrogen in saline than could be used in gas. Hydrogen at a concentration above 4% is inflammable, so, application of hydrogen gas needs a sealed chamber and/or mask. Also, several researchers indicated that complications like facemasks and unattended patients, specifically neurologically impaired patients, may cause

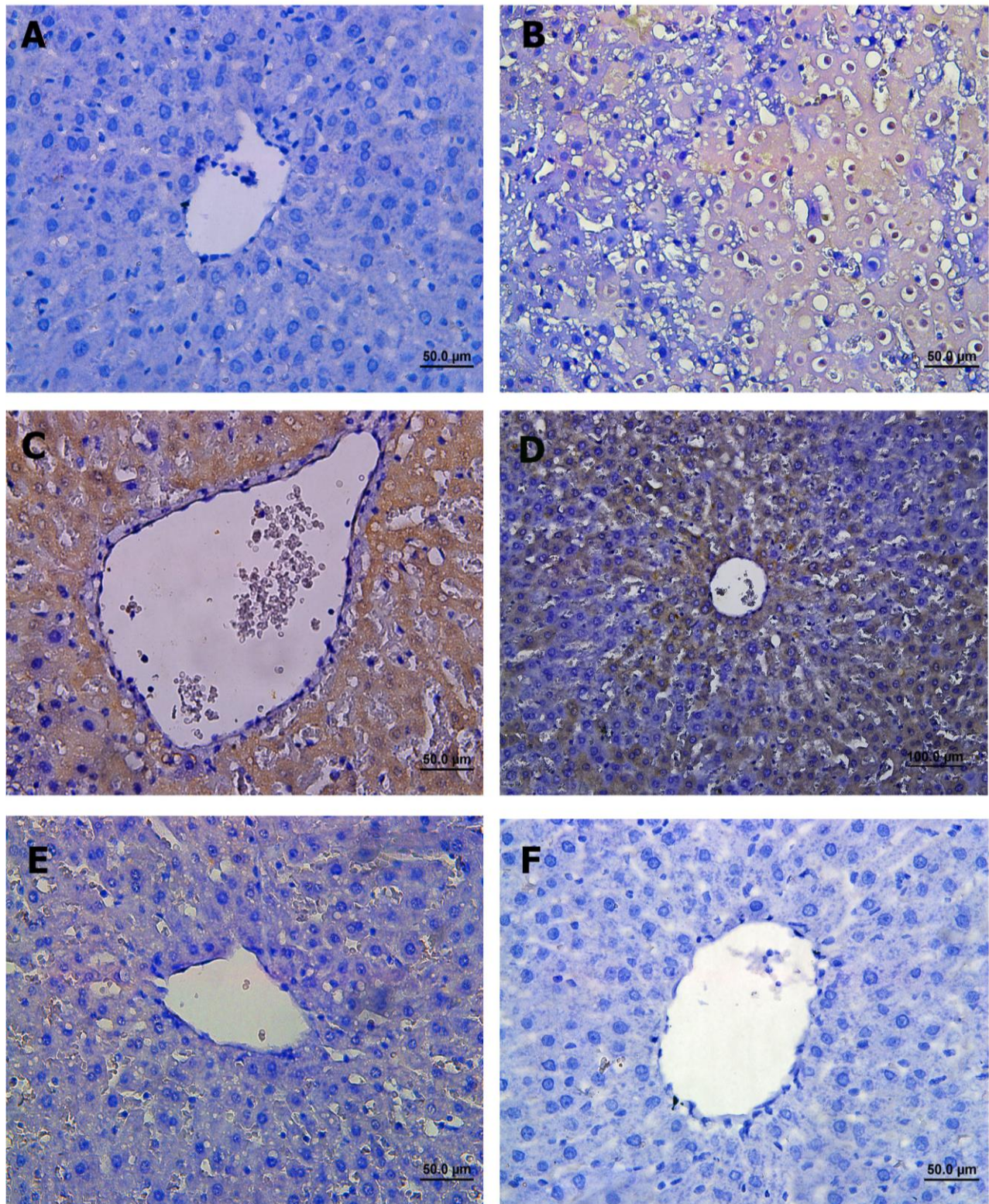


Figure 1. Male Wistar rats were subject to partial warm hepatic I/R injury with intraportal administration of 24°C NS, 4°C NS, 24°C HRSS, 4°C HRSS, at dose of 1 mL/kg 10 minutes before finishing of ischemic period. Liver damage was assessed 2 hours after reperfusion using immunohistochemistry staining of paraffin sections for Caspase-3 (A) sham-operated rat, (B) Rat undergoing 1 hour of ischemia followed by 2 hours of reperfusion, (C) (I/R+ 24°C NS), (D) (I/R+ 4°C NS), (E) (I/R+ 24°C HRSS), (F) (I/R+ 4°C HRSS).

inconsistencies with inhalation (10). Nagata et al. (33) administrated hydrogen water into the stomach of rats. Although hydrogen in water may be evaporate and misses H₂ in the stomach and/or intestine, also controlling concentration and absorption of H₂ is difficult (7). In another study, Le Prell et al. (2007) (28) indicated that the amount of orally administered H₂ may not be enough to scavenge hydroxyl radicals. Administration of hydrogen by an injectable form such as HRSS may let the supply of more accurate concentrations of H₂ (45). Nagatani et al. performed an open-label, prospective, non-randomized study of H₂ administration in patients hospitalized for acute ischemic stroke via I.V. route (200 mL twice a day) immediately after the diagnosis of acute ischemic stroke and reported that this method is safe for patients with acute cerebral infarction, including patients treated with tissue-plasminogen activator (t-PA) (34). Therefore, we used intraportal injection of HRSS that we could rapidly draw and immediately inject hydrogen saline into the hepatic tissue to avoid losing hydrogen into environment and also higher and more accurate concentrations of hydrogen could be applied.

The precise mechanism of the protective effects of H₂ is not clear exactly. Dole et al. (11) showed that hydrogen contained anti-cancer properties and hyperbaric hydrogen therapy degenerated squamous cell carcinomas and exhibited hydrogen therapy also had scavenger capability of the hydroxyl radical via an exothermic reaction. H₂ has been proved to protect the liver from a range of injuries, such as I/R injury, hepatitis, drug-induced liver injury, nonalcoholic steatohepatitis, hepatic cirrhosis and obstructive jaundice and also can induce regeneration (22, 41, 58).

More recent studies have also shown that the reducing power of molecular H₂ is weak, so, H₂ only reduces ROS with a strong oxidizability (•OH and ONOO). Superoxide dismutase (SOD) is a group of metalloenzymes that can effectively remove the active oxygen-free radicals generated by shock and I/R injury and also regulate an inflammatory response. It has been shown that hydrogen is able to increase the level of antioxidant enzymes such as superoxide dismutase and catalase or heme oxygenase-1 to protect the cell and suppress the disturbing effects of oxidative stress (11, 12, 58). In the present study, marked decrease in SOD levels in hepatic I/R injury group showed the exhaustion of antioxidant enzymatic activity and recovery in the 4°C NS, 24°C NS, 4°C HRSS, and 24°C HRSS groups revealed that hypothermia and hydrogen can protect liver from I/R injury via increasing endogenous SOD. And as we indicate previously, the most compensation occurred in the 4°C HRSS and 24°C HRSS groups.

Lipid peroxidation can disrupt the integrity of the cell membrane and lead to alterations its penetrability and fluidity. The increase in the levels of lipid peroxidation products such as MDA is a marker of lipid damage (31). The present study has demonstrated that the notable

increase in MDA in the I/R group confirmed the oxidative damage in the liver, In contrast, intraportal injection of 4°C HRSS and 24°C HRSS markedly reduced MDA level. However 4°C HRSS administration decreased the MDA Level more compared with 24°C HRSS administration, it was not significant difference. By measuring alterations in some type of oxidative stress biomarker and antioxidant level, we found that the decrease of oxidative damage and the increase of endogenous antioxidant enzymatic activities in hepatic tissue might contribute to the protective effect of hypothermic HRSS treatment, which is similar to the results in previous studies for administration of HRSS to liver or others organs and hypothermic solution in to the liver (13, 15, 24, 31, 55). However, we evaluated only the total SOD activity, and did not measure the SOD isoforms activity and expression. So the effects of hypothermic HRSS administration on the expression of three types of SOD isoforms need more research.

H₂ and/or HRSS have been shown to have anti-inflammatory effects in many diseases. H₂ alleviates hepatic injuries by reducing the inflammatory responses (31, 48). The increase in the level of pro-inflammatory cytokines, such as IL-1 β , IL-4, IL-5, IL-6, IL-12, IL-13, IFN- γ , and TNF- α , is a vital pathophysiological procedure in I/R injury and lead to infiltration of leukocyte to damaged tissue (38, 66). In some experimental studies of inflammatory disorders like colitis, hepatitis, obstructive jaundice, pancreatitis, and sepsis, it has been discovered that H₂ decreases inflammation (25). In the present study, 4°C HRSS, 24°C HRSS, and 4°C NS injection significantly attenuated the level of TNF- α concentrations in serum compared with the I/R group. However the amount of decrease in the concentration of IL-6 about the mentioned groups was not significant compared with the I/R group. In general we demonstrated that the in situ hypothermic HRSS administration notably can reduce the level of pro inflammatory cytokines levels and helps to diminution of tissue damages induced by I/R injury. Fu et al. (2011) indicated that mildly hypothermic (24°C) perfusion of NS may alleviate the injury of I/R, which brings significant decrease of liver enzymes, attenuation of I/R-induced histopathologic changes, and maintenance of normal hepatocellular ultramicro structures (15). However in the present study we demonstrated that treatment with 4°C HRSS and 24°C HRSS significantly reduced ALT and AST level compared with the I/R injury group and no significant attenuate was seen after only hypothermic normal saline administration. Zhao et al. indicated that Hypothermia could change various pathways involved in the pathogenic effects of cerebral ischemia, including reductions in metabolic and enzymatic activity, glutamate release and re-uptake, inflammation, reactive oxidant production, vascular permeability, blood-brain barrier disruption and the expression of a host of other genes (65).

Another probable mechanism of protection of H₂ is via the prevention of apoptosis. Accumulation of ROS has been supposed to be one of the key mechanisms to

cause the apoptotic procedure. ROS can harm cellular membrane and subcellular structures and lead to lipid peroxidation and structural and metabolic modifications which resulting in cell necrosis (apoptotic and oncotic) (66). Another hands, surge of oxygen to oxygen-deprived tissues causes increased production of ROS, leading to the mitochondrial permeability transition (MPT) and ruptured mitochondria release proapoptotic factors (e.g. cytochrome c) into the cytosol which can activate apoptotic agents such as caspases and subsequent cell death (29). When the MPT is severe, intense ATP depletion causes cell necrosis (27). So, the MPT causes both type of necrosis (apoptotic and oncotic) during I/R injury (30). Cai et al., indicated that the apoptosis of neurons in newborn rats induced by hypoxia and ischemia is inhibited by inhalation of H₂, as the ratio of Terminal-deoxynucleotidyl Transferase Mediated NickEnd Labeling (TUNEL) staining positive cells and the activity of caspase-3 and caspase-12 of the hippocampus and cortex was decreased (5) which was compatible with our finding about decrease of the activity of caspase-3 in hypothermic HRSS administrated groups. Also, studied showed that H₂ can inhibit the TNF- α /NF κ β , Ras-ERK1/2-MEK1/2, and Akt/Gsk3b pathways which have been involved in apoptosis inflammatory responses, and gene regulation (10). So, further researches are required to clarify the exact mechanism and signaling pathway involved in the protective role of hydrogen in I/R injuries.

Some limitations existed in our study; we have not evaluated serum and/or tissue hydrogen levels before and after hypothermic HRSS intraportal injection and their evaluation can better the cause and effect of HRSS administration and its protective effect. However, Xie et al. (60) demonstrated that H₂ inhalation at a 2% or 4% concentration had no distinguished effects on arterial pH, PO₂, and PCO₂ in mice. It is perfect to discover the progress of I/R injury and effect of hypothermic administration of HRSS in various time points with bigger sample sizes. In addition it needs to more accurate understanding about pharmacokinetics, biology of H₂ to facilitate clinical setting. We did not administrated hypothermic HHRSS to the sham group. However Sun et al. (48) reported no significant biochemical and histopathologic differences between the sham and sham plus HRSS groups. Also, rat models have some limitations in mimicking human biological and physiological properties. So further researches should be focus on larger animal models.

Conclusions

The present study revealed that hypothermic hydrogen-rich saline solution effectively protected the hepatic tissue against cellular injury and organ dysfunction through the mechanisms that decrease the effect of oxidative stress, inflammation, apoptosis and necrosis. Up to now a limited clinical trials performed about HRSS therapy, so more randomized, placebo controlled trials to

improve the amount of dose, timing and delivery of hypothermic HRSS should be performed.

Acknowledgment

This work was supported by a grant from the Faculty of Veterinary Medicine, University of Tehran, Iran (No. 7502012/6/15).

References

1. Azoulay D, Eshkenazy R, Andreani P, Castaing D, Adam R, Ichai P, Naili S, Vinet E, Saliba F, Lemoine A, Gillon MC, Bismuth H. In situ hypothermic perfusion of the liver versus standard total vascular exclusion for complex liver resection. *Ann Surg.* 2011;241:277-85.
2. Bahde R, Spiegel HU. Hepatic ischaemia-reperfusion injury from bench to bedside. *Br J.* 2010;97:1461.
3. Buchholz BM, Kaczorowski DJ, Sugimoto R, Yang R, Wang Y, Billiar TR, Mccurry KR, Bauer AJ, Nakao A. Hydrogen inhalation ameliorates oxidative stress in transplantation induced intestinal graft injury. *Am J Transplant.* 2008;8:2015-24.
4. Buege JA, Aust SD. Microsomal lipid peroxidation. *Methods Enzymol.* 1978;52:302.
5. Cai J, Kang Z, Liu WW, Luo X, Qiang S, Zhang JH, Ohta S, Sun X, Xu W, Tao H, Li R. Hydrogen therapy reduces apoptosis in neonatal hypoxia-ischemia rat model. *Neurosci Lett.* 2008;441:167-72.
6. Carini R, Alchera E, Baldanzi G, Piranda D, Splendore R, Grazia de Cesaris M, Caraceni P, Graziani A, Albano E. Role of p38 map kinase in glycine-induced hepatocyte resistance to hypoxic injury. *J Hepatol.* 2007;46:692-9.
7. Chen Y, Zong C, Guo Y, Tian L. Hydrogen-rich saline may be an effective and specific novel treatment for osteoradionecrosis of the jaw. *Ther Clin Risk Manag.* 2015;14:1581-5.
8. COUNCIL OF EUROPE. Appendix A of the European Convention for the Protection of Vertebrate Animals Used for Experimental and Other Scientific Purposes (ETS No. 123), Guidelines for Accommodation and Care of Animals (Article 5 of the Convention), Approved by the Multilateral Consultation, 15 June 2006, Cons 123 (2006) 3. Strasbourg : Council of Europe, 2006.
9. Dinant S, Roseboom HJ, Levi M, van Vliet AK, van Gulik TM. Hypothermic in situ perfusion of the porcine liver using Celsior or Ringer-lactate solution. *Langenbeck's Arch Surg.* 2009;39(4):143-50.
10. Dixon BJ, Jiping T, Zhang HJ. The evolution of molecular hydrogen: a noteworthy potential therapy with clinical significance. *Med Gas Res.* 2013;3:10.
11. Dole M, Wilson FR, Fife WP. Hyperbaric hydrogen therapy: a possible treatment for cancer. *Science.* 1975;190:152-4.

12. Du W, Amarachintha S, Wilson AF, Pang Q. SCO2 mediates oxidative stress-induced glycolysis to oxidative phosphorylation switch in hematopoietic stem cells. *Stem Cells*. 2016;34:960-71.
13. Fang Y, Fu XJ, Gu C, Xu P, Wang Y, Yu WR, Sun Q, Sun XJ, Yao M. Hydrogen-rich saline protects against acute lung injury induced by extensive burn in rat model. *J Burn Care Res*. 2011;32:82-91.
14. Figueira ER, Bacchella T, Coelho AM, Sampietre SN, Molan NA, Leitão RM, Machado MC. Timing dependent protection of hypertonic saline solution administration in experimental liver ischemia/reperfusion injury. *Surg*. 2010;147:415-23.
15. Fu X, Lu C, Chu K, Yao X, Cheng S, Gao C, Shen F, Wu M. The hepatoprotective effect of hypothermic perfusion of normal saline in period of inflow occlusion of liver in rats. *J Surg Res*. 2011;166:104-8.
16. Fukuda K, Asoh S, Ishikawa M, Yamamoto Y, Ohsawa I, Ohta S. Inhalation of hydrogen gas suppresses hepatic injury caused by ischemia/reperfusion through reducing oxidative stress. *Biochem Biophys Res Commun*. 2007;361:670-4.
17. Ge P, Zhao J, Li S, Ding Y, Yang F, Luo Y. Inhalation of hydrogen gas attenuates cognitive impairment in transient cerebral ischemia via inhibition of oxidative stress. *Neurol Res*. 2012;34:187-94.
18. Hackam DG. Review: antioxidant supplements for primary and secondary prevention do not decrease mortality. *ACP J Club*. 2007;147:4.
19. Hausenloy DJ, Yellon DM. Preconditioning and postconditioning: underlying mechanisms and clinical application. *Atherosclerosis*. 2009;204:334-41.
20. Herberg S, Kesse-guyot E, Druesne-Pecollo N, Touvie R M, Favier A, Latino-Martel P, Briançon S, Galan P. Incidence of cancers, ischemic cardiovascular diseases and mortality during 5-year follow-up after stopping antioxidant vitamins and minerals supplements: a post intervention follow-up in the SU.VI.MAX Study. *Int J Cancer*. 2010;127:1875-81.
21. Hong Y, Chen S, Zhang JM. Hydrogen as a selective antioxidant: A review of clinical and experimental studies. *J Int Med Res*. 2010;38:1893-1903.
22. Huang CS, Kawamura T, Toyoda Y, Nakao A. Recent advances in hydrogen research as a therapeutic medical gas. *Free Radic Res*. 2010;44:971-82.
23. Ji J. Dual role of matrix metalloproteinase 9 in liver ischemia and reperfusion injury. *J Surg Res*. 2013;185:545-6.
24. Ji Q, Hui K, Zhang L, Sun X, Li W, Duan M. The effect of hydrogen-rich saline on the brain of rats with transient ischemia. *J Surg Res*. 2011;168:95-101.
25. Kajiya M, Silva MJ, Sato K, Ouhara K, Kawai T. Hydrogen mediates suppression of colon inflammation induced by dextran sodium sulfate. *Biochem Biophys Res Commun*. 2009;386:11-15.
26. Kalogeris T, Baines CP, Krenz M, Korthuis RJ. Cell biology of ischemia/reperfusion injury. *Int Rev Cell Mol Biol*. 2012;298:229.
27. Kim JS, Qian T, Lemasters JJ. Mitochondrial permeability transition in the switch from necrotic to apoptotic cell death in ischemic rat hepatocytes. *Gastroenterol*. 2003;124:494-503.
28. Le Prell CG, Yamashita D, Minami SB, Yamasoba T, Miller JM. Mechanisms of Noise-Induced Hearing Loss Indicate Multiple Methods of Prevention. *Hear Res*. 2007;226:22-43.
29. Lemasters JJ, Qian T, He L, Kim JS, Elmore SP, Cascio WE, Brenner DA. Role of mitochondrial inner membrane permeabilization in necrotic cell death, apoptosis, and autophagy. *Antioxid Redox Signal*. 2002;4:769-81.
30. Linkermann A, Bräsen JH, Darding M, Jin MK, Sanz AB, Heller JO, De Zen F, Weinlich R, Ortiz A, Walczak H, Weinberg JM, Green DR, Kunzendorf U, Krautwald S. Two independent pathways of regulated necrosis mediate ischemia-reperfusion injury. *Proc Natl Acad Sci USA*. 2013;110:12024-9.
31. Liu Y, Yang L, Tao K, Vizcaychipi MP, Lloyd DM, Sun X, Irwin MG, Ma D, Yu W. Protective effects of hydrogen enriched saline on liver ischemia reperfusion injury by reducing oxidative stress and HMGB1 release. *BMC Gastroenterol*. 2014;14:12.
32. Mustoe T. Understanding chronic wounds: a unifying hypothesis on their pathogenesis and implications for therapy. *Am J Surg*. 2004;187:65S-70S.
33. Nagata K, Nakashima-Kamimura N, Mikami T, Ohsawa I, Ohta S. Consumption of molecular hydrogen prevents the stress-induced impairments in hippocampus-dependent learning tasks during chronic physical restraint in mice. *Neuropsychopharmacol*. 2009;34:501-8.
34. Nagatani K, Nawashiro H, Takeuchi S, Tomura S, Otani N, Osada H, Wada K, Katoh H, Tsuzuki N, Mori K. Safety of intravenous administration of hydrogen-enriched fluid in patients with acute cerebral ischemia: initial clinical studies. *Med Gas Res*. 2013;3:13.
35. Naidu KA. Vitamin C in human health and disease is still a mystery? An overview. *Nutr J*. 2003;2:7.
36. Nakao A, Toyoda Y, Sharma P, Evans M, Guthrie N. Effectiveness of hydrogen rich water on antioxidant status of subjects with potential metabolic syndrome-an open label pilot study. *J Clin Biochem Nutr*. 2010;46:140-9.
37. NASA. Safety standard for hydrogen and hydrogen systems. Washington DC: National Aeronautics and Space Administration, 2005.
38. Nezu Y, Shigihara K, Harada Y, Harada Y, Yogo T, Hara Y, Tagawa M. Effects of small intestinal ischemia and reperfusion on expression of tumor necrosis factor-alpha and interleukin-6 messenger

- RNAs in the jejunum, liver, and lungs of dogs. *Am J Vet Res.* 2008;69:4.
39. Ohno K, Ito M, Ichihara M, Ito M. Molecular hydrogen as an emerging therapeutic medical gas for neurodegenerative and other diseases. *Oxid Med Cell Longev.* 2012;2012:1-11.
 40. Ohsawa I, Ishikawa M, Takahashi K, Watanabe M, Nishimaki K, Yamagata K, Katsura K, Katayama Y, Asoh S, Ohta S. Hydrogen acts as a therapeutic antioxidant by selectively reducing cytotoxic oxygen radicals. *Nat Med.* 2007;13:688-94.
 41. Ohta S. Molecular hydrogen as a preventive and therapeutic medical gas: initiation, development and potential of hydrogen medicine. *Pharmacol Ther.* 2014;144:1-11.
 42. Papadopoulos D, Siempis T, Theodorakou E, Tsoufas G. Hepatic ischemia and reperfusion injury and trauma: current concepts. *Arch Trauma Res.* 2013;2:63-70.
 43. Romanque P, Uribe M, Videla LA. Molecular mechanisms in liver ischemic–reperfusion injury and ischemic preconditioning. *Med. Chil.* 2005;133:469-76.
 44. Serracino-Inglott F, Habib NA, Mathie RT. Hepatic ischemia reperfusion injury. *Am J Surg.* 2001;181:160.
 45. Shen M, Zhang H, Yu C, Wang F, Sun X. A review of experimental studies of hydrogen as a new therapeutic agent in emergency and critical care medicine. *Med Gas Res.* 2014;4:17.
 46. Stangl R, Szijártó A, Ónody P, Tamás J, Tátrai M, Hegedus V, Blázovics A, Lotz G, Kiss A, Módis K, Gero D, Szabó C, Kupcsulik P, Harsányi L. Reduction of liver ischemia-reperfusion injury via glutamine pretreatment. *J Surg Res.* 2011;166:95-103.
 47. Steinhubl SR. Why have antioxidants failed in clinical trials? *Am J Cardiol.* 2008; 101:14-19.
 48. Sun H, Chen L, Zhou W, Hu L, Li L, Tu Q, Chang Y, Liu Q, Sun X, Wu M, Wang H. The protective role of hydrogen-rich saline in experimental liver injury in mice. *J Hepatol.* 2011;54:471-80.
 49. Sun Y, Oberley LW, Li Y. A simple method for clinical assay of superoxide dismutase. *Clin Chem.* 1988;34:497.
 50. Sutter AG, Palanisamy AP, Ellet JD, Schmidt MG, Schnellmann RG, Chavin KD. Interleukin-10 and Kupffer cells protect steatotic mice livers from ischemia-reperfusion injury. *Eur Cytokine Netw.* 2014;25:69-76.
 51. Tamagawa K, Horiuchi T, Uchinami M, Doi K, Yoshida M, Nakamura T, Sasaki H, Taniguchi M, Tanaka K. Hepatic ischemia-reperfusion increases vascular endothelial growth factor and cancer growth in rats. *J Surg Res.* 2008;148:158-63.
 52. Tan YC, Xie F, Zhang HL, Zhu YL, Chen K, Tan HM, Hu BS, Yang JM, Tan JW. Hydrogen-rich saline attenuates postoperative liver failure after major hepatectomy in rats. *Clin Res Hepatol Gastroenterol.* 2014;38:337-45.
 53. Tao Y, Geng L, Wang L, Xu W, Qin L, Peng G, Huang YF, Yang J. Use of hydrogen as a novel therapeutic strategy against photoreceptor degeneration in retinitis pigmentosa patients. *Med Sci Monit.* 2016;8:776-9.
 54. Terasaki Y, Ohsawa I, Terasaki M, Takahashi M, Kunugi S, Dedong K, Urushiyama H, Amenomori S, Kaneko-Togashi M, Kuwahara N, Ishikawa A, Kamimura N, Ohta S, Fukuda Y. Hydrogen therapy attenuates irradiation-induced lung damage by reducing oxidative stress. *Am J Physiol Lung Cell Mol Physiol.* 2011;301:415-26.
 55. Wang F, Yu G, Liu SY, Li JB, Wang JF, Bo LL, Qian LR, Sun XJ, Deng XM. Hydrogen-rich saline protects against renal ischemia/reperfusion injury in rats. *J Surg Res.* 2011;167:339-44.
 56. Wang W, Tian L, Li Y, Wang X, Xia F, Li L, Li J, Zhang Z. Effects of hydrogen-rich saline on rats with acute carbon monoxide poisoning. *J Emerg Med.* 2013;44:107-15.
 57. Xiao M, Zhu T, Wang T, Wen FQ. Hydrogen-rich saline reduces airway remodeling via inactivation of NF- κ B in a murine model of asthma. *Eur Rev Med Pharmacol Sci.* 2013;17:1033-43.
 58. Xie K, Yu Y, Pei Y, Hou L, Chen S, Xiong L, Wang G. Protective effects of hydrogen gas on murine polymicrobial sepsis via reducing oxidative stress and HMGB1 release. *Shock.* 2010;34:90-97.
 59. Xie K, Liu L, Yu Y, Wang G. Hydrogen gas presents a promising therapeutic strategy for sepsis. *Biomed Res Int.* 2014;2014.
 60. Xie K, Yu Y, Huang Y, Zheng L, Li J, Chen H, Han H, Hou L, Gong G, Wang G. Molecular hydrogen ameliorates lipopolysaccharide-induced acute lung injury in mice through reducing inflammation and apoptosis. *Shock.* 2012;37:548-55.
 61. Yu J, Zhang W, Zhang R, Ruan X, Ren P, Lu B. Lactulose accelerates liver regeneration in rats by inducing hydrogen. *J Sur Res.* 2015;195:128-35.
 62. Zhai Y, Petrowsky H, Hong JC, Busuttill RW, Kupiec-Weglinski JW. Ischaemia-reperfusion injury in liver transplantation-from bench to bedside. *Nat Rev Gastroenterol Hepatol.* 2013;10:79-89.
 63. Zhang JY, Liu C, Zhou L, Qu K, Wang R, Tai MH, Lei Lei JC, Wu QF, Wang ZX. A review of hydrogen as a new medical therapy. *Hepatogastroenterol.* 2012;59:1026-32.
 64. Zhao L, Zhou C, Zhang J, Gao F, Li B, Chuai Y, Liu C, Cai J. Hydrogen protects mice from radiation induced thymic lymphoma in BALB/c mice. *Int J Biol Sci.* 2011;7: 297-300.
 65. Zhao WH, Ji XM, Ling F, Ding YC, Xing CH, Wu H, Guo M, Xuan Y, Guan B, Jiang LL. Local mild hypothermia induced by intra-arterial cold saline infusion prolongs the time window of onset of

reperfusion injury after transient focal ischemia in rats.
Am J Vet Res. 2008;69:512-18.

66. Zheng X, Mao Y, Cai J, Li Y, Liu W, Sun P, Zhang JH, Sun X, Yuan H. Hydrogen-rich saline protects against intestinal ischemia/reperfusion injury in rats. Free Rad Res. 2009;43:478-84.