BJVP
Brazilian Journal of Veterinary Pathology
ISSN 1983-0246

Original Full Paper

Histopathological pattern recognition of cresty neck in horses in Spain

Abelardo Morales[1]*, Aniceto Méndez[1], José Méndez[2], Alejandro Escamilla[1], José Pérez[1]

[1]Departamento de Anatomía y Anatomía Patológica Comparadas, Universidad de Córdoba, Córdoba, Spain.
[2]Hospital Equino de Aznalcóllar, Sevilla, Spain.
***Corresponding author**: Departamento de Anatomía y Anatomía Patológica Comparadas, Edificio de Sanidad Animal, Campus de Rabanales Ctra. de Madrid km 396, 14071, Córdoba Universidad de Córdoba, España. E-mail: aamorales13@gmail.com

Submitted January 10th 2017, Accepted February 20th 2017

Abstract

The aim of this study was to describe patterns of histopathological recognition of the cresty neck in Horses in Spain. A total of 250 horses were studied in Andalusia and Extremadura, Spain. Seventy-six percent of horses present cresty neck. The damage of the cresty neck in horses was categorized as Grade 0 - Muscle fibers are observed, no fat vacuoles are observed (24% of the horses). Grade 1 – Scarce adipose deposit was observed. An unaltered muscle tissue is observed (21% of the horses). Grade 2 **-** fat vacuoles are evident in muscle tissue intermyofibrillar space and prone to coalescence (23% of the horses). Grade 3 **-** Abundant fat vacuoles in the intermyofibrillar space, with tendency to coalesce, and low fat infiltration in muscle tissue (moderate lipomatosis) (16% of the horses). Grade 4 **-** Abundant fat vacuoles in the intermyofibrillar space, with tendency to coalesce, and fatty infiltration in muscle tissue (marked lipomatosis) (8% of the horses). Grade 5 **-** Only fat vacuoles are observed, without muscle tissue (severe lipomatosis) (8% of the horses). The results for desmin antibody (1: 100 dilution) was positive (++) in grades 0-2, and negative (-) in grades 3-5. These results suggest that as fat/lipomatosis infiltration increases (progresses in grades 3, 4 and 5), the intercellular space (intermyofibrillar) increases and therefore the cell cytoskeleton is lost, with loss of the bands Z, so the negative response to this antibody. In conclusion, we describe histopathological pattern recognition of cresty neck in horses in Spain.

Key words: biopsy, cresty neck, histopathology, horses.

Introduction

The cresty neck include deformation of the dorsal neck, associated with degenerative changes characterized by fat infiltration (lipomatosis), involving subcutis, nuchal ligament, spinal muscle, and multifidi muscles. The atlas, axis, and cervical vertebra are not infiltrated. The cresty neck is a condition that occurs in horses, with high predisposition to some races, including the Purebred Spanish, Lusitano and some crosses. Both environmental and genetic factors are associated with cresty neck (13). There are discrepancies between clinicians, veterinarians, farmers, geneticists, researchers are considered a defect or a pathological condition, preliminary studies show degenerative changes associated with the deposition of fat (lipomatosis). Increased fat deposits along the crest of the neck in horses and ponies (nuchal crest adiposity), has similarly been associated with an altered metabolic state (7) and an increased risk of certain metabolic disorders such insulin resistance (7). Metabolic myopathies include a group of diseases that have the common feature of accumulating normal or abnormal products of metabolism, such as glycogen and lipids (8). A relative similar condition occurs in Piedmontese cattle described as Lipomatous Muscular Dystrophy (LMD), histological investigations showed variations in fiber size, fiber necrosis, mononuclear cell infiltration, increase of connective tissue and especially, replacement by fat (4). Histological characterization of cresty neck in horses is necessary to elucidate the aetiopathogenesis of the cresty

 All rights reserved 2007.

neck as well as the description of histological patterns. The aim of this study was to describe histopathological pattern recognition of cresty neck in horses in Spain.

Materials and methods

A total of 250 horses were study in Cordoba, Sevilla, and Southern Extremadura, Spain during 2014-2016. All necks were examined by modified biopsy (System for Biopsy Adjustable: To take the sample with a punch of 0.5 mm of diameter) (11), histopathology and grossly scored using a standard lesion classification (10, 110. For histological examination, samples of neck were fixed in 10% formalin, embedded in paraffin and cut to 5 µm sections (2, 3). The slides were stained with Masson´s Trichrome. Additionally, were performed the antibody (desmin 1:100) for immunohistochemical (IHC) study (1, 6, 12). The pathologic examinations included identification of cell type, overall cellularity, cytoplasmic features, nuclear atypia, mitotic index, immunohistochemical findings and morphometric study.

This study was approved by the institutional committee for bioethics and welfare in animal experimentation of the Universidad Central de Venezuela.

Results

Seventy-six percent of horses (189/250) present cresty neck. The damage of the cresty neck in horses was categorized (Table 1) as Grade 0 - Muscle fibers are observed, no fat vacuoles are observed. This grade corresponded to 24% (61/250) of the horses (Fig. 1A). This level corresponds to the normal condition of the neck. Masson´s trichrome was negative (-). Grade 1 **-** Scarce adipose deposit was observed, and unaltered muscle tissue is observed. This grade corresponded to 21% (52/250) of the horses (Fig. 1B). Masson´s trichrome was mildly positive (+). Grade 2 **-** Fat vacuoles were evident in muscle tissue intermyofibrillar space and prone to coalescence. This grade corresponded to 23% (58/250) of the horses (Fig. 1C). Masson´s trichrome was moderately positive (++). Grade 3 **-** Abundant fat vacuoles in the intermyofibrillar space, with tendency to coalesce, and low fat in muscle tissue infiltration (moderate lipomatosis). This grade corresponded to 16% (40/250) of the horses (Fig. 1D). Masson´s trichrome was moderately positive (++). Grade 4 **-** Abundant fat vacuoles in the intermyofibrillar space, with tendency to coalesce, and fatty infiltration in muscle tissue (marked lipomatosis). This grade corresponded to 8% (20/250) of the horses (Fig. 1E). Masson´s trichrome was strongly positive (+++). Grade 5 **-** Only fat vacuoles were observed, without muscle tissue (severe lipomatosis). This grade corresponded to 8% (19/250) of the horses (Fig. 1F). Masson´s trichrome was strongly positive (+++). Immunostaining of desmin (1: 100 dilution of the primary antibody) was moderately positive (++) in grades 0-2, and negative (-) in grades 3-5 (Fig. 2). These results suggest that as fat/lipomatosis infiltration increases (progresses in grades 3, 4 and 5), the intercellular space (intermyofibrillar) increases and therefore the cell cytoskeleton is lost, with loss of the bands Z, so the negative response to this antibody.

Discussion

Cresty neck was associated with variations in muscular fiber size, which is very common, and increase of connective tissue and especially, replacement by fat, although fiber necrosis and mononuclear cell infiltration were not observed, as reported in the syndrome Lipomatous Muscular Dystrophy (LMD) in cattle (4, 5). Recognition patterns allow establishing a score from the normal neck Grade 0, which is predominantly only muscle tissue, intermediate grades 1, 2 and 3, where a fat infiltration is observed in the muscle tissue to more severe grades 4 and 5, where severe fat infiltration (lipomatosis) is observed, with replacement of muscle tissue by adipose tissue. The Masson´s trichrome allows the delimitation of the collagen fibers, which was positive in Grades 3, 4 and 5, indicating an increase in collagen fibers in cases of increased fat infiltration (lipomatosis), and to a lesser extent in Grades 0, 1 and 2. Immunohistochemical results focused on muscle, confirm the small fat in Grades 0, 1 and 2, whereas for Grades 3, 4 and 5 it indicated severe fat infiltration, and replacement of muscle tissue. We are currently working on other antibodies that allow the characterization of muscle tissue and fat tissue in the neck of the horse. A high incidence was observed 76% in horses of Cordoba, Sevilla, and Southern Extremadura, Spain. A recent report suggests cresty neck is a common defect in Spanish Pure Breed horses, affecting 8.89% of the worldwide population (13). A high incidence (76%) were observed in horses with this deformity (cresty neck), these are immediately disqualified from the competitions and removed from the Spanish Pure Breed genetic book, with important economic losses due to its imminent economic devaluation. These horses with neck deformity are sent to slaughter, which limits their study. Several findings led to the classification of this condition pathology. For this study was not considered other, underlying metabolic diseases but many studies suggest an association to the following conditions: endocrine diseases in horses as Equine Metabolic Syndrome, Cushing's syndrome, insulin resistance, obesity, laminitis, hyperlipemia (9, 14). Cresty neck score has a moderate heritability, indicating that the prevalence of this defect could be diminished by genetic selection (13). The description of the histopathological patterns allow the understanding of the metabolic and morphologic alterations cresty neck horses, as well as identifies this phenotype condition as a present pathology in the neck of the horse. These metabolic changes associated with increased neck fat deposition and lipomatosis, with severe fatty infiltration in cervical

Table 1. Cell type, overall cellularity, cytoplasmic features, nuclear atypia, mitotic index.

Score	Cell type	Overall cellularity	Cytoplasmic features	Morphometric Measure Muscular Area (micrometer)
Grade 0	Muscle Fibers	99%	No changes are observed in the cytoplasm.	1314
Grade 1	Muscle Fibers	95%	Scarce fat vacuoles are seen in the cytoplasm	1280
	Adipose cells	5%	No changes are observed in the cytoplasm.	
Grade 2	Muscle Fibers	85%	Fat vacuoles are seen in the cytoplasm	1004
	Adipose cells	15%	Coalescence of adipocytes.	
Grade 3	Muscle Fibers	48%	Were observed an increase of fat vacuoles in the cytoplasm with tendency to coalescence, and involves the intermiofibrillar space.	844
	Adipose cells	62%	Coalescence of adipocytes and deposits of fat.	
Grade 4	Muscle Fibers	15%	The plethoric cytoplasm of fat vacuoles with coalescence is observed and and involves the intermiofibrillar space.	454
	Adipose cells	85%	Coalescence of adipocytes and abundant deposits of fat	
Grade 5	Adipose cells	99%	Coalescence of adipocytes and abundant deposits of fat	136

No nuclear atypia and mitotic index were observed.

Table 2. Results of histopathological pattern recognition of cresty neckin equine (classification of Morales, 2016), Masson´s trichrome and desmin.

Score histopathological pattern (Morales 2016)	Histology Pattern	Masson´s Trichrome	Desmin (1:100)
Grade 0	61	-	+++
Grade 1	52	+	++
Grade 2	58	++	+
Grade 3	40	++	-
Grade 4	20	+++	--
Grade 5	19	+++	---

 All rights reserved 2007.

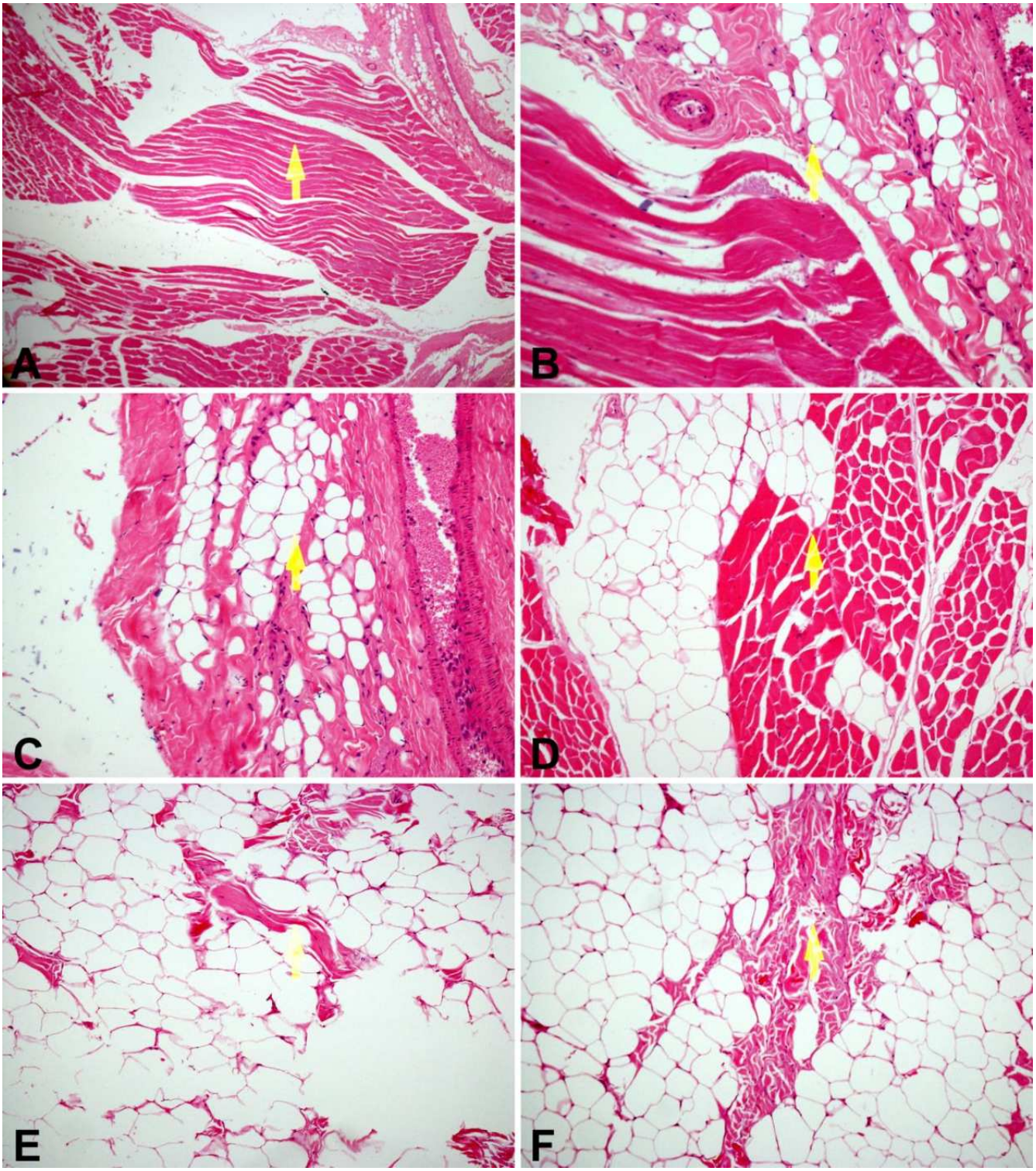

Figure 1. (A) Histopathological section of the cresty neck. Grade 0 - Muscle fibers (arrow) are observed, with no fat vacuoles (H&E 4X). **(B)** Histopathological section of the cresty neck. Grade1 **-** Scarced adipose deposit was observed (arrow), with unaltered muscle tissue (H&E 10X). **(C)** Histopathological section of the cresty neck. Grade 2 **-** adipose deposit are evident in the intermyofibrillar space (H&E 10X). **(D)** Histopathological section of the cresty neck. Grade 3 **-** Adipose deposit is showed in the intermyofibrillar space and moderated lipomatosis affecting muscle tissue (H&E 10X). **(E)** Histopathological section of the cresty neck. Grade 4 - abundant fat vacuoles in the intermyofibrillar space and marked lipomatosis in the muscle tissue (H&E 10X). **(F)** Histopathological section of the cresty neck. Grade 5 - only fat deposits are observed in severe lipomatosis (H&E 10X).

 All rights reserved 2007.

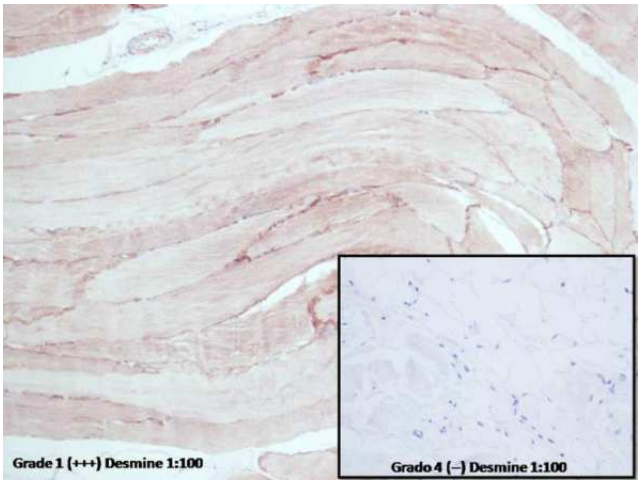

Figure 2. Immunohistochemical section of the cresty neck. Desmin antibody (1: 100 dilution) was positive (++) in grade 1, and negative (--) in grade 4.

muscles, may be associated with body condition, quality of diet, exercise, management and levels of vitamin E.

In conclusion, we describe histopathological pattern recognition of cresty neck in horses in Spain. In the future we hope to determine variables predictive for the development cresty neck in horses. Finally histopathological pattern recognition of cresty neck can have application in the pre-purchase exams in horse breeds at risk of pathology of the dorsal neck.

Acknowledgements

The authors acknowledge the technical assistance of Mrs. Gema Muñoz and Mr. Antonio Ramirez Career at biopsy and histological processing.

References

1. Al-Daraji W, Husain E, Zelger B, Zelger B. A practical and comprehensive immunohistochemical approach to the diagnosis of superficial soft tissue tumors. Int J Clin Exp Pathol. 2009;2:119-31.
2. Aluja A, Constantino C. Technical of necropsy in domestic animals. 2nd ed. Mexico: Manual Moderno; 2002. p.103-4.
3. Banks W. Veterinary Applied Histology. 2nd ed. México: Manual Moderno; 1996. p.487-92.
4. Biasibetti E, Peletto S, Acutis P, Boin C, Schiavini F, Bagnato A, Capucchio MT. A multiple approach to investigate the aetiopathogenesis of Lipomatous Muscular Dystrophy in Piedmontese cattle. ESVP/ECVP Proceedings. 2013;150:1.
5. Biasibetti E, Peletto S, Acutis P, Brugiapaglia A, Vincenti L, Ricci A, Mioletti S, Boin C, Schiavini F, Bagnato A, Capucchio MT. Lipomatous Muscular Myopathy in Piedmontese cattle: different techniques to investigate the aetiopathogenesis. XVIII Reunión de la Sociedad Española de Anatomía Patológica Veterinaria; 2016; Córdoba, Spain: Cordoba Junio; 2016. P5; 81.
6. García-Miralles T, Gonzalbes-Garcia J. Marcadores inmunohistoquimicos del desarrollo embriológico en el músculo estriado de las extremidades fetales. Available at: http://www.uninet.edu/conganat/conferencias/C006/. 2002.
7. Giles SL, Nicol CJ, Rands SA, Harris PA. Assessing the seasonal prevalence and risk factors for nuchal crest adiposity in domestic horses and ponies using the Cresty Neck Score. BMC Vet Res. 2015;31:11-13.
8. Gil F, Alemán M, Rivero MA, Latorre R, Carrión MA, Aguirre C, Ruíz I, Ayala I. Neuromuscular disease associated with glycogen storage in a Spanish-bredfilly. Vet Rec. 2006;158(15):513-6.
9. Johnson PJ. The equine metabolic syndrome peripheral Cushing´s syndrome. Vet Clin North Am Equine Pract. 2002;18(2):271-93.
10. Morales Briceño A, Méndez-Sanchez A, Perez-Arevalo J. Patrones de reconocimiento histopatológico de la deformación del borde dorsal del cuello en équidos. Estudio preliminar. Proceeding XXVII Reunión Anual SEAPV; 2015 June; Barcelona. Barcelona: p.17-95.
11. Morales-Briceño A, Escamilla-Sánchez A, Méndez-Angulo JL, Pérez-Arévalo J, Méndez-Sánchez A. Patrones de reconocimiento histopatológico de la deformación del borde dorsal del cuello en caballos de Pura Raza Española en Andalucía y Extremadura, España. XVIII Reunión de la Sociedad Española de Anatomía Patológica Veterinaria; 2016; Córdoba, Spain: Cordoba Junio, 2016. P28;
12. Rodríguez H, Ríos A, Sarabia L, Ossandón E, Araya J. Inmunohistoquímica de filamentos intermedios, tipo vimentina y desmina, y enzima enolasa en túbulos seminíferos seniles humanos. Rev Int Androl. 2004;2(1):9-14.
13. Sánchez MJ, Azor PJ, Molina A, Parkin T, Rivero JLL, Valera M. Prevalence, risk factors and genetic parameters of cresty neck in Pura Raza Español horses. Equine Vet J. 2016;49(2):196-200.
14. Treiber KH, Kronfeld DS, Hess TM. Evaluation of genetic and metabolic predispositions and nutritional risk factors for pasture-associated laminitis in horses. J Am Vet Med Assoc. 2006;228(10):1538-45.

 All rights reserved 2007.