BJVP
Brazilian Journal of Veterinary Pathology

Original full paper

T-2 mycotoxin intoxication in piglets: a systematic pathological approach and apoptotic immunohistochemical studies

María A. Quiroga[1*], Miguel A. Risso[1], Carlos J. Perfumo[1]

[1]Institute of Pathology, Faculty of Veterinary Sciences, La Plata National University,
***Corresponding author:** María A. Quiroga. Institute of Pathology. P. Box 296, B1900AVW, La Plata, Argentina. E-mail: mquiroga@fcv.unlp.edu.ar

Submitted September 5th 2008, Accepted January 29th 2009

Abstract

An experimental study was performed in order to analyze the histopathological findings of gastrointestinal mucosa and regional lymph-nodes in piglets intoxicated with T-2 toxin as well as the mechanism of T-2 induced apoptosis in the intestinal crypt epithelia. Sixteen piglets were divided into 4 groups receiving a single oral administration of T-2 toxin. Group A: 2.5 mg T-2/kg b.w.; group B: 2 mg T-2/kg b.w.; group C: 1.5 mg T-2/kg b.w.; group D: control group without toxin. Organ lesions were classified in grades 0 to 4 according with severity and were statistically analyzed. Apoptosis was examined in intestinal sections only in groups A and D. Group A piglets showed clinical signs and pathological changes related with those seen in circulatory shock. Microscopic lesions were observed only in pigs from groups A and B. In stomach, lesions consisted of congestion, hemorrhages and necrotic cells in the isthmus and neck regions. Submucosal edema and necrotic crypt epithelial cells were seen in duodenum, jejunum, ileum, cecum and colon. The greatest grade of lesions was observed in colon. In lymph node, grade of lymphocytes depletion and necrosis was significantly higher in cortex than paracortex. Apoptotic bodies were present in intestinal crypt cells, lymphoid cells from lamina propria and ileal Peyer´s patches. Apoptosis seems to be the mechanism involved in the development of intestinal lesions.

Key Words: T-2 mycotoxin, pig, apoptosis, pathology.

Introduction

Trichothecenes are mycotoxins commonly found on a worldwide basis in cereal grains, animal feeds and forages (2, 3, 21, 29). Many toxigenic species of *Fusarium* are the main producers of trichothecenes in cereals (21). Within the trichothecene group more than 150 compounds have been identified (20). Among them, deoxynivalenol (DON), nivalenol (NIV), 3-acetyl DON (3-ADON), diacetoxyscirpenol (DAS), T-2 toxin and HT-2 toxin occur frequently in grains such as wheat, maize, barley, oats and rice grown in the temperate regions of America, Europe and Asia (21, 29). There are evidences implicating these mycotoxins in livestock disorder in different parts of the world (13).

T-2 toxin is a potent inhibitor of protein synthesis both *in vivo* and *in vitro* (11, 33) and affect mitotic cells of the gastrointestinal tract and lymphoid system inducing necrosis and apoptosis (5, 10, 25, 31, 33).The effect of T-2 toxin on the immune response has been investigated showing that T-2 toxin is a potent immunosuppresor in a wide range of species (12, 31). It also has strong emetic effects and greatly reduces the feed intake (26).

Pigs are more sensitive to trichothecenes than other farm animals (3). Different pig breeds, ages and source of the toxin have been used in controlled experiments (3).The contamination of the pig diets with as little as 0.5 mg/kg T-2 toxin may have deleterious effects on a number of hematological and immunological variables and may represent high hazard to pig production

Brazilian Journal of Veterinary Pathology. www.bjvp.org.br . All rights reserved 2007.

(27). However, pigs are generally less severely affected because they refuse part or all any rations that contain these mycotoxins (26). Reduced feed intake or complete feed refusal and reduced weight gain have been observed when pigs were given 5–10 mg T-2 toxin/kg feed (3, 7, 8). Histological examination revealed that necrosis were present in the epithelial cells of the mucosa and in the crypt cells of jejunum and ileum, Peyer´s patches of the ileum, lymphoid elements of the cecum, spleen and lymph nodes of pigs administered intravenously with 0.13 to 3.2 mg T-2 toxin/kg body weight. The B and T dependent zones of the lymph nodes showed a depletion of lymphoid elements in pigs received feed contained 0.5 to 3 mg T-2 toxin/Kg (27). Although T-2 toxin induced necrosis has been described elsewhere, there is a lack of information in piglets with regard to the detailed histopathological changes found in the gut and regional lymph-nodes and the effects of T-2 as the effectors of the apoptotic mechanisms.

The aim of this study were to analyze the histopathological findings at different levels of gastrointestinal mucosa and regional lymph-nodes in piglets experimentally intoxicated with 3 different doses of T-2 toxin in a single oral administration as well as the mechanism of T-2 toxin induced apoptosis in the intestinal crypt epithelia.

Materials and methods

Animals and T-2 toxin

Sixteen crossbreed swine weighing an average of 5.9 kg were obtained from a commercial source, monitored of health and allowed to individual pens following the international guidelines (*Canadian Council on Animal Care, CCAC*). Commercial ration, mycotoxins free by previous analysis, and water were provided *ad libitum* until the start of assay.

T-2 toxin was prepared and purified from cultures of *Fusarium tricinctum* (NRRL 24631) (4). The standard mycotoxin and the crude extracts were applied to TLC plates pre-coated with silica Gel 60 and the plates were developed in a solvent system. Relative amounts of T-2 were determined by visual comparison with known amounts of standards under 365 nm UV light. The toxin was dissolved in 50% ethanol, diluted in 5 ml PBS solution and was administered as a single oral dose.

Pigs were fasted 12 hours before mycotoxin administration and thereafter clinical condition was recorded each hour. Animals were divided into 4 groups: group A: 4 animals inoculated with 2.5 mg T-2/kg body weight (b.w.); group B: 4 pigs inoculated with 2.0 mg T-2/kg b.w.; group C: 4 pigs inoculated with 1.5 mg T-2/kg b.w. and group D: 4 control pigs inoculated with 50% ethanol. In each group, male and female pigs were represented. All observable signs of toxicity were recorded. The pigs from group A were euthanized by humanitarian reason about 16 hours after treatment (HAT) according with the methods proposed by the American Association of Swine Practitioners -AASP- (National Pork Producers Council) and the remainder animals were sacrificed at 35 HAT. Necropsy was performed on animals, gross lesion registered and tissues were sampled for histopathology.

Histopathologic study

Tissue samples of brain, lung, heart, liver, pancreas, adrenal gland, kidney, stomach, small intestine (duodenum, jejunum and ileum), large intestine (cecum and colon), lymph nodes, spleen and tonsil were collected and fixed in 10% neutral-buffered formalin, embedded in paraffin, sectioned at 4 µm, stained with hematoxylin and eosin (HE) and examined by light microscopy. Sections of stomach (fundic region), duodenum, jejunum, ileum, cecum and colon were studied by random observation of 4 fields (objective magnification x40). The evaluated lesions were: a) stomach (gastric glands): necrosis of the epithelium (isthmus, neck and base regions); b) intestine: necrosis of absorptive and intestinal crypt epithelia, necrosis of lymphoid cells in the lamina propria and depletion/necrosis of ileal Peyer`s patches and lymphoid aggregates of colon and cecum.

In the same way necrosis and depletion of lymphoid cells from thymus, lymph nodes, spleen and tonsil were studied.

Above mentioned lesions were classified in grades from 0 to 4 according to severity, as follows:

-Epithelial cells necrosis: *grade 0: no necrotic cells, *grade 1: scattered necrotic cells, *grade 2: few necrotic cells, *grade 3: numerous necrotic cells, *grade 4: almost cells necrotic.

-Lymphocyte depletion: *grade 0: no depletion, *grade 1: slight depletion, *grade 2: moderate depletion, *grade 3: severe depletion, *grade 4: very severe depletion.

-Lymphocyte necrosis: *grade 0: no necrosis, *grade 1: slight necrosis, *grade 2: moderate necrosis, *grade 3: severe necrosis, *grade 4: very severe necrosis.

Statistical analysis

Microscopic lesions were analyzed by Fisher (ANOVA). A value of $P<0.05$ was considered significant (30).

In situ detection of fragmented DNA

DNA fragmentation was examined on the paraffin sections of duodenum, jejunum, ileum, cecum, and colon from groups A and D by the TUNEL method with a commercial apoptosis detection kit (ApopTag®Plus Peroxidase *In Situ* Apoptosis Detection Kit, Chemicon International, USA&Canada). Briefly, fragmented DNA 3´-OH ends on the section were labeled with digoxigenin-dUTP in the presence of terminal deoxynucleotidyl transferase (TdT). Peroxidase-conjugated anti-digoxigenin

antibody was reacted with the sections. Then the slides were incubated with DAB substrate solution at room temperature and counterstained with methyl green.

Apoptotic index (AI) of crypt epithelium was calculated using the number of pyknotic cells positively stained. Namely, AI (pyknotic cells/total cells counted x 100) in the intestine was calculated on 4 fields/section on randomly chosen (5 crypts/field).

Results

Clinical observations

Signs of emesis, chewing movements, ptialism, hind limbs locomotor´s disturbances, increased number of mictions, dullness, hypothermia and diarrhea were seen in group A pigs. Pigs from group B showed emesis, chewing movements and hind limbs weakness. Group C and D pigs appeared clinically normal.

Gross changes

Lesions were observed only in group A pigs killed at 16 HAT. Mesenteric fold edema of ascending colon, ascitis, edema gall bladder, congestion and hemorrhages of stomach, cecum and colon, diffuse cortical hemorrhages of adrenal glands, enlargement of mesenteric lymph-nodes and hemorrhages of spleen were the predominated changes.

Histopathologic study

Microscopic lesions were observed only in pigs from groups A and B. Distribution of organ lesions classified in grades from 0 to 4 and their statistically significance are showed in tables 1 to 3.

In stomach the lesions consisted of congestion and hemorrhages. Scattered to numerous necrotic cells were seen in the isthmus and neck regions. Necrosis of base region was not observed. There was statistically differences of grade of necrotic cells in both isthmus and neck, between groups A and B ($P<0.0001$) and within groups ($P< 0.05$) (fig.1 and table 1).

Submucosal edema and scattered to numerous necrotic crypt epithelial cells were seen in duodenum, jejunum, ileum, cecum and colon (fig. 2). Absorptive epithelium was not affected. Significative differences were seen in the grade of necrotic crypt cells and necrotic lymphoid cells of lamina propria between groups A and B ($P< 0.0001$) (table 2). Grade of depletion and necrosis of ileal Peyer`s patches were significantly higher in group A (1.87±0.09 and 4±0.0 respectively) than group B (0.67±0.25 and 0.67±0.0 respectively). The greatest grade of lesions was observed in colon ($P< 0.05$) (table 2).

Lymphoid aggregates of tonsils, white and red pulps of spleen, germinal centres of lymph-nodes, cortex and medulla of thymus showed depletion, pyknosis and karyorrhexis of lymphocytes.

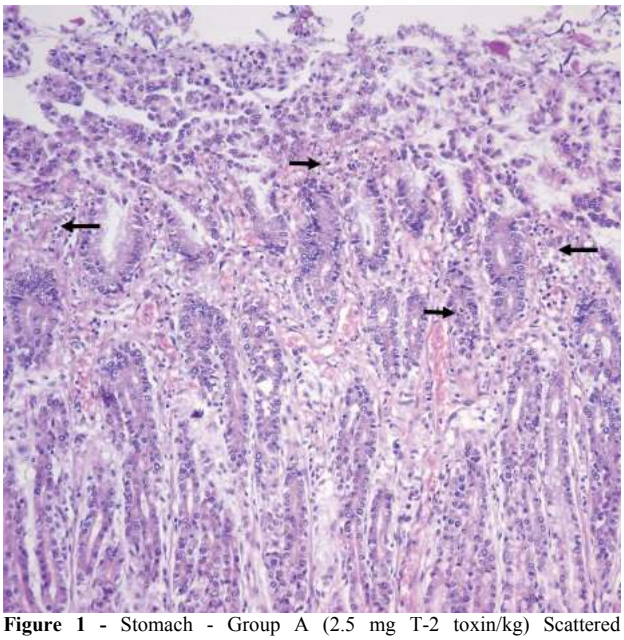

Figure 1 - Stomach - Group A (2.5 mg T-2 toxin/kg) Scattered karyopyknotic cells in the neck and isthmus zones (arrows). H&E. Obj. 20X.

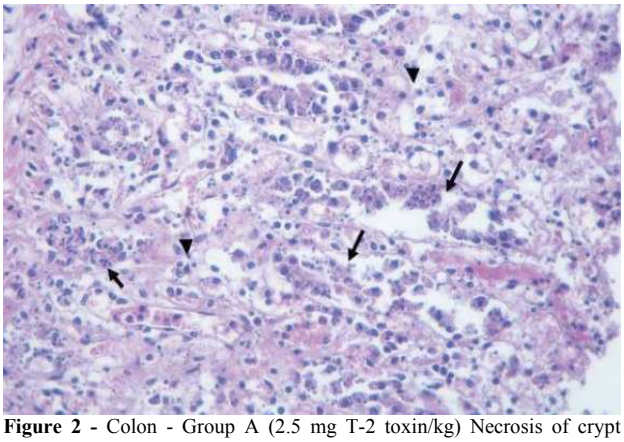

Figure 2 - Colon - Group A (2.5 mg T-2 toxin/kg) Necrosis of crypt epithelial cells (arrows) and lymphocytes in the lamina propria (arrow heads). H&E. Obj. 40x.

In addition, large mononuclear cells, morphologically resembling macrophages with abundant cytoplasm containing phagocytosed cell debris were observed. In thymus, grade of lymphocytes necrosis was significantly higher in cortex than medulla in group A ($P<0.05$)(table 3). In lymph node, grade of lymphocytes depletion and necrosis was significantly higher in cortex than paracortex ($P<0.05$) (table 3).

In adrenal gland, generalized hemorrhages with vacuolization and necrosis of cortical epithelial cells were evident.

In heart, small subendocardial hemorrhages, multifocal degeneration and necrosis of myofibers were evident.

The liver showed scattered hepatocytes with coagulative necrosis and edema of gall-bladder.

Coagulative necrosis of single or grouped acinar cells in pancreas was another change.

Table 1 - Stomach: graded score of necrotic cells in Groups A (2.5 mg T-2/b.w.) and B (2.0 mg T-2/b.w.).

Zone	Group	
	A (m±SEM)	B (m±SEM)
Isthmus	2.3 ± 0.15^{a}***	0.20±0.13***
Neck	1.7 ± 0.15^{b}***	0.20±0.13***

Data are expressed as means±SEM; n= 15 per group. (***) Means within the same region and raw, and with asterisks, indicate significant difference between groups ($P < 0.001$). $^{(a,b)}$ Means within the same column and with different superscripts letters (a, b), are significantly different ($P < 0.05$). Score level:*grade 0: no necrotic cells,*grade 1: scattered necrotic cells,*grade 2: mild necrotic cells,*grade 3: moderate necrotic cells,*grade 4: majority of necrotic cells

In situ detection of fragmented DNA

TUNEL histochemistry clearly revealed a distinct pattern of staining. Intense staining was observed in nuclei and nuclear fragments with the morphological characteristics of apoptosis. Apoptotic bodies in diverse forms and sizes were present in intestinal crypt cells, lymphoid cells from lamina propria and ileal Peyer´s patches (Fig. 3).

TUNEL histochemistry disclosed significant differences of the crypt epithelium. AI between groups A and D. Animals from group A showed a significantly higher number of apoptotic cells than control animals who showed an AI nearly 0%. Although there were no significant differences between intestinal regions, AI in the jejunum, ileum and colon were less (20.31%, 15.16%, 17.79% respectively) than duodenum and cecum (32.24% and 36.53% respectively).

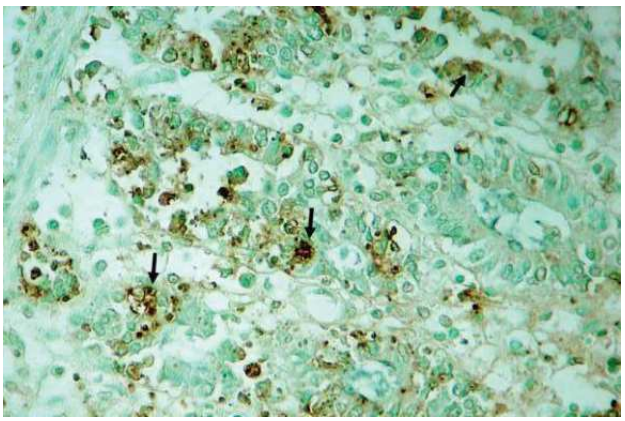

Figure 3 - Colon - Group A (2.5 mg T-2 toxin/kg). High number of crypt epithelial cells showing apoptosis (arrows) Immunohistochemical staining by TUNEL method. Obj. 40x

Discussion

In pigs, several lesions were induced by T-2 toxin when administered by oral gavages, inhalation, endovenous or topical routes (7, 15, 16, 17, 18, 19, 27, 36).

In the present study, pigs intoxicated with a single oral dose of 2 and 2.5 mg T-2/kg b.w. showed clinical signs and pathological changes related to those reported by inhalatory or endovenous exposure to this toxin (15, 27, 36).

Changes in posture and locomotion seen in groups A and B have been previously described in T-2 toxicoses (3, 16, 19, 36). Emesis was the common clinical sign observed. T-2 toxin and other trichothecenes such as DON or DAS can cause emesis (19). Although the vomiting seen in oral studies may result from localized gastrointestinal effect of the toxin, it has also been suggested that the emesis is due to a direct central effect on the medulla oblongata (19). In this study, necrosis in pancreas and heart found in group A might be a consequence of a direct cytotoxic effect of T-2 or secondary to a decrease of blood flow (15). It was suggested that trichothecene mycotoxins may have a direct effect on capillaries (16). Bilateral adrenal cortical necrosis and hemorrhages might be the results of systemic endotoxic shock that triggering a stress-like response (36).

Changes in the stomach mucosa were found mainly in the isthmus and glandular neck. Several pathway mechanisms have been proposed: a) direct cytotoxic effects of T-2 or its metabolites (16); b) indirect exposure of T-2 via blood circulation (25); c) reduced blood flow by shock-like syndrome (32); d) ischemia secondary to microvasculature injury (16) and e) inhibitory effect of T-2 on DNA synthesis on cells of high mitotic activity (3, 35).

In the intestine, the colonic crypt epithelium was the most sensitive to T-2 followed by duodenum and jejunum. This marked cellular impairment could be related to a long contact of these cells with the toxin or its toxic metabolites via the enterohepatic circulation (1).

In the present study, besides the necrotic crypt cells observed on HE-stained sections, some cells were positively stained by TUNEL method. Apoptotic index were higher in the cryptal cells of duodenum and cecum than the other intestinal region. Results were different of those seen in T-2-toxicated mice in which the above mentioned cells in the small intestine were more sensitive than those in the large intestine (25). In mice, normal small intestine show a low level of spontaneous apoptosis in the crypts while in the large bowel, is virtually absent (22, 23). The rapid intestinal turnover could make this tissue highly sensitive to cytotoxic agents. T-2 toxin is a potent inducer of apoptotic cell death (10, 24, 25). The mechanism that appears to be involved is the activation of several caspases, resulting in DNA fragmentation, chromosomal condensation and nuclear fragmentation (9). The heterogeneous response seen in intestinal regions might

Table 2 - Intestine: graded score of necrotic cells in Groups A (2.5 mg T-2/b.w.) and B (2.0 mg T-2/b.w.)

	Crypt epithelium (m±SEM)		**Lamina propria** (m±SEM)	
	Group A	**Group B**	**Group A**	**Group B**
Duodenum	2.73 ± 0.43^{b}***	0.13 ± 0.09^{a}***	1.66 ± 0.25^{a}***	$0.060.06\pm^{a}$***
Jejunum	2.80 ± 0.31^{b}***	0.26 ± 0.15^{b}***	1.93 ± 0.27^{b}***	0.13 ± 0.09^{b}***
Ileum	1.40 ± 0.20^{a}***	0.13 ± 0.09^{a}***	1.33 ± 0.21^{a}***	0.67 ± 0.25^{c}***
Cecum	1.78 ± 0.21^{a}***	0.15 ± 0.09^{a}***	2.13 ± 0.27^{b}***	0.67 ± 0.25^{c}***
Colon	3.46 ± 0.55^{c}***	0.40 ± 0.25^{c}***	3.53 ± 0.17^{c}***	0.67 ± 0.25^{c}***

Data are expressed as means±SEM; n= 15 per group. Means within the same region and raw, and with asterisks, indicate significant difference between groups ($P < 0.001$).[(a,b)] Intestinal Regions: means within the same column and with different superscripts letters (a, b, c) are significantly different ($P < 0.05$). Score level:*grade 0: no necrotic cells,*grade 1: scattered necrotic cells,*grade 2: mild necrotic cells,*grade 3: moderate necrotic cells,*grade 4: majority of necrotic cells

Table 3 - Lymphoid organs: graded score of lymphoid depletion and necrosis in Groups A (2.5 mg T-2/b.w.) and B (2.0 mg T-2/b.w.)

Organ	**Lymphoid depletion** (m±SEM)				**Lymphoid necrosis** (m±SEM)			
Thymus (n=15)	**Cortex**		**Medulla**		**Cortex**		**Medulla**	
	Group A	**Group B**	**Group A**	**Group B**	**Group A**	**Group B**	**Group A**	**Group B**
	2.00±0.00***	0.14±0.10***	2.14±0.10***	0.14±0.10***	1.71 ± 0.27^{a}****	0.14±0.10***	1.00 ± 0.15^{b}***	0.14±0.10***
Lymph node (n=25)	**Cortex**		**Paracortex**		**Cortex**		**Paracortex**	
	Group A	**Group B**	**Group A**	**Group B**	**Group A**	**Group B**	**Group A**	**Group B**
	2.92±0.18a***	1.20±0.23***	2.40±0.12b***	1.00±0.19***	3.36±0.11a***	0.24±0.09a***	2.72±0.09b***	0.08±0.06b***
Spleen (n=20)	**White pulp**		**Red pulp**		**White pulp**		**Red pulp**	
	Group A	**Group B**	**Group A**	**Group B**	**Group A**	**Group B**	**Group A**	**Group B**
	3.35±0.18***	0.70±0.28***	3.50±0.18***	0.75±0.30***	$.20\pm0.20^{a}$***	0.10±0.07***	$.00\pm0.16^{b}$***	0.10±0.07***
Tonsil (n= 20)	**Nodular lymphoid tissue**		**Diffuse lymphoid tissue**		**Nodular lymphoid tissue**		**Diffuse lymphoid tissue**	
	Group A	**Group B**	**Group A**	**Group B**	**Group A**	**Group B**	**Group A**	**Group B**
	1.85±0.15***	0.55±0.22***	2.00±0.15**	0.75±0.30**	2.75±0.14***	0.25±0.10***	2.60±0.15***	0.25±0.10***

Data are expressed as means±SEM; n= 15 per group. (*) Means within the same region and raw, and with asterisks, indicate significant difference between groups (*) $P < 0.05$; (**) $P < 0.01$; (***) $P < 0.001$. [(a,b)] Means of groups, within the same raw but different region and with different superscripts letters, are significantly different ($P < 0.05$). Score level: *grade 0: no depletion, *grade 1: slight depletion, *grade 2: moderate depletion, *grade 3: severe depletion, *grade 4: very severe depletion. *grade 0: no necrotic cells,* grade 1: scattered necrotic cells,* grade 2: mild necrotic cells,*grade 3: moderate necrotic cells,*grade 4: majority of necrotic cells

represent a different cellular susceptibility defined by the topological position of each epithelial cell within the crypt, the different expression of family genes whose products are capable of both suppressing and promoting apoptosis and the dose mycotoxin- response relationship (23).

The occurrence of necrotic lymphocytes in the lamina propria and Peyer's patches probably reflects an inhibitory effect of T-2 on protein synthesis and the damage in the immune system. Li et al examined T-2 toxin-induced changes in mouse Peyer's patches and found that morphological characteristics of dead lymphocytes were well compatible with those of apoptosis (10).

Mesenteric lymph nodes and spleen were the most severely lymphoid organs affected, followed by tonsil, and thymus. Both, T and B dependent areas were comprised. Similar changes were described in laboratory animals (6, 28, 34).

In summary, pigs intoxicated with a single oral dose of 2.5 mg/kg b.w. of T-2 showed clinical signs and pathological changes related with those seen in circulatory shock and similar with those reported in other animal species after T-2 treatment. In addition, apoptosis seems to be the mechanism involved in the development of the intestinal lesions.

References

1. CODDINGTON KA., SWANSON S.P., HASSAN A.S. & BUCK W.B. Enterohepatic circulation of T-2 toxin metabolites in the rat. *Drug Metabolism and Disposition,* 1989, 17: 600-605.
2. D´MELLO JPFD., PLACINTA C.M. & MACDONALD A.M.C. *Fusarium* mycotoxins: a review of global implications for animal health, welfare and productivity. *Anim. Feed Sci. Technol,*

1999,. 80: 183-205.
3. ERIKSEN GS., PETTERSSON H. Toxicological evaluation of trichothecenes in animal feed. *Anim. Feed Sci. Technol.,* 2004, 114: 205-239.
4. FAIFER GC., GODOY HM. Acute effects of T-2 toxin on radioactive iron incorporation into circulating erythrocytes in mice. *Toxicology*, 1991, 70: 133-140.
5. GALTIER P. Biological fate of mycotoxins in animals. *Revue Méd. Vét*, 1998,. 149: 549-554.
6. GLAVITS R., VANYI A.. Effect of trichothecene mycotoxins (satratoxin H and T-2 toxin) on the lymphoid organs of mice. *Acta Vet. Hungarica*, 1988, 36: 37-41.
7. HARVEY RB., KUBENA LF., HUFF WE., CORRIER DE., ROTTINGHAUS GE. , PHILLIPS TD. Effects of treatment of growing swine with aflatoxin and T-2 toxin. *Am. J. Res*., 1990, 51: 1688-1693.
8. HARVEY RB., KUBENA LF., ELISSALDE MH., ROTTINGHAUS GE., CORRIER DE. Administration of ochratoxin A and T-2 toxin to growing swine. *Am. J. Vet. Res.,* 1994, 55: 1757-1761.
9. HOLME JA., MORRISON E., SAMUELSEN JT., WIGER R., LAG M., SCHWARZE PE., BERNHOFT A., REFSNES M. Mechanisms involved in the induction of apoptosis by T-2 and HT-2 toxins in HL-60 human promyelocytic leukemia cells. *Cell Biol. Toxicol.*, 2003, 19: 53-68.
10. LI GM., SHINOZUKA J., UETSUKA K., NAKAYAMA H., DOI K. 1997. T-2 toxin-induced apoptosis in Peyer's patches of mice. *J. Toxicol. Pathol.* , 1997, 10: 59-61.
11. MURTHY MR., RADOUCO-THOMAS S., BHARUCHA AD., LEVESQUE G., PANDIAN S , RADOUCO TC. Effects of trichothecenes (T-2 toxin) on protein synthesis in vitro by polysomes and messenger RNA. *Prog. Neuropsychopharmacol. Biol. Psychiatry*, 1985, 9: 251-258.
12. OSWALD IP., COMERA C. Immunotoxicity of mycotoxins *Revue Méd. Vét*, 1998, 149: 585-590.
13. OSWEILER, GD. Occurrence and clinical manifestations of trichothecene toxicoses and zearalenone toxicoses. In: Richard, J.L.; Thurston, J.R. (eds.): Diagnosis of mycotoxicoses. Martinus Nijhoff Publishers, Ames, Iowa, 31-42, 1986.
14. OSWEILER GD. Mycotoxins. In: Leman, AD.; Straw BE.; Mengeling WL., D′Allaire SD.; Taylor DJ. (eds.): Disease of swine. 7th. Ed., Iowa State University Press, Ames, IOWA, 735-743, 1992.
15. PANG VF., ADAMS JH., BEASEY VR., BUCK WB., HASCHEK WM. Myocardial and pancreatic lesions induced by T-2 toxin, a trichothecene mycotoxin, in swine. *Vet. Pathol*, 1986, 23: 310-319.
16. PANG VF., SWANSON SP., BEASLEY VR., BUCK WB., HASCHEK WM. The toxicity of T-2 toxin in swine following topical application. I. Clinical signs, pathology and residue concentrations. *Fundamental and Applied Toxicology*, 1987a, 9: 41-49.
17. PANG VF., LAMBERT RJ., FELSBURG PJ., BEASLEY VR., BUCK WB., HASCHEK WM. Experimental T-2 toxicosis in swine following inhalation exposure: effects on pulmonary and systemic immunity and morphologic changes. *Toxicol. Pathol.,* 1987b*,* 15: 308-319.
18. PANG VF., LORENZANA RM., BEASLEY VR., BUCK WB. , HASCHEK WM. Experimental T-2 toxicosis in swine. III.Morphologic changes following intravascular administration of T-2 toxin. *Fundam. Appl. Toxicol.*, 1987c, 8: 298-309.
19. PANG VF., LAMBERT RJ., FELSBURG PJ., BEASLEY VR., BUCK WB., HASCHEK WM. Experimental T-2 toxicosis in swine following inhalation exposure: clinical signs and effects on hematology, serum biochemistry, and immune response. *Fundam. Appl. Toxicol*, 1988,. 11: 100-109.
20. PITTET A. Natural occurrence of mycotoxins in foods and feeds. An updated review. *Revue Méd. Vét*, 1998,. 149: 479-492.
21. PLACINTA CM., D´MELLO JPF. , MACDONALD AMC. A review of worldwide contamination of cereal grains and animal feed with *Fusarium* mycotoxins. *Anim. Feed Sci. Technol*, 1999,. 78: 21-37.
22. POTTEN CS., WILSON .W. , BOOTH C. Regulation and significance of apoptosis in the stem cells of the gastrointestinal epithelium. *Stem Cells*, 1997, 15: 82-93.
23. POTTEN CS. Apoptosis induced in small intestinal crypts by low doses of radiation protects the epithelium from genotoxic damage. International Congress Series, 2002, 1236: 407-413.
24. QUIROGA, MA.; ITAGAKI S., DOI K. Early ultrastructural changes of thymocytes in T-2 toxicated mice. *J. Toxicol. Pathol*, 1993,. 6: 109-112.
25. QUIROGA MA., RISSO MA., PERFUMO CJ., IDIART JR., OHTSUKA R., DOI K. Sequence of and regional difference in apoptotic index in the mouse gastrointestinal mucous epithelia after T-2 toxin inoculation. *J. Toxicol. Pathol*, 2000,. 13: 193-196.
26. RAFAI P, BATA A., VANYI A., PAPP Z., BRYDL E., JAKAB L., TUBOLY S., TURY E. Effect of various levels of T-2 toxin on the clinical status, performance and metabolism of growing pigs. *Vet. Rec*, 1995a, 136: 485-489.
27. RAFAI P., TUBOLY S., BATA A., TILLY P., VANYI A., PAPP Z., JAKAB L. , TURY E. Effect of various levels of T-2 toxin in the immune system of growing pigs. *Vet. Rec.,* 1995b, 136: 511-514.
28. SCHIEFER HB., HANCOCK DS. Systemic effects of topical application of T-2 toxin in mice. *Toxicol. Appl. Pharmacol.* 1984, 76: 464-472.
29. SCHLATTER J. Toxicity data relevant for hazard characterization. *Toxicol. Lett.,* 2004, 153: 83-89.
30. SHESKIN D. The Handbook of Parametric and Nonparametric Statistical Procedures. Third edition,

CRC Press, editor.1193 pp., 2003.
31. SHARMA RP. Immunotoxicity of Mycotoxins. *J. Dairy Sci*., 1993, 76: 892-897.
32. SMITH TK. Recent advances in the understanding of *Fusarium* trichothecene mycotoxicoses. *J. Anim. Sci.*, 1992, 70: 3989-3993.
33. THOMPSON WL., WANNEMACHER R.W. JR. In vivo effects of T-2 mycotoxin on synthesis of protein and DNA in tissues. *Toxicol. Appl. Pharmacol.*. 1990, 105: 483-491.
34. THURMAN JD.; CREASIA, D.A. , TROTTER, R.W. Mycotoxicosis caused by aerosolized T-2 toxin administered to female mice. *Am. J. Vet. Res*, 1988,. 49: 1928-1931.
35. UENO Y. Mode of action of trichothecenes. *Ann. Nutr. Alim*, 1977,. 31: 885-900.
36. WEAVER GA., KURTZ HJ., BATES FY., CHI MS., MIROCHA CJ., BEHRENS JC. , ROBISON TS. Acute and chronic toxicity of T-2 mycotoxin in swine. *Vet.Rec*, 1978,. 103: 531-535.

Brazilian Journal of Veterinary Pathology. www.bjvp.org.br . All rights reserved 2007.