



## Case Report

# Salivary gland adenocarcinoma in an orange-spined hairy dwarf porcupine (*Sphiggurus villosus*)

Lívia Perles<sup>1</sup>, Fernando Y. K. Kawamoto<sup>2</sup>, Andresa Matsui<sup>1</sup>, Julia M. Ribeiro<sup>1</sup>,  
Rosemeri de O. Vasconcelos<sup>1</sup>, Karin Werther<sup>1\*</sup>

<sup>1</sup>Department of Veterinary Pathology, Faculdade de Ciências Agrárias e Veterinárias (FCAV), Universidade Estadual Paulista “Julio de Mesquita Filho” (UNESP), Jaboticabal, SP, Brazil.

<sup>2</sup>Department of Veterinary Surgery, Faculdade de Ciências Agrárias e Veterinárias (FCAV), Universidade Estadual Paulista “Julio de Mesquita Filho” (UNESP), Jaboticabal, SP, Brazil.

\*Corresponding author: Faculdade de Ciências Agrárias e Veterinárias (FCAV), Universidade Estadual Paulista “Julio de Mesquita Filho” (UNESP), via de Acesso Prof. Paulo Donato Castellane s/n, Jaboticabal, SP, 14884-900 Brazil. E-mail: werther@fcav.unesp.br

Submitted September 8<sup>th</sup> 2016, Accepted November 28<sup>th</sup> 2016

---

## Abstract

The goal of this case report is to describe a salivary gland adenocarcinoma in a free ranging *Sphiggurus villosus*. A orange-spined hairy dwarf porcupine (*S. villosus*) was referred to the Wildlife Medicine Service at the Veterinarian Hospital of the Universidade Estadual Paulista (Jaboticabal, São Paulo, Brazil), with a mass in the lateral region of the face. Radiographs highlighted swelling in the soft tissues, measuring 7 cm x 9 cm, without bone involvement. The physical examination and radiographs were consistent with a neoplastic process. The animal was submitted to surgical excision of the mass. Microscopically, the tumor was composed of a highly cellular proliferation of epithelial cells arranged predominantly in tubular pattern, associated with moderated fibrous stroma, poorly demarcated, non-encapsulated and with infiltrative growth. These findings were consistent with salivary gland adenocarcinoma. To the authors' knowledge, this is the first report of a salivary gland adenocarcinoma in a wild life orange-spined hairy dwarf porcupine.

**Key words:** rodentia, wildlife, neoplasia, surgery, clinical-histological diagnostic.

---

## Introduction

The orange-spined hairy dwarf porcupine (*Sphiggurus villosus*) belongs to the largest order of the mammals, the Rodentia. It is a nocturnal and arboreal animal, measuring about 70 cm in the total length and has the body covered with long hair and thorns. The species is present in Atlantic forest habitat and has a folivorous diet (10). It is classified as “least concern” at the IUCN red list of threatened species (11). This animal is occasionally found near urban areas and the main threats are road kills and attacks by domestic dogs (10).

Primary salivary gland neoplasia is rare in dogs and cats, and are usually the result of secondary invasion of tumors affecting surrounding tissues (2, 9). The

submandibular salivary glands are most often involved, with the parotid gland second in frequency (17). Adenocarcinoma is the most frequent type of salivary gland tumor diagnosed in cats and dogs, representing 67.4% of all neoplasms, followed by carcinomas with 13.8%, mixed tumors with 6.5%, adenomas and squamous cells both with 2.9%, and fibrosarcoma and mast cells with 0.7% (1). Metastases to lymph nodes, bones, and other organs occur more frequently in cats than in dogs (8). The most common clinical signs of salivary gland neoplasia in dogs and cats are a slowly enlarging mass or painless swelling in the area of the salivary gland, anorexia, halitosis, dysphagia and weight loss (1, 7). Diagnosis of salivary gland neoplasia includes clinical examination, skull and thoracic radiographs, advanced imaging

techniques, such as computed tomography, and cellular characterization through cytology and histopathology (4, 12).

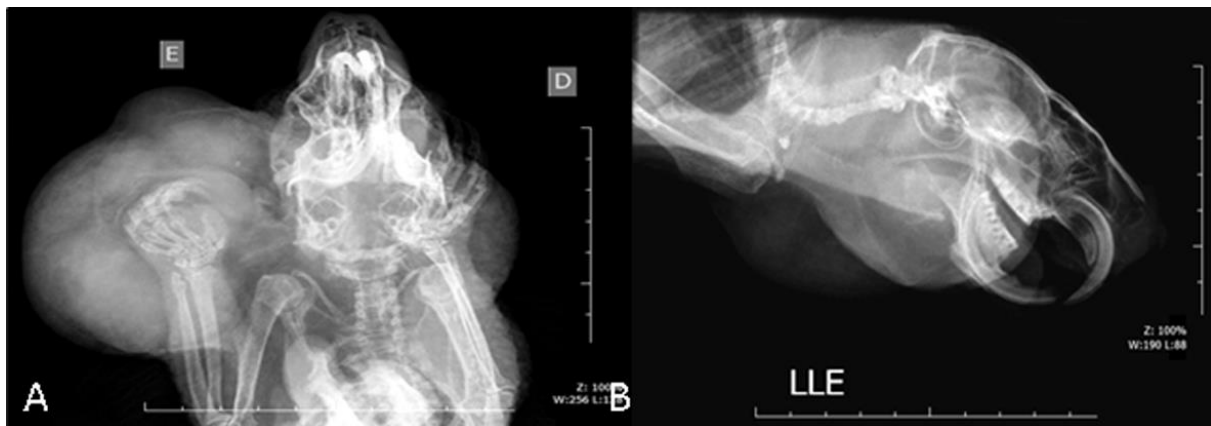There is a paucity of published articles about diseases in wildlife orange-spined hairy dwarf porcupine, including tumors. This report describes a case of salivary gland adenocarcinoma in a wild *S. villosus*.

### Case report

An adult male 1,6 kg orange-spined hairy dwarf porcupine was referred to the Wildlife Medicine Service at the Veterinary Hospital of Universidade Estadual Paulista (Jaboticabal, São Paulo, Brazil), with a mass in the left region of the face. At physical examination, the animal was alert and responsive, presented a mild dehydration (6%), and abnormal occlusion of incisor teeth. The remaining external physical examination was within normal limits. Radiographs were obtained with the patient under sedation with tiletamina-zolazepam (5 mg/kg,

intramuscular, Zoletil 50, Virbac Brazil). Dorsoventral, lateral, and oblique radiographic projections of the cranium revealed swelling in soft tissues, measuring 7 cm x 9 cm with regular and well-demarcated borders, in the left side of the skull, in the same area of the salivary gland (Fig. 1). There were no evidences of bone involvement. Thoracic radiographs demonstrated collapse of the tracheal lumen diameter in cervical and cervical-thoracic portions. In addition, there was pulmonary opacification with diffuse bronchial pattern suggestive of bronchitis or respiratory effort due to trachea collapse. No significant abnormalities were observed on lateral or ventrodorsal whole-body radiographs. Ultrasonographic examination of the abdomen was unremarkable.

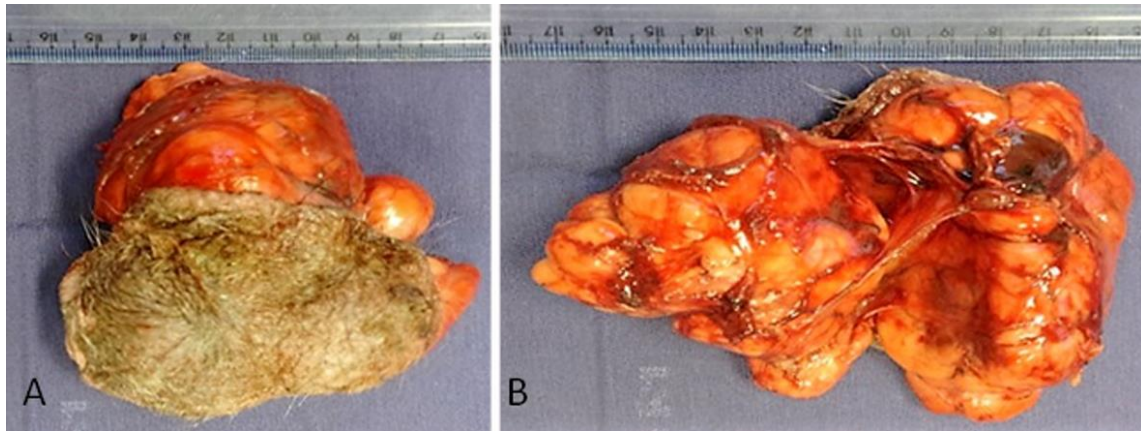
Based on the clinical examination and radiographic findings a neoplastic process was the main differential. Fine needle aspiration was performed, but there were no conclusive findings. Thus, surgical excision was performed, followed by histopathological examination.



**Figure 1.** Swelling in soft tissues, measuring 7 cm x 9 cm with regular and well-demarcated borders, in the left side of the skull cap topographically related to salivary gland with no evidences of bone commitment. (A) Dorsoventral radiographic projection of the cranium. (B) Lateral radiographic projection of the cranium.

Grossly it was an 11.5 x 9.0 x 7.0 cm, firm, multilobulated, and ulcerated mass. The cut surface was heterogeneous and whitish, well demarcated and solid (Fig. 2). Tissue was fixed in 10% neutral buffered formalin (pH 7.4) and processed routinely for histological examination. Microscopically, the mass was poorly demarcated, non-encapsulated and infiltrated to adjacent adipose tissue (Fig. 3A). It was composed of a highly cellular proliferation of epithelial cells arranged predominantly in tubular pattern (Fig. 3A), associated with moderate fibrous stroma (Fig. 3B). Some tubules exhibited

mucinous differentiation (Fig. 3C). Neoplastic cells had indistinct borders and moderate, acidophilic, and fibrillar cytoplasm. The nuclei were round and hypochromic with prominent, sometimes aberrant, acidophilic nucleoli (Fig. 3C). There were moderate anisokaryosis and accentuated karyomegaly with seven mitotic figures per high power field. Mild and multifocal areas of inflammatory infiltrate composed of lymphocytes was observed associated with the tumor stroma (Fig. 3D). These findings were suggestive of salivary gland adenocarcinoma, due to the anatomical site and the histological features of the tumor.



**Figure 2.** (A) Skin tissue fragment with mass adhered measuring 9 cm. (B) Note the mass is multilobular, red-white color, measuring 11.5 cm.

## Discussion

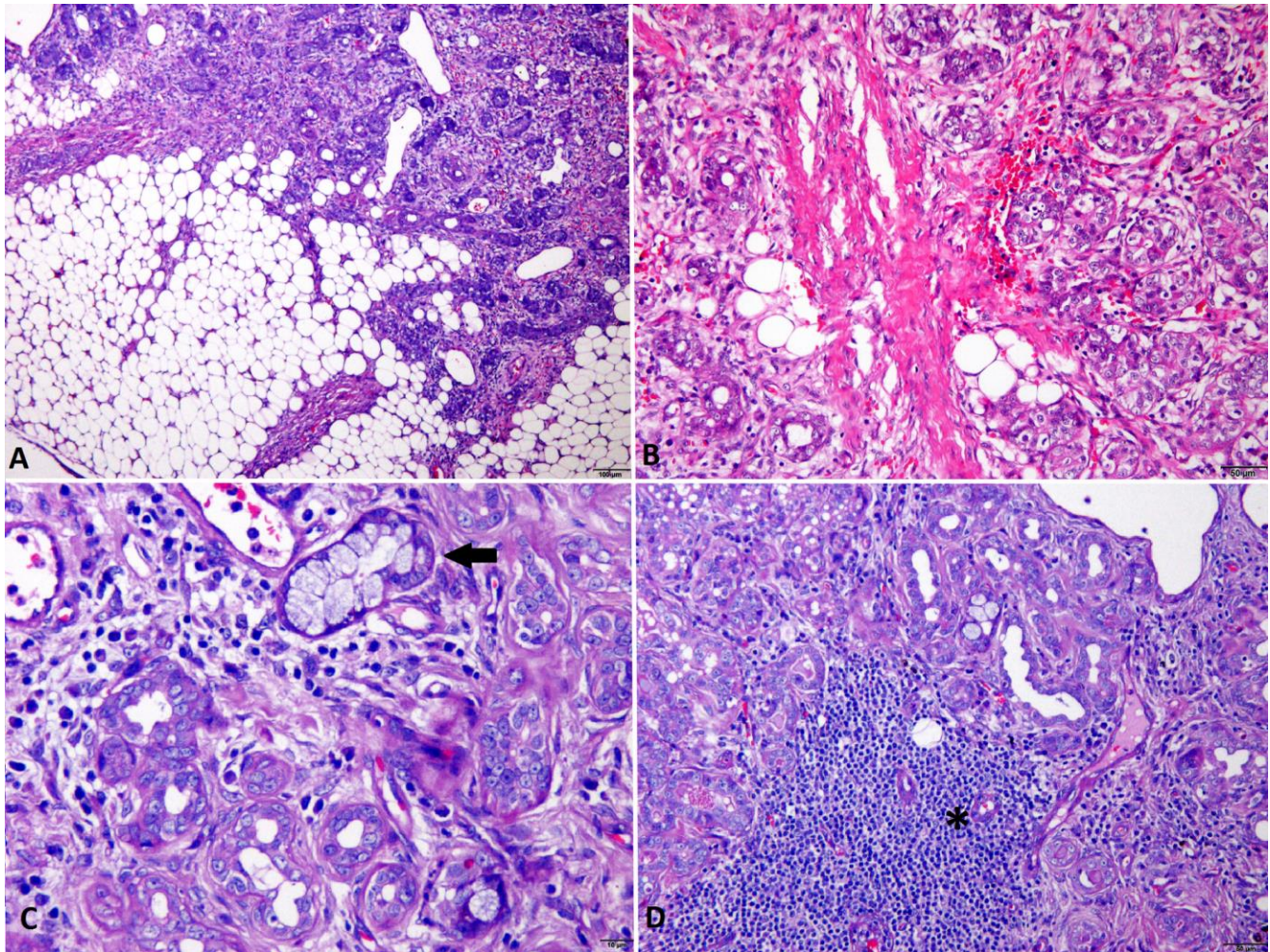
There are scarce data regarding tumors in wildlife, and little is known about the resistance or susceptibility of these animals to neoplastic diseases (15). Researches with captive wild mammals and birds have indicated that all taxonomic groups may not be equally affected and that there may be distinct differences in organ and tissue susceptibility to tumor growth (15).

Neoplasms of salivary glands are unusual in domestic animals, but have been described in dogs, cats, sheep, horses, guinea pigs and goats (8, 16). Studies have shown that the prevalence of salivary gland neoplasms in dogs and cats is approximately 0.17%, with cats being most often affected than dogs (1). In wildlife, there are few studies reporting the occurrence of these tumors in salivary glands. In a retrospective study conducted in Brazil, from 1974 to 1996, only two cases of neoplasia in the oral cavity were diagnosed in captive animals, in a total of 28 animals affected by tumors (18). In free-living animals, there is no data on its prevalence, becoming important to describe the occurrence of tumors in wild animals as in this case. We have not found any case of neoplasm in *S. villosus* in the literature.

The reported mean age of patients with salivary tumors is 10 years for dogs and 12 years for cats (8). There is no statistics about the mean age of wildlife animals with salivary neoplasms. It is not possible to affirm the exact age of the animal, but due to physical characteristics such as pigmentation of the incisors and the radiographic findings (spondylosis in several thoracic and lumbar vertebrae) it is estimated that the orange-spined hairy dwarf porcupine had advanced age.

Identification of the gland of origin can be challenging if the history of the animal is unknown and if the dimension of the neoplasm is extensive (7). In this case, given the anatomic location and clinical presentation, salivary gland is the most likely gland of origin. Rodents and lagomorphs have numerous pairs of salivary glands, like other mammals (3). The glands are parotid, mandibular (or submaxillary), sublingual and zygomatic (12). There are two types of secretory cells in salivary glands: serous cells and mucous cells. Each gland can be serous, mucous or mixed. Mucous cells are cuboidal and organized as tubules and serous cells are pyramidal in shape, with a large base and narrow apical surface facing the lumen of the acinus they form (3).

Similar to what happens to all domestic rodents, porcupines can present a malocclusion of the incisors teeth due to improper wear, resulting in overgrowth (5). In these cases, animals can present clinical signs as anorexia, weight lost, lethargy and hypersalivation (5). These signs were similar to those found in the animal of this report. After surgical removal of the tumor and reestablishment of proper occlusion, the animal improved its clinical and body condition. This report describes the clinical presentation, imaging and pathology findings of a salivary gland adenocarcinoma in an orange-spined hairy dwarf porcupine (*S. villosus*). Diseases that affect salivary glands of dogs and cats may have inflammatory, neoplastic or traumatic origin, and the differential diagnosis becomes fundamental to direct their treatment (6, 14). Tumors affecting the salivary glands should be included in the differential diagnosis of mandibular nodulations in wild animals.



**Figure 3.** Photomicrograph of a salivary gland carcinoma in a *Sphiggurus villosus*. (A) The tumor presents a neoplastic proliferation of infiltrative growth invading the adjacent adipose tissue (4x obj.). (B) The tumor was composed of a highly cellular proliferation of epithelial cells arranged in tubular pattern, associated with moderated fibrous connective tissue (20x obj.). (C) The nuclei were round and hypochromic with prominent, sometimes aberrant, acidophilic nucleoli. Arrow: Some tubules exhibit mucinous differentiation (20x obj.). (D) Focal areas of inflammatory infiltrate (\*) composed of lymphocytes was observed associated with the tumor stroma (20x obj.). Hematoxylin and eosin.

### References

1. Carberry CA, Flanders JA, Harvey HJ, Ryan AM. Salivary gland tumors in dogs and cats: a literature and case review. *J Am Anim Hosp Assoc.* 1988;24:561-7.
2. Barker IK, Van Dreumel AA. The alimentary system. In: Jubb KVF, Kennedy PC, Palmer N, editors. *Veterinary Pathology.* 6th ed. New York: Academic Press; 1993. p. 31-33.
3. Bercier M, Guzman DSM, Stockman J, Zwingenberger A, Vapniarsky N, Lowestine L, Hawkins MG. Salivary gland adenocarcinoma in a domestic rabbit (*Oryctolagus cuniculus*). *J Exot Pet Med.* 2013;22:218-24.
4. Burek KA, Munn RJ, Madewell BR. Metastatic adenocarcinoma of a minor salivary gland in a cat. *J Vet Med A Physiol Pathol Clin Med.* 1994;41:485-90.
5. Donnelly TM, Schaeffer DO. Disease problems of guinea pigs and chinchillas – Part B. In: Hillyer EV, Quesenberry KE, editors. *Ferrets, rabbits, and rodents. Clinical medicine and surgery.* Philadelphia: Saunders; 1997. p. 271-2.
6. Gioso MA. *Odontologia Veterinária para o Clínico de Pequenos Animais.* 2nd ed. São Paulo: Manole; 2007. 145p.
7. Hammer A, Getzy D, Ogilvie G, Upton M, Klausner J, Kisseberth WC. Salivary gland neoplasia in the dog and cat: survival times and prognostic factors. *J Am Anim Hosp Assoc.* 2001;37:478-82.
8. Head KW. Tumours of the upper alimentary tract. *Bull World Health Organ.* 1976;53(2-3):145-66.

9. Jones TC, Hunt RD, King NW. The digestive system. In: Jones TC, Hunt RD, King NW, editors. Veterinary Pathology. 6th ed. London: Williams and Wilkins; 1997. p. 1053-4.
10. Lange RR, Schmidt EMS. Rodentia: Roedores silvestres (capivara, cutia, paca, ouriço). In: Cubas ZS, Silva JCR, Catão-Dias JL, editors. Tratado de Animais Selvagens. 1st ed. São Paulo: Roca; 2007. p. 475-91.
11. Leite Y, Patterson B. 2008. *Sphiggurus villosus*. The IUCN Red List of Threatened Species 2008: <http://dx.doi.org/10.2305/IUCN.UK.2008.RLTS.T20634A9216258.en>. Downloaded on 24 April 2016.
12. Mazullo G, Sfacteria A, Iannelli N, De Majo M, Pennisi MG. Carcinoma of the submandibular salivary glands with multiple metastases in a cat. Vet Clin Pathol. 2005;34:61-4.
13. Morris J, Dobson J. Small animal oncology. 1st ed. Hoboken: Wiley-Blackwell 2001.
14. Pignone VN, Contesini EA, Pinto LAT, Oliveira R. Diagnóstico diferencial de afecções das glândulas salivares em cães e gatos. J Bras Ciên Anim. 2010;3:242-5.
15. Ratcliffe HL. Incidence and nature of tumors in captive wild mammals and birds. Am J of Cancer. 1993;17:116-35.
16. Spangler WL, Culbertson MR. Salivary gland disease in dogs and cats: 245 cases (1985-1988). J Am Vet Med Assoc. 1991;198:465-9.
17. Sozmen M, Brown PJ, Eveson JW. Sebaceous carcinoma of the salivary gland in a cat. J Vet Med A Physiol Pathol Clin Med. 2002;49:425-7.
18. Werner PR, Chiquito M, Pachaly JR. Estudo retrospectivo das neoplasias diagnosticadas em animais selvagens ou exóticos pelo serviço de patologia do Hospital Veterinário da Universidade Federal do Paraná entre 1974 e 1996. Arch Vet Sci. 1998;3(1):39-44.