BJVP
Brazilian Journal of Veterinary Pathology
ISSN 1983-0246

**Case Report**

# Estrogen and progesterone receptors immunolabeling in mammary solid carcinoma in an African Hedgehog (*Atelerix albiventris*) with concurrent uterine fibrosarcoma

Natália C. C. A. Fernandes[1]*, Rodrigo A. Réssio[1], Juliana M. Guerra[1], Danilo G. Wasques[2], Maria Lucia Z. Dagli[3]

[1]Instituto Adolfo Lutz, São Paulo, SP, Brazil.
[2]Histopet, São Paulo, SP, Brazil.
[3]Faculdade de Medicina Veterinária e Zootecnia, Universidade de São Paulo, Brazil.
[*]**Corresponding Author:** Av. Dr. Arnaldo, 355. Sétimo andar, São Paulo, SP. Zip Code: 01246-000, Brazil. E-mail: nccafernandes@yahoo.com.br

Submitted November 2nd 2016, Accepted January 30th 2017

**Abstract**

The African Hedgehog (*Atelerix albiventris*) has gained popularity as a pet in several parts of the world. This is a report of a concomitant finding of spontaneous mammary and uterine tumors in an adult female African Hedgehog. The animal presented abdominal masses and died suddenly. Upon necropsy, not only the mammary tumor mass, but also a uterine neoplasm was found. Formalin fixed and paraffin embedded tissues were submitted for histopathological examination. The mammary tumor was diagnosed as a solid carcinoma, and the uterine tumor as fibrosarcoma. By immunohistochemistry, the mammary tumor showed positivity for pancytokeratins and estrogen and progesterone receptors, while the uterine neoplasm exhibited positivity for vimentin. There was high cross-immunoreactivity between anti-human antibodies. The positivity for hormonal receptors antigens may represent a relationship between estrogen and progesterone levels and the development of mammary tumors, as in other mammals.

**Key words:** wild animals, exotic animals, cancer, histopathology, concurrent tumors, progesterone receptor, estrogen receptor, immunohistochemistry, diagnosis.

## Introduction

African hedgehog (*Atelerix albiventris*) became a common pet in United States (6, 11), and its popularity is gradually increasing in Brazil. However, scientific literature on diseases that affect these small animals is scarce worldwide and nationally (10, 14). Neoplasms are often found in African hedgehogs, especially over the age of three years (6), and include skin tumors, neuro-endocrine, reproductive, hemolymphoid, among others (3). Similarly to other wild animals, the high prevalence of neoplastic diseases in this species (which are mostly malignant) may be a result of an increase in the expected lifespan of hedgehogs in captivity (13). The present report describes a case of an African hedgehog presenting with simultaneous mammary carcinoma and uterine sarcoma, diagnosed by histopathology and immunohistochemistry with the use of human commercial antibodies. Also, it describes the expression of estrogen and progesterone receptors in neoplastic mammary cells.

## Case report

Formalin-fixed tissue samples from a necropsy of an adult female African hedgehog (*Atelerix albiventris*) were submitted for histopathological analysis. The necropsy report described concomitant mammary and uterine tumors, without the presence of tumors in other organs. Tissues obtained at the necropsy were fixed in formalin, embedded in paraffin and sent to

 All rights reserved 2007.

histopathological and immunohistochemical analysis. For the immunostainings, antigen retrieval with solution of citrate buffer, pH 6.0 in pressure cooker for three minutes at 120ºC was applied, following blockage of endogenous peroxidase for 30 minutes. The used antibodies, their sources and dilutions are presented in Table 1. All antibodies were diluted in a phosphate-buffered saline, with 1% of bovine serum (pH 7.4), and incubated for 18 hours at 4ºC. Amplification was performed with Picture Max Kit (Life Technologies, Carlsbad, CA, USA), for 30 minutes at 37ºC. After development with 100 mg of 3.3 '-diaminobenzidine (D-5637; Sigma, St. Louis, MO, USA) diluted in PBS (pH 7.4) for 5 minutes at 37°C, samples were counterstained with Harris hematoxylin for 30 seconds at room temperature, dehydrated and histoslides mounted with synthetic resin. The reaction was observed in an optical microscope, and signal was subjectively graded as weak, moderate or strong, and the proportion of stained cells was also subjectively evaluated. The crossed immunoreactivity was considered when internal control was positively stained.

Histologically, the mammary tumor was multilobular and infiltrative, and consisted of round to polygonal cells arranged in a solid pattern, sometimes with central cystic degeneration. Neoplastic cells had scant cytoplasm, granular chromatin and inconspicuous nucleoli. The cellular pleomorphism was high, with loss of cell polarity and high mitotic index, with atypical mitotic figures (Fig. 1). The uterine tumor consisted of a mildly infiltrative neoplasm, composed of spindle cells arranged in a storiform pattern. The cells displayed scant eosinophilic cytoplasm, sometimes finely fibrillary, and spindle nuclei with granular chromatin. The pleomorphism was moderate, with atypical nuclei and rare mitotic figures (Fig. 2).

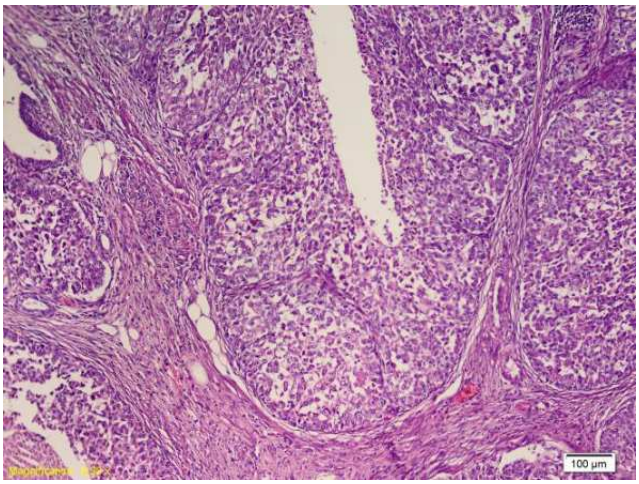


**Figure 1.** Mammary neoplasm in *Atelerix albiventris*. The image shows multiple multilobular tumor in a solid pattern, with round to polygonal cells with scant cytoplasm, granular chromatin and inconspicuous nucleoli. Hematoxylin and eosin, Bar = 100 µm.

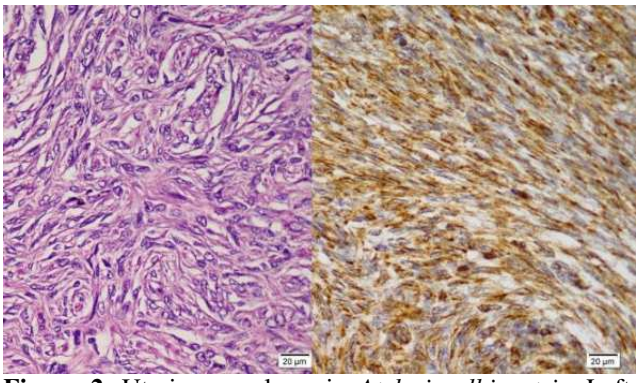


**Figure 2.** Uterine neoplasm in *Atelerix albiventris*. Left: spindle cells arranged in a storiform pattern. The cells displayed scant eosinophilic cytoplasm, sometimes finely fibrillary, and spindle nuclei with granular chromatin. Hematoxylin and eosin, Bar = 20 µm. Right: Immunohistochemistry with vimentin shows strong and diffuse positivity. Bar = 20 µm.

Immunohistochemical reactions are described in Table 1. In mammary tumor there was strong cytoplasmic positivity in all neoplastic cells with AE1/AE3, and moderate nuclear positivity with estrogen and progesterone receptor, staining 20% and 50% of neoplastic cells, respectively (Fig. 3). No immunoreactivity was achieved with cerb-B2 or GCDFP15. In uterine tumor there was strong cytoplasmic positivity with vimentin in all neoplastic cells. AE1/AE3, desmin, 1A4, CD10, estrogen receptor and progesterone receptor were all negative.

Based on histological and immunohistochemical findings, the final diagnoses were solid mammary carcinoma and uterine fibrosarcoma.

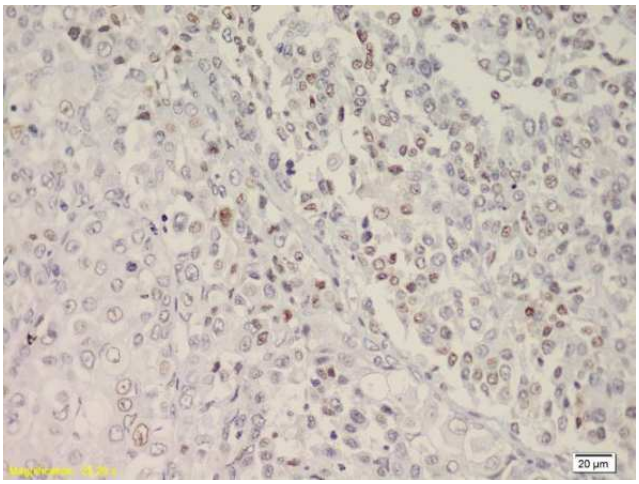


**Figure 3.** Mammary neoplasm in *Atelerix albiventris*. Immunohistochemistry with anti-progesterone receptor antibodies shows a moderate staining in the nuclei of neoplastic cells. Bar = 20 µm.

DOI: 10.24070/bjvp.1983-0246.v10i1p38-42

**Table 1.** Antibodies, sources, dilutions and immunostaining results in *Atelerix albiventris* mammary and uterine tumors. All antibodies listed with negative result had internal positive control, while those without positive control were listed as no 'immunoreactivity'.

| Neoplasm | Antibody (clone) | Dilution | Results | Signal intensity |
|---|---|---|---|---|
| Uterus | Vimentin (V9; Invitrogen, Life Technologies, GIBCO, Grand Island, NY, USA) | 1:3000 | POSITIVE | Strong, All neoplastic cells |
| | Pancytokeratins (AE1/AE3, Biocare Medical, Concord, CA, USA) | 1:2000 | NEGATIVE | -- |
| | Desmin (D33, Dako, Carpinteria, CA, USA) | 1:1000 | NEGATIVE | -- |
| | Smooth Muscle Actin (1A4, Dako, Carpinteria, CA, USA) | 1:4000 | NEGATIVE | -- |
| | CD10 (56C6, Cell Marque, Rocklin, CA, USA) | 1:200 | NEGATIVE | -- |
| | Estrogen Receptor (SP-1, Cell Marque, Rocklin, CA, USA) | 1:50 | NEGATIVE | -- |
| | Progesterone Receptor (PR2c5, Zymed, South San Francisco, CA, USA) | 1:100 | NEGATIVE | -- |
| Mammary | Pancytokeratins (AE1/AE3) | 1:2000 | POSITIVE | Strong, all neoplastic cells |
| | Estrogen Receptor (SP-1, Cell Marque, Rocklin, CA, USA) | 1:50 | POSITIVE | Moderate, 20% of the cells |
| | Progesterone Receptor (PR2x5 Zymed, South San Francisco, CA, USA) | 1:100 | POSITIVE | Moderate, 50% of the cells |
| | Anti-c erb B2 (Dako, Carpinteria, CA, USA) | 1:2000 | NEGATIVE | -- |
| | Anti- GCDFP15 (23A3 BRST2 - 23A3, Cell Marquer, Rocklin, CA, USA) | 1:500 | NEGATIVE | -- |

## Discussion

There has been a growing concern in recent decades about the understanding and characterization of spontaneous neoplasms in domestic and wild animals, with an increase in research in comparative oncology, mainly due to the need of development of biological systems for environmental monitoring (4). In African hedgehogs, spontaneous tumors have been frequently reported, and a retrospective necropsy study reported 30% of prevalence of spontaneous neoplasms in this species (13). Mammary neoplasms are one of the most commonly reported, occurring as solitary or multiple nodules, with benign and malignant variants. In a previous case series, mammary tumors in this species have been classified as papillary adenoma or tubular, solid or papillary carcinomas (12).

The samples from the present case consisted of formalin-fixed tissues submitted from referring veterinary. Although necroscopic findings were described, additional information concerning clinical symptoms and circumstances of death was unfortunately not provided, precluding an accurate determination of the cause of death.

The present report shows two neoplasms in the same individual. More than one tumor type is reported to occur in less than 10% of hedgehogs with neoplasia, and include thyroid follicular adenoma and concurrent multicentric skeletal sarcoma, adrenocortical carcinoma and concurrent mandibular osteosarcoma, among others (6). Simultaneous tumors have also been reported in animals with mammary tumors, and include cutaneous mast cell tumor, hemangiosarcoma, oral squamous cell carcinoma, sebaceous carcinoma, uterine leiomyoma, uterine adenocarcinoma and ovarian granulosa cell tumor (8, 12, 18). Whether this association is coincidental, due to the high prevalence of mammary tumor in these species, or has a common oncogenic pathway is not clear.

A strong cross-reactivity between human commercial antibodies and hedgehog antigens has been reported in immunohistochemical studies, making them useful in these species for a more accurate diagnosis of tumors. A panel of antibodies has been applied for characterization of sarcomas in this species, with immunolabeling ranging from strong to moderate for vimentin, smooth muscle actin, laminin and CD10 (11). In European hedgehogs, cross-reactivity to VIIIRa factor,

DOI: 10.24070/bjvp.1983-0246.v10i1p38-42

macrophage antigen, Ki-67, AE1/AE3, 34β12 and CK20 was achieved (3). In this study, despite the negativity of uterine neoplasia for most tested antibodies, strong reactivity was observed in internal controls. Additionally, except for C-erb-B2 and GCDFP15, which failed to react with internal controls, a positive reaction was also obtained in mammary tumor for AE1/AE3 and estrogen and progesterone receptors. These findings corroborate the usefulness of immunohistochemistry with human commercial antibodies for diagnosis of neoplasms in *A. albiventris* in this particular case.

Mammary tumor is the cancer with the highest incidence in the world's human female population and the most common neoplasm in female dogs (7, 15). In both species, tumors are hormonally controlled, with similarity in stimuli caused by ovarian hormones in neoplastic mammary tissues (17). In bitches, benign mammary tumors are positive for progesterone and estrogen receptors, and a decrease in the number of neoplastic cells expressing these receptors is noted in malignant tumors (1, 17). The authors could not find any report on the expression of hormonal receptors in mammary tumors in African hedgehogs. However, there is a report of a case of a hedgehog with mammary neoplasm and concurrent ovarian granulosa cell tumor, treated with tamoxifen and surgery, without recurrence (18). According to the findings of the present case report, the expression of hormonal receptors in the neoplastic mammary tissue of *Atelerix albiventris* may suggest a relationship between hormone levels and neoplasia. In the present case, mammary tumor showed positivity for estrogen and progesterone receptors at levels comparable to what is expected in benign tumors in bitches, but the morphologic features were consistent with a high grade malignant tumor. Although this finding might indicate that the negative correlation between hormone receptor expression and malignancy does not happen in African hedgehogs, it is not advisable to draw any precise conclusion based on a single case report. It is also possible that this correlation does exist, but with different proportions of cell expression, as compared to what happens in bitches. In humans, a recent guideline recommended that estrogen and progesterone receptors assays in mammary neoplasia should be considered positive when at least 1% of neoplastic cells show nuclear immunostaining, and these cases may benefit from endocrine therapy (5). In African hedgehogs, additional studies with representative case series are needed to better understand the correlation between hormone receptors expression, malignancy, histological types and survival in mammary tumors.

Spontaneous uterine tumors have been reported in African hedgehogs, and include endometrial stromal sarcomas, endometrial polyps, adenossarcomas, adenoleiomiossarcoma, adenoleiomioma, leiomyosarcomas and adenocarcinomas (2, 9, 13). These reports were based on morphological features alone, and immunohistochemical analysis was not described. In the present case, the final diagnosis of uterine fibrosarcoma was one of exclusion. The histopathological features alone did not allow a specific histogenic diagnosis, and only a provisional diagnosis of spindle cell sarcoma was possible. Immunohistochemistry was proceeded in order to obtain a more specific histogenic diagnosis. Leiomyosarcoma was ruled out due to lack of expression of desmin and smooth-muscle actin, antigens associated with muscle differentiation. CD10 expression may be noted in tumors with peripheral nerve differentiation, but was negative in the present case, making the diagnosis of malignant peripheral nerve sheath tumor less likely. Unfortunately, additional antibodies associated with neural differentiation, such as neuron-specific enolase and laminin, could not be done. Due to lack of antigens associated with muscle or neural differentiation, strong expression of vimentin and lack of expression of pancytokeratin (ruling out spindle cell carcinoma), a final diagnosis of uterine fibrosarcoma was offered. Several antibodies, like smooth muscle anti-actin, anti-CD10, among others, have already been employed for diagnosis of sarcomas in African hedgehogs (11). In women, uterine stromal sarcomas, leiomyosarcomas and fibroids are characterized by the expression of hormonal receptors with impact on clinical behavior and response to systemic therapies (16). In this case, no hormone expression was observed in the cells of the uterine sarcoma, making the importance of hormonal influence in this tumor less likely.

In conclusion, we report a case of concurrent mammary solid carcinoma and uterine fibrosarcoma in *A. albiventris*, with evidence of high immunoreactivity with the use of human commercial antibodies in immunohistochemical reactions, and with expression of estrogen and progesterone receptors in neoplastic mammary cells. Additional studies are needed to evaluate the true effectiveness of the use of commercial human antibodies for tumor diagnosis with immunohistochemistry in this species, as well as the importance of estrogen and progesterone receptors expression in mammary neoplasia.

## References

1. Chang CC, Tsai MH, Liao JW, Chan JP, Wong ML, Chang SC. Evaluation of hormone receptor expression for use in predicting survival of female dogs with malignant mammary gland tumors. J Am Vet Med Assoc. 2001;235:391-6.
2. Done LB, Deem SL, Fiorello CV. Surgical and medical management of a uterine spindle cell tumor in an African Hedgehog (*Atelerix albiventris*). J Zoo Wildl Med. 2007;38(4):601-3.
3. Döpke C, Fehr M, Thiele A, Pohlenz J, Wohlsein P. Morphological and immunohistochemical characterization of spontaneous mammary tumours in European hedgehogs (*Erinaceus europaeus*). J Comp Pathol. 2007;137:22-29.

4. Gamlem H, Nordstoga K, Glattre E. Canine neoplasia – An introductory paper. APMIS Suppl. 2008;125:5-18.
5. Hammond ME, Hayes DF, Dowsett M, Allred DC, Hagerty KL, Badve S, Fitzgibbons PL, Francis G, Goldstein NS, Hayes M, Hicks DG, Lester S, Love R, Mangu PB, McShane L, Miller K, Osborne CK, Paik S, Perlmutter J, Rhodes A, Sasano H, Schwartz JN, Sweep FC, Taube S, Torlakovic EE, Valenstein P, Viale G, Visscher D, Wheeler T, Williams RB, Wittliff JL, Wolff AC; American Society of Clinical Oncology; College of American Pathologists. American Society of Clinical Oncology/College of American Pathologists guideline recommendations for immunohistochemical testing of estrogen and progesterone receptors in breast cancer (unabridged version). Arch Pathol Lab Med. 2010;134(7):e48–72.
6. Heatley JJ, Mauldin GE, Chi DY. A review of neoplasia in the captive african hedgehog (*Atelerix albiventris*). Sem Avian Exot Pet Med. 2005;14(3):182-92.
7. Jemal A, Bray F, Center MM, Ferlay J, Ward E, Forman D. Global cancer statistics. CA Cancer J Clin. 2011;61(2):69-90.
8. Matute AR, Bernal AM, Lezama JR, Guadalupe MP, Antonio GA. Sebaceous gland carcinoma and mammary gland carcinoma in an African hedgehog (*Ateletrix albiventris*). J Zoo Wildl Med. 2014;45(3):682-5.
9. Mikaelian I, Reavill DR, Practice A. Spontaneous proliferative lesions and tumors of the uterus of captive African Hedgehogs (*Atelerix albiventris*). J Zoo Wildl Med. 2004;35(2):216-20.
10. Nakata M, Miwa Y, Itou T, Uchida K, Nakayama H, Sakai T. Astrocytoma in an african hedgehog (*Atelerix albiventris*) suspected wobbly hedgehog syndrome. J Vet Med Sci. 2011;73(10):1333-5.
11. Ramos-Vara JA. Soft tissue sarcomas in the African hedgehog (*Atelerix albiventris*): microscopic and immunohistologic study of three cases. J Vet Diagn Invest. 2001;13:442-5.
12. Raymond JT, Garner M. Mammary gland tumors in captive african hedgehogs. J Wildl Dis. 2000;36(2):405-8.
13. Raymond JT, Garner MM. Spontaneous tumours in captive African hedgehogs (*Atelerix albiventris*): a retrospective study. J Comp Pathol. 2001;124:128-33.
14. Santos FB, Branco AMC, Monteiro BF, Souza PMC, Perinelli AF, Xavier JG. Tumor maligno de bainha de nervo periférico recorrente em ouriço pigmeu africano (*Atelerix albiventris*). Arch Vet Sci. 2013;18(3):506-508.
15. Sleeckx N, Rooster H, Kroeze EJBV, Van Ginneken C, Van Brantegem L. Canine Mammary Tumors, an overview. Reprod Domest Anim. 2011;46(6):1112-31.
16. Thanapoulou E, Judson I. Hormonal therapy in gynecological sarcomas. Expert Rev Anticancer Ther. 2012;12(7):885-94.
17. Thuroczy J, Reisvaag GJ, Perge E, Tibold A, Szilagyi J, Balogh L. Immuno-histochemical detection of progesterone and cellular proliferation in canine mammary tumours. J Comp Pathol. 2007;137(2-3):122-9.
18. Wellehan JFX, Southorn E, Smith DA, Taylor WM. Surgical removal of a mammary adenocarcinoma and a granulosa cell tumor in an African hedgehog. Can Vet J. 2003;44:235-7.