



Original Full Paper

# Clinical, pathological and parasitological aspects of ascaridiasis in Blue-fronted parrots (*Amazona aestiva*) from illegal wildlife trade in Northeastern Brazil

Raul A. S. Siqueira<sup>1\*</sup>, Temístocles S. O. Neto<sup>1</sup>, Ricardo R. Guerra<sup>1</sup>, Vinícius L. R. Vilela<sup>2</sup>,  
Ricardo B. Lucena<sup>1</sup>

<sup>1</sup>\*Centro de Ciências Agrárias, Universidade Federal da Paraíba, Campus Areia, Areia, PB, Brazil.

<sup>2</sup>Instituto Federal da Paraíba, Campus Sousa, Sousa, PB, Brazil.

\*Corresponding Author: Centro de Ciências Agrárias, Universidade Federal da Paraíba, Campus Areia, Areia, PB, Brazil.  
E-mail: siqueiraras@gmail.com

Submitted October 31<sup>st</sup> 2017, Accepted March 18<sup>th</sup> 2017

## Abstract

Wild birds from illegal wildlife trade are susceptible to several injuries due to the unfavorable sanitary conditions in which they are maintained. Among these animals, parrots of the *Amazona* genus are frequent victims, and are hosts to parasites of the *Ascaridia* genus. This study aimed to describe clinical, pathological and parasitological aspects of ascaridiasis in Blue-fronted parrots apprehended from illegal wildlife trade in Paraíba State, Brazil. Sixteen *Amazona aestiva* dead at triage after progressive weight loss were submitted to necropsy. Moderate to intense ascaridiasis was observed in 36.4% of the parrots, and associated with poor and cachectic body conditions. Simultaneous diseases were also observed. The parasites were bleached and observed in stereomicroscopy. Based on morphologic aspects, the parasites were identified as *Ascaridia hermaphrodita*.

**Key words:** birds, Psittaciformes, parasitism, illegal wildlife trade.

## Introduction

Birds from the Psittacidae family, especially *Amazona aestiva*, are major targets of illegal wildlife trade due to their colors, shapes, ability to sing, wide distribution and ease of capture (13). These birds may be exposed to several diseases, including ones caused by parasites, due to inadequate sanitary and maintenance conditions during illegal trade (10) and at the triage centers. Parasitological infestations by *Ascaridia* sp. are frequent in birds, especially in those that have access to soil. Among the seven species described in this genus, five species are known in psittacines and *Ascaridia hermaphrodita* was described in 22 species of psittacines, its most common definitive hosts (9).

The location of the main lesions is the gastrointestinal tract, in which even light infestations can

impair absorption and cause diarrhea, while severe infestations may generate ulcers, intussusception, and intestinal occlusion (6, 11). In spite of some studies reporting the occurrence of *Ascaridia* sp. in psittacines, only a few of these studies describe the association between the presence of this parasite and clinical-pathological aspects, and the occurrence of concomitant diseases. Therefore, this study aimed to describe clinical, pathological and parasitological aspects of the infestation by *A. hermaphrodita* in Blue-fronted parrots from illegal wildlife trade in a local wildlife rehabilitation center in the state of Paraíba, Brazil.

## Material and methods

Between 2011 and 2013, twenty two adult Blue-fronted parrots (*A. aestiva*) (sixteen males and six females)

were seized from illegal wildlife trade. After arriving at a local wildlife rehabilitation center (Centro de Triagem de Animais Silvestres – CETAS), these animals died without clinical signs, with no apparent cause, and their ages were unknown. In 2014, they were submitted to necropsy in the Department of Veterinary Sciences at the Centro de Ciências Agrárias, Universidade Federal da Paraíba. The diagnostic procedure in collaboration with CETAS occurred through SISBIO protocol number 02019.00129-12/2009-12.

The carcasses were maintained at 8°C. Body condition was assessed based on the pectoral muscles, subcutaneous adipose tissue and keel exposure (12). During necropsy, samples from the liver, kidneys, lungs, heart, intestines, spleen, esophagus, trachea, proventriculus, gizzard, air sac, skin, and brain were collected, fixated in 10% formalin and routinely processed with hematoxylin-eosin (HE) staining. Adult parasites found in the gastrointestinal tract (proventriculus and small intestine) were collected, pre-fixed in 10% formaldehyde, and maintained in alcohol-formalin-acetic acid (AFA) solution at 65°C for a short time until the counting was performed in a stereomicroscope (1). Then, the parasites were preserved in 70% alcohol and cleared with lactophenol (8). Different larval stages were classified in histopathology, considering the coelomic muscles, lateral chords and the morphology of structures such as intestines and esophagus (4). The definition of other diseases was based on anatomical, pathological, and histopathological findings post necropsy.

## Results and discussion

A severe parasitic infestation in the small intestines, in the initial portions (duodenum) and middle portions (jejunum), based on the ascarid estimative, was observed in eight (36.4%) out of twenty-two Blue-fronted parrots by a single species of nematode identified as *A. hermaphrodita* (Fig. 1). This parasite was identified through phenotypic description, by using stereomicroscopy, in which the morphological characteristics in the reproductive tract (i.e. pre-cloacal sucker) were described (Fig. 1). Ideally, a diagnosis of helminthiasis should be restricted to cases in which three criteria are met: (1) helminths are present in quantities compatible with the disease; (2) typical lesions caused by the parasite are present and (3) clinical signs are compatible with the pathological genetic mechanisms known to be associated with the parasite (3). The diagnosis of ascariasis in this study was based on the clinical signs and the pathological aspects, in addition to the

identification of the adult parasites (9). The relationship between the degree of parasitic infestation, body condition, and occurrence of concomitant diseases are detailed in Table 1.

Blue-fronted parrots are frequently reported as hosts of *A. hermaphrodita* (5, 9). In 36.4% of the necropsied Blue fronted parrots that presented ascariasis, low weight or cachexia was observed, in addition to the occurrence of secondary diseases due to the debility presented by the birds. In Chile, from 2003 to 2008, the presence of *Ascaridia platyceri* was observed in the intestines of different species of psittacine submitted to necropsy, associated with severe weight loss and congestion of the intestinal sites of parasitism (7). The association of parasite infestation to cachexia in this study was considerably more frequent than in other studies. This may be explained by the fact that these birds were seized from illegal wildlife trade, in which they were stressed, maintained inadequately, with no sanitary control, exposed to captive environments, and with inadequate feeding.

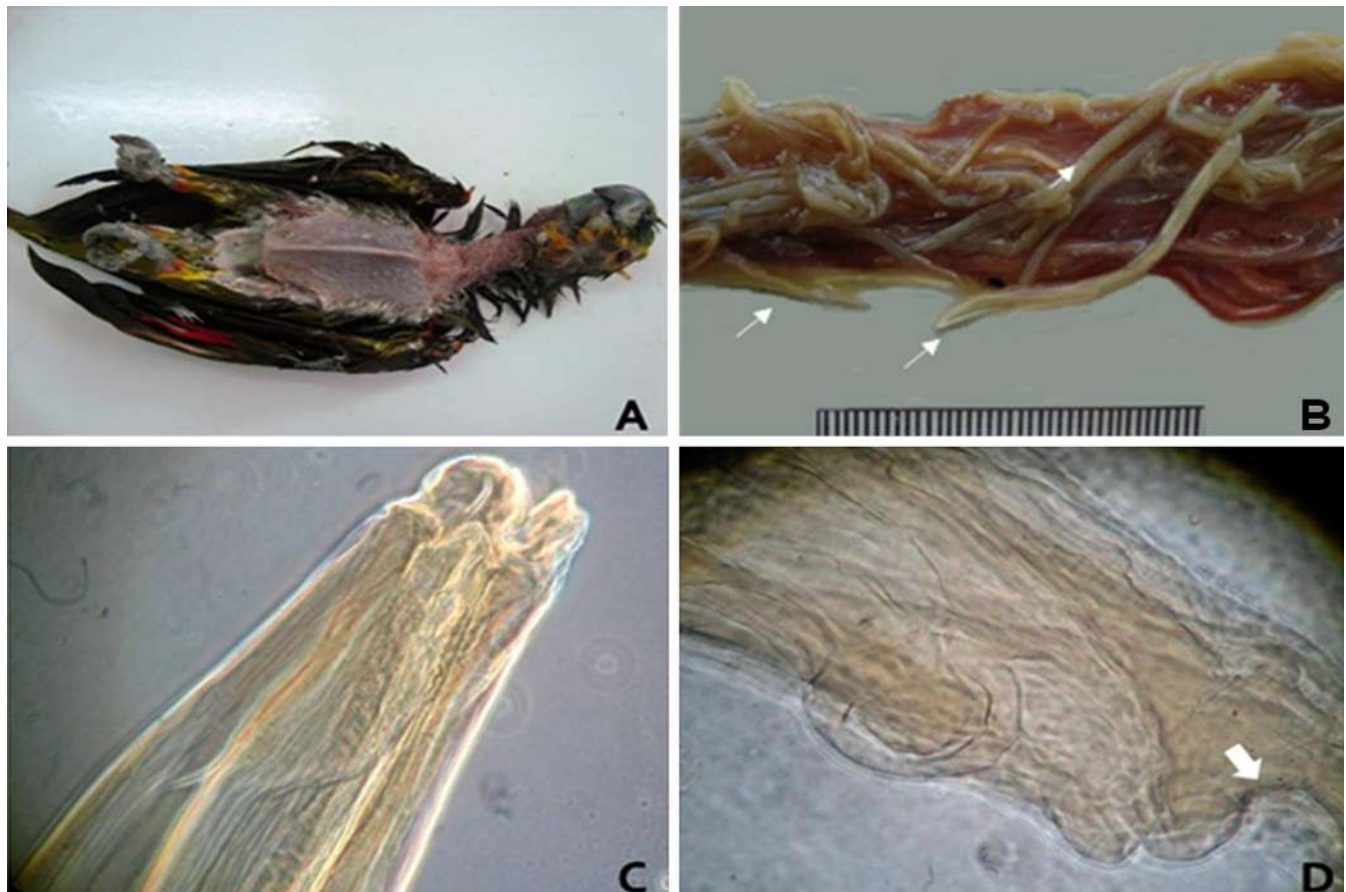
The histopathological evaluation of the small intestine revealed light to moderate enteritis with lymphocytes and plasma cells, which was always more severe in cases that showed the intestinal lumen partially obstructed by worms. Other lesions were mostly caused by opportunistic agents such as: bacterial pneumonia (five parrots), fungal gastritis (two parrots), and periportal fibrosis and presence of larvae in the bile canalicular lumen (one parrot) (Table 1). In Italy, the occurrence of *A. columbae* and *A. platyceri* was reported in captive psittacine presenting severe enteritis and intestinal obstruction, followed by considerable weight loss, ascites, adhesions in the liver and gizzard, perihepatitis, fibrosis and multifocal liver necrosis (2).

## Conclusion

Blue-fronted parrots rescued from the illegal wildlife trade in the state of Paraíba, Brazil, had severe parasitism by *A. hermaphrodita*. Local rescued and rehabilitating psittacines may be predisposed to infestation by *A. hermaphrodita*, which may result either due to conditions of stress or to elevated density in captivity. The infested birds had poor body conditions, often with concomitant diseases and the elevated parasitism was considered a participating cause of cachexia. In addition, the conjoint use of parasitological and pathological diagnostic techniques contributed to the elucidation of these cases.

**Table 1.** Clinical and pathological aspects of ascariasis in Blue-fronted parrots seized from illegal wildlife trade in Paraiba, Brazil, from 2011 to 2013.

Parrot	Infestation degree	Body condition	Concomitant disease
1	Intense	Poor	Fungal gastritis
2	Moderate	Poor	Bacterial pneumonia
3	Moderate	Poor	Bacterial pneumonia
4	Intense	Cachectic	Bacterial pneumonia
5	Intense	Cachectic	Bacterial pneumonia
6	Intense	Cachectic	Bacterial Pneumonia
7	Moderate	Poor	Fungal gastritis
8	Moderate	Poor	Parasite migration in liver



**Figure 1.** Ascaridiasis in Blue-fronted parrots (*Amazona aestiva*). **A.** Parrot 8. Weight loss characterized by keel exposure. **B.** Parrot 1. Intestinal lumen. Elevated quantity of cylindrical worms obliterating the intestinal lumen. **C.** *Ascaridia hermaphrodita*. Stereoscopic photography demonstrating the head of the parasite. **D.** *Ascaridia hermaphrodita*. Stereoscopic photography demonstrating the end of a male parasite with a pre-cloacal sucker (arrow).

## References

1. Amato JFR, Böeger WA, Amato SB. Protocolos para laboratório: coleta e processamento de parasitos de pescado. Seropédica: Gráfica da Universidade Federal Rural do Rio de Janeiro;1991. 81p.
2. Bernadi B, Fichi G, Finotello R, Perucci S. Internal and external parasitic infections in captive psittacine birds. Vet Rec. 2014;174(3):69.
3. Brown CC, Baker DC, Barker IK. Alimentary system. In: Maxie MG, editor. Jubb, Kennedy, and Palmer's Pathology of domestic animals. Philadelphia: Elsevier; 2007. p.1-296.
4. Gardiner CH, Poynton SL. An atlas of metazoan parasites in animal tissues. American Registry of Pathology. Washington: Armed Forces Institute of Pathology; 1999. p. 19-21.
5. Gómez-Puerta LA, López-Urbina MT, González AE. Ocorrência de *Ascaridia hermaphrodita* (Nematode: *Ascaridiidae*) em el loro de Cabeza Azul (*Pionus menstruus*) em Perú. Rev Peru Biol. 2009;15(2):133-5.
6. González-Acuña D, Fabry M, Nascimento AA, Tebaldi JH. Death of two slender-billed parakeet (King) (*Enicognathus leptorhynchus*) (Aves, Psittacidae) by *Ascaridia hermaphrodita* (Froelich, 1789, Railliet & Henry, 1914) at the National Zoo of Santiago, Chile. Arq Bras Med Vet Zootec. 2007;59(2):539-40.
7. González-Hein G, Fredes F, Kinsella M, Larenas J, González-Acuña D. New reports of helminthes in captive exotic psittacine birds in Chile. Arch Med Vet. 2012;44:87-91.
8. Humanson HL. Animal Tissue Techniques. San Francisco: W.H. Freeman and Co.; 1972. 641 p.
9. Kajerova V, Barus V, Literak I. Nematodes from the genus *Ascaridia* parasitizing psittaciform birds: a review and determination key. Vet Med. 2004;49(6): 217-23.
10. Melo CMF, Oliveira JB, Feitosa TF, Vilela VLR, Athayde ACR, Dantas AFM, Wagner PGC, Febrônio AB. Parasites of *Psittaciformes* and *Accipitriformes* in Paraíba state, northeastern Brazil. Rev Bras Parasitol Vet. 2013;22(2):314-7.
11. Ritchie BW, Harrison GJ, Harrison LR. Avian Medicine: Principles and applications. Florida: Wingers Publishing; 1994. 1394 p.
12. Sanches TC. Causas de morte em passeriformes: comparação entre aves de vida livre residentes na Região Metropolitana de São Paulo e aves oriundas do tráfico. Dissertação [Mestrado em Patologia Experimental e Comparada] – Universidade de São Paulo; 2008.
13. Souza TO, Vilela DAR. Espécies ameaçadas de extinção vítimas do tráfico e criação ilegal de animais silvestres. Atualidades Ornitológicas On-line. 2013;176:64-8.