Braz J Vet Pathol, 2017, 10(2), 69 – 78.
DOI: 10.24070/bjvp.1983-0246.v10i2p69-78

BJVP
Brazilian Journal of Veterinary Pathology
ISSN 1983-0246

Original Full Paper

Morphometric and histopathological findings in the adrenal glands of dogs with chronic diseases

Fernanda A. Salvagni*, Adriana de Siqueira, Anna Carolina B. E. Maria, Paulo C. Maiorka

Department of Pathology, Faculdade de Medicina Veterinária e Zootecnia da Universidade de São Paulo, Brazil.
***Corresponding author**: Departamento de Patologia, Faculdade de Medicina Veterinária e Zootecnia, Universidade de São Paulo. Avenida Professor Doutor Orlando Marques de Paiva, 87, Cidade Universitaria, São Paulo, Brazil. Zip code: 05508270. Phone: +55 11 3091-7685 / Fax: +55 11 3091-7829. E-mail: salvagni.fa@gmail.com

Submitted January 30th 2017, Accepted May 21st 2017

Abstract

Prolonged stress suffered by the organism in the presence of chronic diseases can result in functional and morphological changes to the adrenal glands; although the effects of chronic stress on the adrenal gland function in live dogs is well documented, studies focusing on the morphologic changes in the adrenal glands have been lacking. Thus, this study aimed to identify and connect possible morphometric and histopathological changes in the adrenal glands of necropsied dogs in the presence or absence of chronic diseases. Morphological changes in the adrenal glands of 46 necropsied dogs were evaluated through morphometric and histopathological analyses. The morphometric characteristics of the adrenal glands of dogs were influenced more by the animal's body weight ($p < 0.0001$) and adrenocortical hyperplasia ($p < 0.05$) than by the stress associated with chronic diseases or acute conditions. Previously healthy animals with sudden death or animals that died from acute diseases had significant severe congestion in the adrenal glands ($p = 0.0272$), while adrenocortical hyperplasia was more frequent in the chronic diseases group ($p = 0.0041$). Fibrosis at the corticomedullary junction ($p < 0.0001$) and inflammatory infiltrate ($p = 0.0015$) were observed only in animals with chronic diseases. The adrenal glands of dogs with chronic cardiac dysfunction frequently showed significant necrosis ($p = 0.0256$), fibrosis ($p = 0.0002$) and lipid depletion ($p = 0.0288$). Thus, while the weight or dimensions of the adrenal glands of dogs at necropsy should not be used alone as parameters to indicate a relation with the stress suffered prior to death, the histopathological findings could aid and support necropsy conclusions regarding the presence of chronic diseases.

Key words: cardiac dysfunction, fibrosis, necropsy, necrosis, stress.

Introduction

Stress is defined as a reaction of the organism to aggressive agents of various natures, as an attempt to preserve and maintain homeostasis (38). The first in-depth studies on stress were performed by the endocrinologist Hans Selye in 1936 in Canada, who called the stress-causing agents "stressors", which may have physical, chemical, or psychological origins (37).

Two decades later, his study with rats and their body's response to stressors established the "general adaptation syndrome" hypothesis, a nonspecific and stereotyped adaptive response that would include, among other organic changes, variations in morphology and function of the adrenal glands (38).

The adrenal glands are bilateral organs located anterior to the kidneys, covered by a capsule of dense connective tissue and composed of two distinct anatomical regions: the cortex and the medulla (3, 13, 18). The cortex, derived from the mesoderm of the neural crest, is subdivided into the zonas glomerulosa, fasciculata and reticularis. The zona glomerulosa is located in the subcapsular region, formed by columnar or polyhedral cells organized in curved strands or arcs. The zona

 All rights reserved 2007.

fasciculata, the most extensive of the adrenal cortex, is formed by polyhedral cells with abundant and intensely vacuolated cytoplasm, arranged in radial cords surrounded by an extensive web of venous sinuses. The cells of the zona reticularis are very similar to those of the fasciculata; however, they usually present a smaller amount of cytoplasmic lipid vacuoles. The cortical zones are responsible for the production of mineralocorticoids, glucocorticoids and androgens, respectively (3, 18).

The adrenal medulla, on the other hand, is located in the central region of the gland, being derived from the ectoderm of the neural crest and formed mainly by prismatic cells with large vesicular nucleus and basophilic cytoplasm, called chromaffin or pheochromic cells, being responsible for the production of catecholamines noradrenaline and adrenaline (3, 13, 18).

The adrenal glands are intrinsically related to the body's response to stress, being part of the hypothalamic-pituitary-adrenal (HPA) and sympathic-adrenomedullary (SAM) axes (1, 34). Although the three zones of the cortex can be activated by the stimulation of the adrenocroticotrophic hormone (ACTH), the zona fasciculata is the one that presents the greatest response, especially in cases of prolonged stress, resulting in increased production and release of cortisol (1, 32, 34, 46).

There are numerous studies regarding the HPA axis and the response of the organism to a variety of stressors of different natures and for variable periods, such as fasting, sound, cold, heat, immobilization, presence of chronic diseases, among others. These studies, performed in humans or in several animal models, present results involving morphological or functional changes in the adrenal glands in response to the studied stressors (20, 21, 30, 31, 34, 40, 44).

In relation to chronic diseases, there are studies relating long-term diseases such as immune-mediated arthritis, hepatic cholestasis and chronic infections, with a significant reduction in the synthesis and secretion of corticotropin releasing hormone (CRH) through the hypothalamus (19, 41, 42). Reduced levels of CRH may be associated with chronic fatigue, often present in humans afflicted with chronic diseases (40). Chronic diseases are also not uncommon in companion animals (15, 25, 29), especially chronic cardiac dysfunctions in dogs (45). Dogs now have a higher life expectancy than in previous decades, which reflects the higher occurrence of chronic diseases in these animals, such as cardiac dysfunctions and chronic renal failure, among others (23, 25).

Thus, although there are several studies concerning the effects of chronic stress on adrenal function in live dogs (6, 7, 14), studies focusing on the morphometric or histopathological alterations of the adrenal glands in dogs submitted to necropsy are absent.

The objective of this study is to analyze and identify possible morphometric and histopathological alterations in the adrenal glands of dogs submitted to routine necropsies and their relation to the prolonged stress suffered by the organism in the presence of chronic diseases.

Material and methods

We sampled 46 dogs submitted to necropsy at the Animal Pathology Service at the Faculdade de Medicina Veterinária e Zootecnia, Universidade de São Paulo (FMVZ-USP) in São Paulo, Brazil. This study was approved by the Ethic Committee for the Use of Animals of FMVZ-USP (protocol number 2350/2011). The dogs, among males and females, presented ages ranging from 1 month to 16 years old, body weight between 680 g and 58 kg and a variety of breeds, including mixed-breeds.

Sixteen of the 46 dogs had suffered from acute stress before death, being previously healthy or affected by acute diseases, while 30 of the dogs died due to complications of chronic diseases. The animals were divided into groups AC and CH, respectively. Only seven of the animals were euthanized, and only in the CH group.

Forty-five right and 43 left adrenal glands were collected for morphometric and histopathological evaluations. Glands with neoplasia or severe autolysis were not included. The adjacent adipose tissue was removed, and the adrenal glands were weighed individually in a 0.001 g precision scale. Each adrenal gland was measured with a caliper rule to determine its length, width and thickness in centimeters. The animals' pituitary glands were macroscopically analyzed for signs of neoplasia.

The adrenal glands were transversally sectioned, fixed in 10% buffered formalin and embedded in paraffin. Sections 5 µm in size were stained with hematoxylin and eosin and with Masson's trichrome for evidence of fibrosis. The slides were evaluated by two of the veterinary pathologists among the authors (FAS and AS) using a Nikon Eclipse Ni-U trinocular optical microscope (Nikon Instruments Inc., Melville, NY, USA) and photomicrographs were obtained with a Nikon DS Ri1-U3 digital camera (Nikon Corp., Tokyo, Japan) and Nikon NIS-F software (Nikon Instruments Inc., Melville, NY, USA).

Comparisons between the masses and dimensions of an animal's right and left adrenal glands were performed with the paired t-test. Non-paired t-test was performed to compare the animals' age and body weight between the AC and CH groups, and also to compare adrenal gland weight and dimensions between sexes and between adrenal glands with or without cortical hyperplasia. The Mann-Whitney test was used to compare length and width of the right adrenal glands between the AC and CH groups, while the remaining comparisons regarding adrenal gland weight and dimensions between the two groups were performed with the non-paired t-test. The correlations of body weight with adrenal gland weight and dimensions were analyzed using Pearson's correlation test. Comparisons between the AC and CH groups' adrenal

histopathological findings and the presence or absence of adrenal cortical hyperplasia, presence or absence of cardiac diseases, the animal's sex and breed were performed using Fisher's exact test. Only values of $p < 0.05$ were considered significant for all of the analyses. The statistical tests were performed with GraphPad Prism software, version 6 (Analytical Software, San Diego, California, USA).

Results

Data regarding sex, age range and breed of the sampled animals are summarized in Table 1, while age and body weight means± standard deviations are represented in Table 2. There was no significant difference regarding sex ($p = 0.2170$) and body weight ($p = 0.0586$) between the AC and CH groups. On the other hand, breed ($p = 0.0084$) and age ($p < 0.0001$) were significantly different between the two groups. Necropsy conclusions of the 46 dogs are described in Table 3.Means and standard deviations of the adrenal glands' weight and dimensions are summarized in Table 4. There were no significant differences between the sexes regarding adrenal weight or dimensions. There were significant differences in adrenal weight ($p = 0.0073$), length ($p = 0.0210$) and thickness ($p = 0.0030$) among the age ranges, with the adrenal glands being lighter and smaller in animals up to 1 year old, compared to the adults (>3 to ≤ 6 years old and >6 to ≤ 9 years old ranges) and geriatric dogs (>9 years old) but not to the dogs in the <1 to ≤ 3 years old range. There were no significant differences between the right and left adrenal dimensions of the same animals, but the left adrenal gland was heavier than the right gland ($p = 0.0158$).

There were significant differences in weight and thickness of the adrenal glands between groups AC and CH. However, considering that the adrenal glands presented significant correlations ($p < 0.0001$) with body weight (adrenal gland weight $r = 0.82$, length $r = 0.78$, width $r = 0.68$, thickness $r = 0.56$), comparisons were also performed on the basis of body weight range: <10 kg and >10 kg.

When the animals were compared in the body weight range <10 kg, the right adrenal glands of group CH presented greater weight in relation to those of group AC ($p = 0.0222$), with the other comparisons not showing significant differences. In the > 10 kg body weight range, the right adrenal glands of group CH presented greater weight (right $p = 0.0166$; left $p = 0.0059$), length of right adrenal gland ($p = 0.0485$) and thickness of left adrenal gland ($p = 0.0488$) in relation to group AC.

Table 1. Distribution of the 46 necropsied dogs regarding sex, age range and breed in groups AC and CH.

Parameters	Group AC (n=16)	Group CH (n=30)	Total (n=46)
Sex			
Male	11 (68.8%)	16 (53.3%)	27 (60.9%)
Female	5 (31.3%)	14 (46.7%)	19 (39.1%)
Age range			
≤ 1 year old	6 (37.5%)	0 (0%)	6 (13%)
> 1 year old and ≤ 3 years old	3 (18.8%)	2 (6.7%)	5 (10.9%)
> 3 years old and ≤ 6 years old	1 (6.25%)	3 (10%)	4 (8.7%)
> 6 years old and ≤ 9 years old	3 (18.8%)	6 (20%)	9 (19.6%)
> 9 years old	3 (18.8%)	19 (63.3%)	22 (47.8%)
Breed*			
Pure-bred	7 (43.8%)	25 (83.3%)	32 (69.6%)
Mixed breed	9 (56.2%)	5 (16.7%)	14 (30.4%)

* Significant difference between the groups ($p < 0.05$).

Table 2. Age and body weight means± standard deviations in groups AC and CH.

	Group AC	Group CH	p value
Age	4.7 ± 4.8	10.4 ± 3.4	< 0.0001*
Body weight	13.1 ± 10.2	22.8 ± 18.5	0.0586

* Significant difference between the groups ($p < 0.05$).

Table 3. Necropsy conclusions of 46 necropsied dogs.

Necropsy conclusion	Number of animals
Group AC	
Anaphylactic shock to rabies vaccine	4 (8.7%)
Acute infectious enterocolitis	3 (6.5%)
Septic shock	2 (4.3%)
Exogenous intoxication (carbamates)	2 (4.3%)
Cranioencephalic trauma	2 (4.3%)
Acute pneumonia	1 (2.2%)
Hypovolemic shock by trauma (bites)	1 (2.2%)
Asphyxia (drowning)	1 (2.2%)
Group CH	
Chronic cardiac dysfunction	19 (41.3%)
Hypovolemic shock due to neoplasia rupture	3 (6.5%)
Widespread methastasis	3 (6.5%)
Chronic pneumonia	2 (4.3%)
Chronic nephropathy	1 (2.2%)
Widespread methastatic calcification (parathyroid adenoma)	1 (2.2%)
Iatrogenic hyperadrenocorticism	1 (2.2%)

Table 4. Weight and dimensions of 45 right adrenal glands and 43 left adrenal glands of 46 necropsied dogs.

	Group AC	Group CH	p value
Right adrenal gland			
Weight (g)	0.83 ± 0.46	1.25 ± 0.75	0.0478*
Lenght (cm)	2.17 ± 0.65	2.50 ± 0.78	0.1281
Width (cm)	1.20 ± 0.33	1.37 ± 0.43	0.2958
Thickness (cm)	0.55 ± 0.16	0.70 ± 0.18	0.0064*
Left adrenal gland			
Weight (g)	0.81 ± 0.46	1.32 ± 0.82	0.0303*
Lenght (cm)	2.18 ± 0.63	2.45 ± 0.79	0.2634
Width (cm)	1.16 ± 0.32	1.25 ± 0.41	0.4272
Thickness (cm)	0.57 ± 0.14	0.68 ± 0.18	0.0359*

* Significant difference between the groups ($p < 0.05$).

Table 5. Weight and dimensions of adrenal glands with or without cortical hyperplasia of 46 necropsied dogs.

Parameter	Without cortical hyperplasia	With cortical hyperplasia	p value
Weight (g)	0.75 ± 0.47	1.14 ± 0.72	< 0.0001*
Length (cm)	2.10 ± 0.65	2.66 ± 0.70	0.0010*
Width (cm)	1.16 ± 0.38	1.36 ± 0.37	0.0283*
Thickness (cm)	0.59 ± 0.15	0.70 ± 0.19	0.0030*

* Significant difference ($p < 0.05$).

Group CH also had a higher occurrence of animals with adrenocortical hyperplasia ($p = 0.0041$), and adrenal glands showed significant differences in their weight and dimensions between the glands with or without cortical hyperplasia, as shown in Table 5.

The histopathological findings in the adrenal glands are summarized in Table 6. There were no significant differences between the findings in the right and left adrenal glands of the same animals.

Necrosis was coagulative and was mainly observed in the reticularis zone (Fig. 1A). Necrotic cells were frequently replaced by connective tissue, as evidenced by Masson's trichrome staining (Fig. 1B), and were sometimes accompanied by macrophage infiltrate.

 All rights reserved 2007.

Occasionally, the fibrosis formed large patches of connective tissue, almost fully separating the adrenal cortex from the medulla (Fig. 1C, 1D). This finding was more frequent in dogs with chronic cardiac dysfunction ($p = 0.0002$) and was very different from the region's normal fibrovascular stroma (Fig. 1E, 1F). Animals with chronic cardiac dysfunction also showed adrenal necrosis more often ($p = 0.0256$). Only two animals in group AC had adrenal necrosis, but no animal in this group had adrenal fibrosis.

Congestion was present in varying degrees of severity in the reticularis zone and medulla of most of the adrenal glands and was absent only in animals that died of hypovolemic shock.

Hemorrhage was observed in both groups with no significant difference, and occasionally accompanied by siderophages. Hyperplastic cortical nodules were the main sites that showed hemorrhage.

Adrenocortical hyperplasia was usually bilateral and consisted of single or multiple nodules of varying sizes, involving mainly the fasciculata and reticularis zones.

Lipid depletion is characterized by zona fasciculata cells with compact, eosinophilic cytoplasm due to the absence of lipid-rich vacuoles (Figures 2A, 2B). Although there was no significant difference in the occurrence of this finding between the AC and CH groups, it was more frequent in animals with chronic cardiac dysfunction ($p = 0.0288$).

Infiltrates of inflammatory or hematopoietic precursor cells were not observed in the adrenal glands of group AC animals, although the difference was significant only regarding inflammatory infiltrate ($p = 0.0444$).

There was no significant difference in the morphometric and histopathological comparisons between previously healthy animals and those who died from acute diseases.

Discussion

This study describes the morphometric and histopathological findings of the adrenal glands of dogs submitted to routine necropsy with the presence or absence of chronic diseases.

Regarding the characteristics of the sampled animals, there was no significant difference between groups AC and CH in relation to sex and body weight; however, in relation to the definition of race, group AC had a higher occurrence of mixed-breed animals when compared to group CH.

Among the animals in group AC, there were dogs that died due to exogenous poisoning or trauma, and there are studies that indicate a higher risk of occurrence of non-accidental injuries in crossbred dogs and cats (28, 39). In addition, four of the group AC animals died due to anaphylactic reaction to the rabies vaccine, and crossbred dogs are usually more frequent in populations with lower economic status (27, 28), who are the target audience for free or low-cost vaccination campaigns (10).

The mean age of the animals showed a significant difference between groups AC and CH, with dogs being older in group CH (10.4 years) than those in group AC (4.7 years). This finding is consistent with the fact that the animals in group CH had chronic diseases, which are more commonly observed in older animals (15, 45).

In addition, younger animals are commonly more susceptible to acute infections (16, 24) or have a higher risk of suffering non-accidental lesions (28, 39), resulting in the lower mean age of group AC.

The adrenal glands' weight and dimensions in this study were similar to the means described in the literature for the canine species (2, 17). However, unlike Baker's findings in 1937 (2), there was no significant difference between the sexes regarding adrenal weight or dimensions.

Table 6. Histopathological findings in the adrenal glands of 46 necropsied dogs.

Histopathological findings	Group AC	Group CH	p value
Necrosis	2 (12.5%)	12 (40%)	0.0915
Fibrosis	0 (0%)	23 (76.7%)	< 0.0001*
Severe congestion	13 (81.3%)	13 (43.3%)	0.0272*
Hemorrhage	2 (12.2%)	4 (13.3%)	1.0000
Siderophages	1 (6.3%)	6 (20%)	0.3938
Cortical hyperplasia	4 (25%)	22 (73.3%)	0.0041*
Cortical vacuolar depletion	4 (25%)	14 (46.7%)	0.2099
Inflammatory infiltrate	0 (0%)	13 (43.3%)	0.0015*
Hematopoietic precursors	0 (0%)	4 (13.3%)	0.2820

* Significant difference between the groups ($p < 0.05$).

Braz J Vet Pathol, 2017, 10(2), 69 – 78.
DOI: 10.24070/bjvp.1983-0246.v10i2p69-78

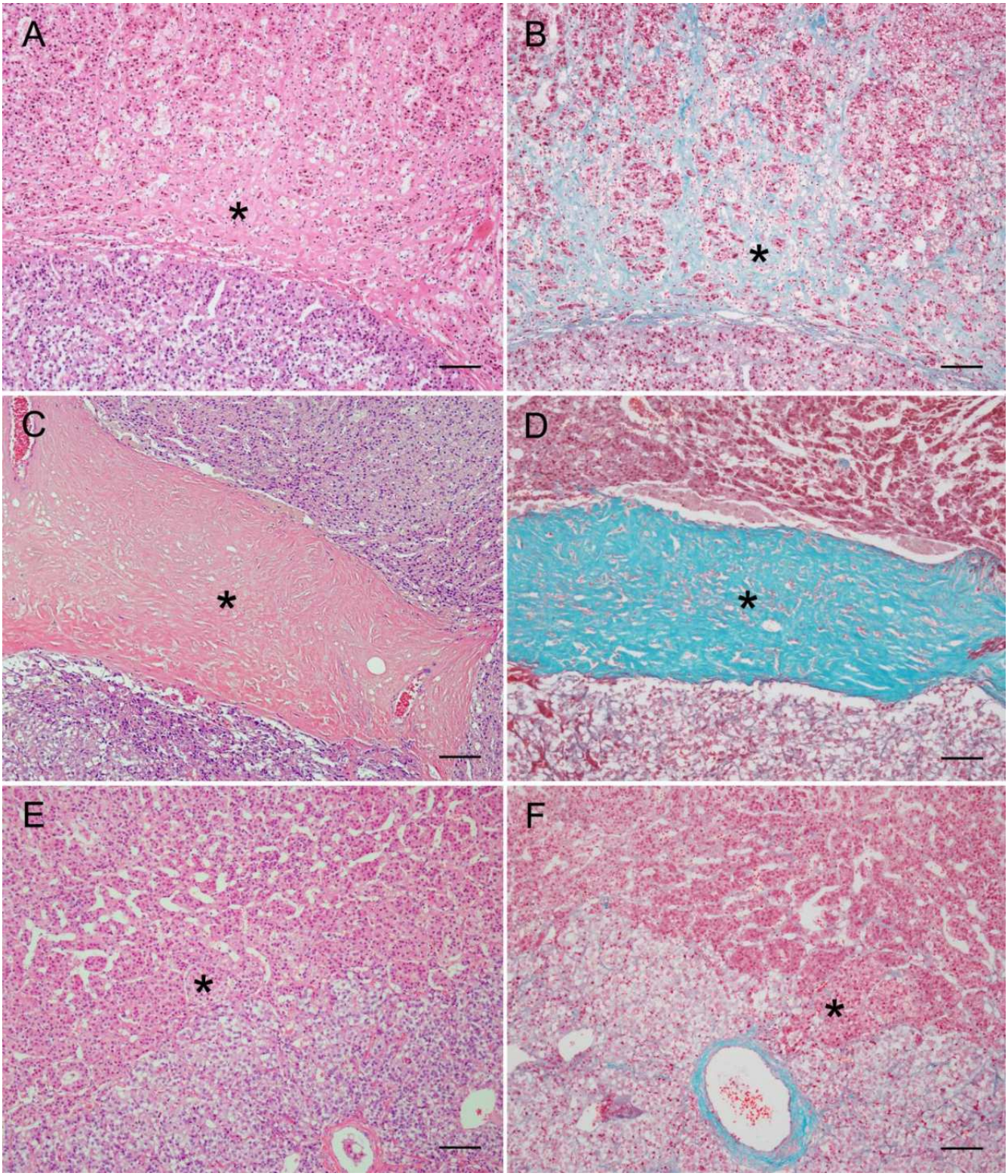

Figure 1. Adrenal glands, dog. **A, B:** Coagulation necrosis in the reticularis zone, with necrotic cells replaced by collagen fibers (asterisks). A-Hematoxylin and eosin (HE), B-Masson's trichrome (MT). **C, D:** Exuberant fibrosis at the corticomedullary junction (asterisks) with almost full separation of the medulla from the reticularis zone in a dog with chronic cardiac dysfunction. C-HE, D-MT. **E, F:** Normal adrenal gland in a previously healthy dog with sudden unexpected death (cranioencephalic trauma). The delicate normal fibrovascular stroma of the corticomedullary junction (asterisks) is barely evidenced by Masson's trichrome. E-HE, F-MT. Bar = 100 µm.

 All rights reserved 2007.

Braz J Vet Pathol, 2017, 10(2), 69 – 78.
DOI: 10.24070/bjvp.1983-0246.v10i2p69-78

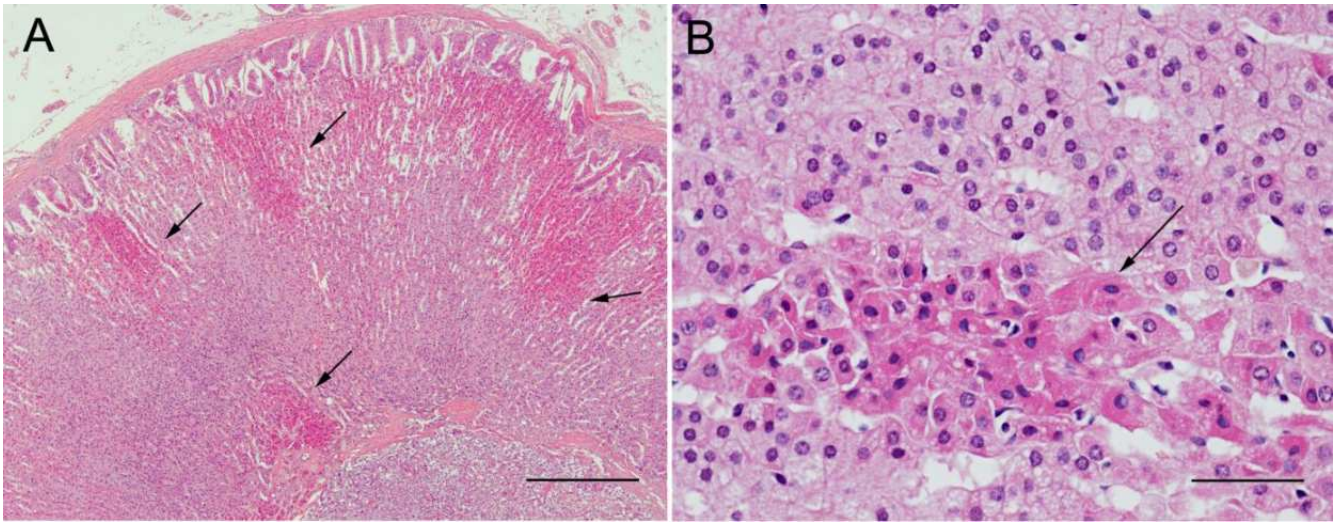

Figure 2. Adrenal glands, dog. **A:** Multiple lipid-depleted areas (arrows) in the fasciculata and reticularis zones. Hematoxylin and eosin (HE). **B:** The lipid-depleted cells show compact, eosinophilic cytoplasm due to the absence of the lipid-rich vacuoles observed in the adjacent normal cortical cells. HE. Bar (A) = 500 µm. Bar (B) = 50 µm.

As shown in Table 5, there was a significant difference between groups AC and CH in relation to adrenal weight and thickness. However, although statistically not significant ($p = 0.0586$), the animals in group CH had a higher mean body weight (22.8 kg) than group AC (13.1 kg).

Thus, since there was a correlation between adrenal weight and dimensions and the body weight of the animals, these findings may not necessarily be related to the presence or absence of chronic diseases. Although there was a significant difference between the AC and CH groups in relation to adrenal weight in both weight ranges, and in relation to right gland length and left gland thickness in the range of > 10 kg, group CH also had a higher frequency of adrenocortical hyperplasia. Hyperplastic glands were significantly heavier, longer, wider and thicker than the glands without hyperplasia, similar to the findings of ultrasonographic studies in dogs (9, 17).

Therefore, although there have been studies describing adrenal size changes regarding stress periods in rats (12, 38, 44), it is important to remember that routinely necropsied dogs do not come from a controlled environment and have a variety of ages, breeds and body weights, which heavily influence the adrenal size, as reinforced by this study. As such, care must be exercised when describing adrenal morphometric findings and attempting to correlate them with the stress suffered by the animal before death.

The coagulative necrosis found in the reticularis zone of the adrenal glands was similar to the findings in humans with hypotension (21). Coagulative necrosis in the adrenal glands can be the result of prolonged cellular hypoxia, due to an imbalance between a reduced concentration of oxygen in the blood and high demand for oxygen by the adrenal cells in situations of stress (21).

This hypothesis is compatible with the observed location of coagulative necrosis, since the reticularis zone is the last to receive oxygenated blood due to the typical vascularization and blood flow of the adrenal glands (5, 36). The majority of the animals with adrenal necrosis also had chronic cardiovascular diseases (69%), which can often result in systemic tissue hypoxia (45).

Only two animals in group AC showed adrenal necrosis, one being a case of carbamate poisoning and the other a case of asphyxia by drowning, both of which are also characterized by tissue hypoxia (11, 35).

The coagulative necrosis found in this study differed from the lesions found in adrenal glands exposed to chemical exogenous substances (43), septicemia or high levels of adrenocorticotrophic hormone (33), because the necrosis was at the specific location of the corticomedullary junction and the inflammatory infiltrate was discrete and composed mainly of macrophages without associated hemorrhage.

Necrotic cells were frequently replaced by collagen fibers in the adrenal glands, resulting in fibrosis of the zona reticularis, as also seen in humans with hypotension (21). Studies of thermal stress in rats have also described the induction of fibrosis in the adrenal glands (20), but in a more diffuse pattern, instead of at the specific corticomedullary junction observed in this study. We found no fibrosis in animals in the AC group, reinforcing the hypothesis that this finding is associated with chronic diseases, especially of cardiac origin, since adrenal necrosis and fibrosis were significantly associated with chronic cardiac dysfunction in this study. The increased frequency and severity of adrenal fibrosis in dogs with chronic cardiac abnormalities may be associated

with the prolonged period of congestion and systemic hypoxia caused by these conditions, which may persist for years in the subclinical form (45).

Adrenal congestion was more severe in group AC, which included animals that died of anaphylactic shock or carbamate poisoning, which are frequently characterized by vasodilation in multiple organs (26, 35).

Cortical adrenal hemorrhage can be observed as part of the exhaustion phase in response to stress, in wild animals that die after capture or in horses that die after excessive exercise (8). In this study, we found adrenal hemorrhage only in two dogs that died of trauma, two that were euthanized, one that died of cardiogenic shock and one that died of respiratory decompensation, and these hemorrhages were frequently located in hyperplastic cortical nodules. Endotoxemia and septicemia can also cause adrenocortical hemorrhage (31, 33), although, in this study, hemorrhage or siderophages were not observed in the adrenal glands of animals with sepsis. It is interesting to note that the hemorrhage findings between groups AC and CH showed a value of $p = 1.000$; thus, although adrenal hemorrhage is commonly associated with stress situations in rats, due to the original studies of Hans Selye in 1956 (38), it is not recommended to use this finding in the canine species as a parameter to indicate the stress suffered by the animal before death.

Adrenocortical nodular hyperplasia is frequently observed spontaneously in dogs of advanced age (8) and group CH had a significant higher age mean (7.9 years old). None of the animals had a history or signs of Cushing's disease, except for one Rottweiler with iatrogenic hypercortisolism and atrophy of the adrenal cortex.

There were no associated pituitary tumors in any of the animals, which reinforced the occurrence of adrenocortical hyperplasia due to advanced age. The mean adrenal thickness with cortical hyperplasia in relation to non-hyperplastic adrenal glands corroborates the more recent ultrasound studies which indicate that the normal adrenal thickness limit of 0.75 cm proposed by Barthez et al (4) would be too high, which may omit the diagnosis of dogs with adrenal cortical hyperplasia (9, 17).

Lipid depletion areas in the adrenal cortex are observed in situations of intense stress recovery, indicating high cortisol metabolism (22). In humans, lipid depletion is a frequent finding in septic shock, although in a more diffuse manner (31). In this study, lipid depletion was focal or multifocal, and although there was no significant difference in the occurrence between the groups, this lesion was significantly more frequent in animals with chronic cardiac dysfunction (0.0288).

Inflammatory cells in the adrenal glands are frequently observed as the result of inflammation in other tissues, such as in systemic or retroperitoneal diseases (22), while hematopoietic precursor cells can be spontaneously observed in the adrenal glands, characterizing extramedullary hematopoiesis (36). The absence of inflammatory and hematopoietic precursor cells in group AC was compatible with the fact that those animals were previously healthy or had acute non-systemic and/or non-retroperitonial diseases. Regarding the infiltrate of hematopoietic precursors, this finding was generally associated with extramedullary hematopoiesis seen in other organs, such as the spleen.

In summary, the morphometric characteristics of the adrenal glands were influenced more by the animal's body weight and the presence of adrenocortical hyperplasia than by the stress associated with chronic diseases or the rapidity of death.

It is not recommended, therefore, that the information regarding weight or dimensions of the adrenal glands of dogs at necropsy should be used alone as parameters to indicate the relation with the stress suffered prior to death, due to the remarkable variety of breeds and sizes in this species. Therefore, future studies with each breed, age group and body weight range of dogs would be necessary to detect possible subtle changes in adrenal morphometry. Previously healthy animals or animals with acute diseases had more severe congestion in the adrenal glands, while adrenocortical hyperplasia was more frequent in the chronic diseases group. Fibrosis at the corticomedullary junction and inflammatory infiltrate were observed only in animals with chronic diseases. Animals with chronic cardiac dysfunction were frequently suspected of sudden unexpected death; however, although this cardiac condition can be clinically silent for years, the adrenal glands of these animals frequently showed significant necrosis, fibrosis and lipid depletion. These findings could aid and support necropsy conclusions regarding the presence of chronic diseases, especially in clinically silent or undiagnosed conditions previously unknown to the owner and/or veterinary clinician.

Acknowledgements

This work was supported by the Sao Paulo Research Foundation (FAPESP) process no. 2013/23645-4. The authors would like to thank the Coordination for the Improvement of Higher Education Personnel (CAPES) and the National Council for Scientific and Technological Development (CNPq) for doctoral grants.

References

1. Axelrod J, Reisine TD. Stress hormones: their interaction and regulation. Science, 1984;224(4648): 452-9.
2. Baker DD. Studies of the suprarenal glands of dogs. I. Comparison of the weights of suprarenal glands of mature and immature male and female dogs. Am J Anat. 1937;60(2):231-52.
3. Banks WJ. Sistema endócrino. In: Banks WJ, editor. Histologia veterinária aplicada. 2nd ed. São Paulo: Manole; 1991. p. 521-45.

4. Barthez P, Nyland T, Feldman E. Ultrasonographic evaluation of the adrenal glands in dogs. J Am Vet Med Assoc. 1995;207:1180-3.
5. Bassett JR, West SH. Vascularization of the adrenal cortex: its possible involvement in the regulation of steroid hormone release. Microsc Res Tech. 1997;36(6):546-57.
6. Beerda B, Schilder MBH, Bernadina W, Van Hooff JA, De Vries HW, Mol JA. Chronic stress in dogs subjected to social and spatial restriction. II. Hormonal and immunological responses. Physiol Behav. 1999;66(2):243-54.
7. Beerda B, Schilder MBH, Van Hooff JA, De Vries HW. Manifestations of chronic and acute stress in dogs. Appl Anim Behav Sci. 1997;52(3-4):307-19.
8. Capen CC. Endocrine glands. In: Maxie MG, editor. Jubb, Kennedy and Palmer's Pathology of domestic animals. 5th ed., vol. 3. Philadelphia: Saunders Elsevier; 2007. p. 325-428.
9. Choi J, Kim H, Yoon J. Ultrasonographic adrenal gland measurements in clinically normal small breed dogs and comparison with pituitary-dependent hyperadrenocorticism. J Vet Med Sci. 2011;73(8):985-9.
10. Davlin SL, Vonville HM. Canine rabies vaccination and domestic dog population characteristics in the developing world: a systematic review. Vaccine 2012;30(24):3492-502.
11. Dimaio VJ, Dimaio D. Forensic pathology. 2nd ed. Boca Raton: CRC Press; 2001. 592 p.
12. Dumm ME, Laken B, Ralli EP. Factors influencing adrenal weight and adrenal cholesterol in rats following stress. J Nutr. 1955;56(4):517-31.
13. Dyce KM, Sack WO, Wensing CJG. Glândulas endócrinas. In: Dyce K, Sacks W, Wensing C, editors. Tratado de anatomia veterinária. 3rd ed. Rio de Janeiro: Elsevier, 2004. p. 208-14.
14. Garnier F, Benoit E, Virat M, Ochoa R, Delatour P. Adrenal cortical response in clinically normal dogs before and after adaptation to a housing environment. Lab Anim. 1990;24(1):40-3.
15. Greene C. Infectious diseases of the dog and cat. 3rd ed. St. Louis: Elsevier, 2006.
16. Greene C, Appel M. Canine Distemper. In: Greene C., editor. Infectious diseases of the dog and cat. 3rd ed. St. Louis: Elsevier, 2006. p. 25-40.
17. Grooters AM, Biller D, Merryman J. Ultrasonographic parameters of normal canine adrenal glands: comparison to necropsy findings. Vet Radiol Ultrasound. 1995;36(2):126-30.
18. Guyton AC, Hall JE. O sistema nervoso autônomo e a medula adrenal. In: Guyton AC, Hall JE, editors. Tratado de fisiologia médica. 11th ed. Rio de Janeiro: Elsevier, 2006. p. 748-70.
19. Harbuz MS, Rees RG, Eckland D, Jessop DS, Brewerton D, Lightman SL. Paradoxical responses of hypothalamic corticotropin-releasing factor (CRF) messenger ribonucleic acid (mRNA) and CRF-41 peptide and adenohypophysial proopiomelanocortin mRNA during chronic inflammatory stress. Endocrinology. 1992;130(3):1394-400.
20. Koko V, Djordjeviae J, Cvijiae G, Davidoviae V. Effect of acute heat stress on rat adrenal glands: a morphological and stereological study. J Exp Biol. 2004;207(24):4225-30.
21. Kuhajda FP, Hutchins GM. Adrenal cortico-medullary junction necrosis: a morphologic marker for hypotension. Am Heart J. 1979;98(3):294-7.
22. Lack EE. Tumors of the adrenal glands and extra-adrenal paraganglia. 1st ed. Annapolis Junction: American Registry of Pathology, 2007.
23. Marcondes M, Correa V. Expectativa de vida de cães e gatos dobrou nos últimos 30 anos [Internet]. São Paulo: Folha de São Paulo; 2014, July 6. Available from: http://www1.folha.uol.com.br/saopaulo/2014/07/1481144-expectativa-de-vida-de-caes-e-gatos-dobrou-nos-ultimos-30-anos.shtml.
24. McCaw D, Hoskins J. Canine viral enteritis. In: Greene C, editor. Infectious diseases of the dog and cat. 3rd ed. St. Louis, MO: Elsevier, 2006. p. 63-73.
25. Michell AR. Longevity of British breeds of dog and its relationships with sex, size, cardiovascular variables and disease. Vet Rec. 1999;145(22):625-9.
26. Moranville MP, Mieure KD, Santayana EM. Evaluation and management of shock states: hypovolemic, distributive, and cardiogenic shock. J Pharm Pract. 2011;24(1):44-60.
27. Munro HM, Thrusfield MV. "Battered pets": features that raise suspicion of non-accidental injury. J Small Anim Pract. 2001;42(5):218-26.
28. Munro HM, Thrusfield MV. "Battered pets": non-accidental physical injuries found in dogs and cats. J Small Anim Pract. 2001;42(6):279-90.
29. Olsen TF, Allen AL. Causes of sudden and unexpected death in dogs: a 10-year retrospective study. Can Vet J. 2000;41(11):873-5.
30. Petrovic-Kosanovic D, Velickovic K, Koko V, Jasnic N, Cvijic G, Miloševic MC. Effect of acute heat stress on rat adrenal cortex - a morphological and ultrastructural study. Cent Eur J Biol. 2012;7(4):611-9.
31. Polito A, Lorin De La Grandmaison G, Mansart A, Louiset E, Lefebvre H, Sharshar T, Annane D. Human and experimental septic shock are characterized by depletion of lipid droplets in the adrenals. Intensive Care Med. 2010;36(11):1852-8.
32. Quan X, Guo K, Wang Y, Huang L, Chen B, Ye Z, Luo Z. Mechanical compression insults induce nanoscale changes of membrane-skeleton arrangement which could cause apoptosis and necrosis in dorsal root ganglion neurons. Biosci Biotechnol Biochem. 2014;78(10):1631-9.
33. Rao RH. Bilateral massive adrenal hemorrhage. Med Clin North Am. 1995;79(1):107-29.

34. Riegle GD. Chronic stress effects on adrenocortical responsiveness in young and aged rats. Neuroendocrinology. 1973;11(1):1-10.
35. Risher JF, Mink FL, Stara JF. The toxicologic effects of the carbamate insecticide aldicarb in mammals: a review. Environ Health Perspect. 1987;72(1):267-81.
36. Rosol TJ, Yarrington JT, Latendresse J, Capen CC. Adrenal gland: structure, function, and mechanisms of toxicity. Toxicol Pathol. 2001;29(1):41-8.
37. Selye H. A syndrome produced by diverse nocuous agents. 1936. J Neuropsychiatry Clin Neurosci. 1998;10:230-1.
38. Selye H. The stress of life. 1st ed. New York: McGraw-Hill Book Company, 1956.
39. De Siqueira A, Cassiano FC, Landi MFDA, Marlet EF, Maiorka PC. Non-accidental injuries found in necropsies of domestic cats: a review of 191 cases. J Feline Med Surg. 2012;14(10):723-8.
40. Swain MG. Fatigue in chronic disease. Clin Sci. 2000;99(1):1-8.
41. Swain MG, Maric M. Defective corticotropin-releasing hormone mediated neuroendocrine and behavioral responses in cholestatic rats: implications for cholestatic liver disease-related sickness behaviors. Hepatology. 1995;22(5):1560-4.
42. Swain MG, Patchev V, Vergalla J, Chrousos G, Jones EA. Suppression of hypothalamic-pituitary-adrenal axis responsiveness to stress in a rat model of acute cholestasis. J Clin Invest. 1993;91(5):1903-8.
43. Szabo S, Lippe IT. Adrenal gland: chemically induced structural and functional changes in the cortex. Toxicol Pathol. 1989;17(2):317-29.
44. Ulrich-Lai YM, Figueiredo HF, Ostrander MM, Choi DC, Engeland WC, Herman JP. Chronic stress induces adrenal hyperplasia and hypertrophy in a subregion-specific manner. Am J Physiol Endocrinol Metab. 2006;291(5):965-73.
45. Ware WA. Cardiovascular disease in small animal medicine. 1st ed. London: Manson Publishing; 2007. 396 p.
46. Whitworth EJ, Kosti O, Renshaw D, Hinson JP. Adrenal neuropeptides: regulation and interaction with ACTH and other adrenal regulators. Microsc Res Tech. 2003;61(3):259-67.