

**Case Report****Bluetongue in white-tailed deer (*Odocoileus virginianus*) in Northeastern Mexico**Julio Martínez-Burnes<sup>1\*</sup>, Hugo Barrios-García<sup>1</sup>, Jorge Alva-Pérez<sup>1</sup>, Rafael Ramírez-Romero<sup>2</sup>, Luis J. García-Márquez<sup>3</sup>, Alfonso López-Mayagoitia<sup>4</sup><sup>1</sup>Facultad de Medicina Veterinaria y Zootecnia, “Dr. Norberto Treviño Zapata” Universidad Autónoma de Tamaulipas, Km. 5 Carretera Victoria-Mante, Ciudad Victoria, Tamaulipas, CP87000, México.<sup>2</sup>Facultad de Medicina Veterinaria y Zootecnia, Universidad Autónoma de Nuevo León, Francisco Villa S/N, Col: Ex Hacienda el Canadá, Escobedo, Nuevo León, CP66050, México.<sup>3</sup>Centro Universitario de Investigación y Desarrollo Agropecuario (CUIDA), Facultad de Medicina Veterinaria y Zootecnia, Universidad de Colima, Carretera Colima-Manzanillo Km 40. Colonia: La Estación, Tecmán, Colima, CP 28100, México.<sup>4</sup>Department of Pathology and Microbiology, Atlantic Veterinary College, University of Prince Edward Island, Charlottetown, Prince Edward Island, C1A 4P3, Canada.\*Corresponding Author: Julio Martínez-Burnes; E-mail: [jmburnes@docentes.uat.edu.mx](mailto:jmburnes@docentes.uat.edu.mx)Submitted July 7<sup>th</sup> 2017, Accepted August 27<sup>th</sup> 2017**Abstract**

Bluetongue (BT) and epizootic hemorrhagic disease of deer (EHD) are two distinct viral hemorrhagic diseases of domestic and wild ruminants caused by members of the family Reoviridae and transmitted by *Culicoides* midges. These conditions have been recognized in Canada and the United States for many years, but not in Mexico. Although in Mexico there is serologic evidence of EHD virus (EHDV) and bluetongue virus (BTV) in domestic and wild ruminants, to our knowledge, there have never been reports of clinical illness or fatalities attributed to either of these viruses. Two free ranging white-tailed deer (*Odocoileus virginianus*) in two licensed hunting ranches in Northern Mexico near the Texas border died unexpectedly. Postmortem and microscopic examinations revealed hemorrhagic lesions compatible with viral hemorrhagic disease (Reoviridae: Orbivirus). Tissues from one animal tested positive by RT-PCR for BTV but negative for EHDV. To our knowledge, this is the first time in Mexico where deer dying with hemorrhagic lesions consistent with Bluetongue tested positive for BTV by PCR.

**Key words:** hemorrhagic disease, white-tailed deer, Orbivirus, Mexico.**Introduction**

Similar to the United States and Canada, wildlife management and conservation in northern Mexico have gained great economic relevance in recent years (14). The white-tailed deer (*Odocoileus virginianus*) is the main species licensed for sport hunting on North American ranches where this free range wild ruminant graze together with cattle, goats, and sheep. Infectious diseases are not only a threat to domestic animals but wildlife conservation and game farming too.

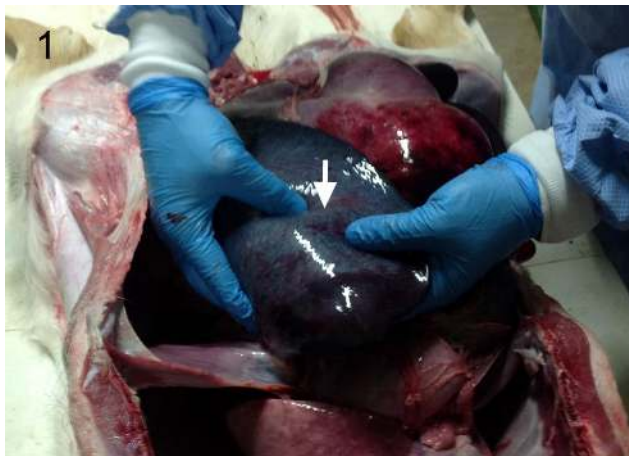
Bluetongue (BT) and epizootic hemorrhagic disease of deer (EHD) are two distinct viral hemorrhagic

diseases of ruminants, caused by members of the family Reoviridae, genus Orbivirus and transmitted by *Culicoides* midges (1, 5). These two hemorrhagic diseases cause significant morbidity and mortality in domestic and wild ruminants in many regions of the world (1, 9) and have been diagnosed in the white-tailed deer populations of Canada and the United States, but not in Mexico (3, 8, 11).

The objective of this report is to document the first case of BT diagnosed in white-tailed deer in Mexico.

## Case report

In December 2012, two free ranging white-tailed deer were found dead on two separate ranches in the State of Nuevo Leon and Tamaulipas, just a few miles south of the Mexico-Texas border. Postmortem examination revealed remarkable hemorrhagic lesions involving the abdominal and thoracic viscera. The spleen in one of the deer was severely enlarged with rounded margins, and on the cut surface, the splenic pulp appeared distinctly congested (Fig. 1). The intestinal serosa appeared diffusely dark (Fig. 2). The intestinal and forestomach serosa from the other deer were severely hemorrhagic (Fig. 3) and on the cut surface, the mucosa was diffusely thickened and hemorrhagic with clotted blood in the intestinal lumen. Also, numerous petechial and ecchymotic hemorrhages were present in the pericardium, endocardium, and myocardium. Samples of the intestine, spleen, and heart were fixed in 10% buffered formalin and submitted for histopathological examination to the Diagnostic Laboratory of the Facultad de Medicina Veterinaria y Zootecnia, Universidad Autónoma de Tamaulipas, México. Fixed tissues processed and embedded in paraffin were cut at 4-5  $\mu$ m and stained with hematoxylin-eosin.

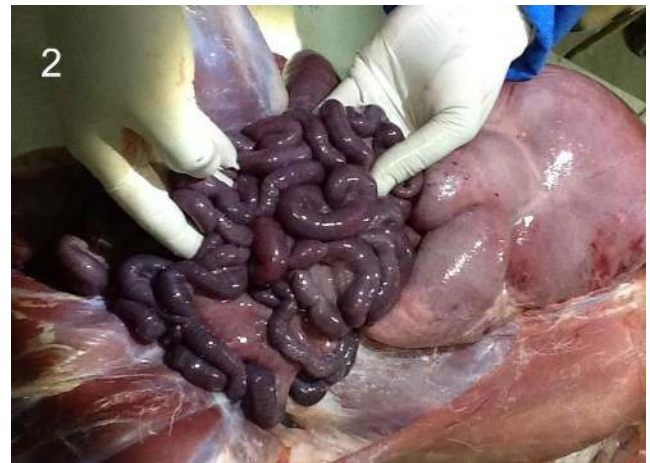

**Figure 1.** Abdominal cavity. Markedly enlarged spleen with rounded borders and petechial hemorrhages on the splenic capsule (arrow).

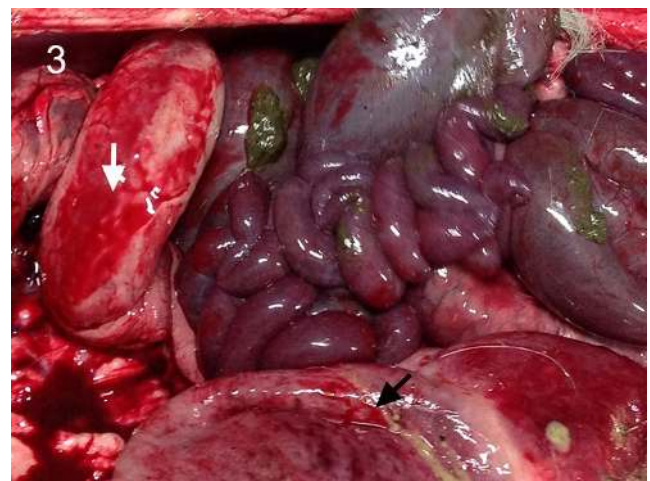Microscopic examination of the intestine revealed severe congestion and extensive transmural hemorrhages. In some sections of the intestine, the lamina propria was virtually effaced with extravasated blood (Fig. 4). Multifocal hemorrhages were evident in the epicardium and subendocardium, and myocardial fibers appeared separated with edema and hemorrhage. Microscopically, there was no evidence of arteritis, vasculitis, thrombosis, inclusion bodies or intralésional pathogens.

Based on the gross and microscopic findings, bluetongue and EHD were suspected. Paraffin-embedded tissues from the deer with more severe hemorrhagic lesions were sent to the Washington Animal Disease Diagnostic

Laboratory (Pullman, WA) for *in situ* detection of BTV and EHDV antigens. After extraction of nucleic acids with Trizol from paraffin-embedded tissues, BTV and EHDV were investigated using a real-time PCR (RT-PCR) assay (15). Test results were positive for BTV and negative for EHDV.



**Figure 2.** Diffuse dark discoloration of the intestinal serosa.

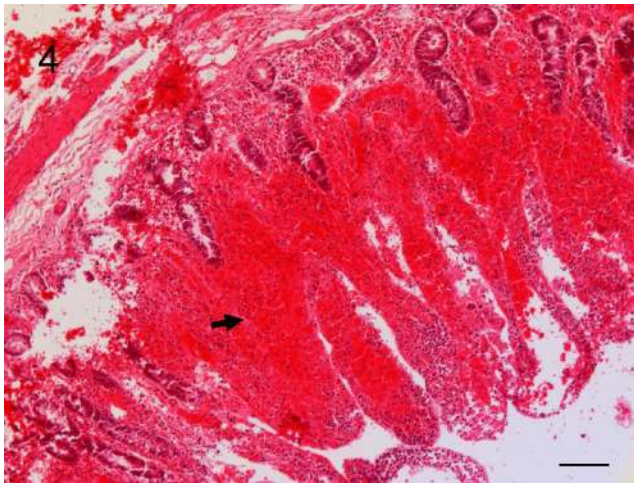


**Figure 3.** Severe serosal hemorrhages on intestine (white arrow) and forestomach (black arrow).

## Discussion

The hemorrhagic lesions in BT and EHD can be mistaken for a variety of other hemorrhagic diseases such as malignant catarrhal fever, adenovirus infection, hemorrhagic septicemia, anthrax, enterotoxemia, coagulopathy and sepsis (7, 13). In North America, BTV and EHDV are found in the same geographical locations and cause sporadic outbreaks in domestic and wild ruminants (13). For most of these hemorrhagic diseases, good clinical work and laboratory tests such as virus isolation, PCR or immunostaining are necessary to reach the correct etiological diagnosis. In the two white-tailed deer reported here, acute death and extensive hemorrhages

in the absence of microscopic evidence of vasculitis, adenoviral inclusions or other intralesional pathogens suggested the possibility of EHD or BT. A RT-PCR assay was required to confirm BTV as the etiology and ruled out EHDV. Gross and microscopic lesions in BT relate to the endothelial changes caused by the virus which eventually leads to edema and hemorrhages in many organs and tissues. Although vascular thrombosis has been reported in BTV infection (13), this lesion was not seen microscopically in affected tissues.



**Figure 4.** Small intestine, histopathology. Diffuse mucosal and submucosal hemorrhage (arrow) and total effacement of the lamina propria with extravasated blood. H&E stain, Bar = 100  $\mu$ m.

The global distribution of the 26 serotypes of the BTV has changed over the last 15 years, possibly as a consequence of climate change and shifts in the *Culicoides* midge populations (6, 9). Although serological studies had suggested that BT virus is prevalent in Mexico, including in the deer population (4, 10, 12), to our knowledge, this is the first time where dead deer showing multisystemic hemorrhages highly suggestive of Bluetongue tested positive for BTV by PCR.

Mexico shares a long border of over 3,200 Km with the United States, and as result of this geographical connection, these two countries also share similar virus-vector ecosystems (2). Therefore, it should not be surprising that BT in deer occurs in both neighboring countries. According to some investigators, BT in cattle relates more to the vector movement than the animal trade; for free-ranging deer, BT possible involves both vector and animal movement across the Mexico-US border (2).

#### Acknowledgements

The authors would like to acknowledge the funding provided by "Programa para el Mejoramiento del Profesorado (PROMEP-SEP) through the "Red de Cuerpos

Académicos sobre estudios de enfermedades de fauna y su papel como reservorios."

#### References

1. Allepuz A, Garcia-Bocanegra I, Napp S, Casal J, Arenas A, Saez M, Gonzalez M. Monitoring bluetongue disease (BTV-1) epidemic in southern Spain during 2007. *Prev Vet Med.* 2010;96(3-4):263-71.
2. DeHaven WR, Del Valle-Molina J, Evans B. Bluetongue viruses and trade issues: a North American perspective. *Vet Ital.* 2004;40(4):683-7.
3. Johnson DJ, Ostlund EN, Stallknecht DE, Goekjian VH, Jenkins-Moore M, Harris SC. First report of bluetongue virus serotype 1 isolated from a white-tailed deer in the United States. *J Vet Diagn Invest.* 2006;18(4):398-401.
4. Martinez A, Salinas A, Martinez F, Cantu A, Miller DK. Serosurvey for selected disease agents in white-tailed deer from Mexico. *J Wildl Dis.* 1999;35(4):799-803.
5. Ruder MG, Stallknecht DE, Allison AB, Mead DG, Carter DL, Howerth EW. Host and potential vector susceptibility to an emerging orbivirus in the United States: Epizootic Hemorrhagic Disease Virus serotype 6. *Vet Pathol.* 2016;53(3):574-84.
6. Ruiz-Fons F, Reyes-Garcia AR, Alcaide V, Gortazar C. Spatial and temporal evolution of bluetongue virus in wild ruminants, Spain. *Emerg Infect Dis.* 2008;14(6):951-3.
7. Schultheiss PC, Van Campen H, Spraker TR, Bishop C, Wolfe L, Podell B. Malignant catarrhal fever associated with ovine herpesvirus-2 in free-ranging mule deer in Colorado. *J Wildl Dis.* 2007;43(3):533-7.
8. Shope RE, Macnamara LG, Mangold R. A virus-induced epizootic hemorrhagic disease of the Virginia white-tailed deer (*Odocoileus virginianus*). *J Exp Med.* 1960;111(2):155-170.
9. Sleeman JM, Howell JE, Knox WM, Stenger PJ. Incidence of hemorrhagic disease in white-tailed deer is associated with winter and summer climatic conditions. *Ecohealth.* 2009;6(1):11-5.
10. Snyderlaar-Hardwicke AC, Lerma-Doria CE. Serologic study of bluetongue in the State of Tamaulipas. *Rev Latinoam Microbiol.* 1987;29(1):5-13.
11. Stallknecht DE, Luttrell MP, Smith KE, Nettles VF. Hemorrhagic disease in white-tailed deer in Texas: A case for enzootic stability. *J Wildl Dis.* 1996;32(4):695-700.
12. Teclaw RF, McConnell S, Wagner GG, Romo S, Garcia Z. Serologic study of the incidence and prevalence of bluetongue infections in cattle in the Mexican States of Nuevo Leon, Tamaulipas, Coahuila and San Luis Potosi. *Prev Vet Med.* 1985;3(5):437-43.
13. Uzal FA, Plattner BL, Hosteter JM. Alimentary system. In: Maxie MG, editor. *Jubb, Kennedy &*

Palmer's Pathology of Domestic Animals. St. Louis Missouri: Elsevier; 2016. p.1-257.

14. Valdez R, Guzman-Aranda JC, Abarca FJ, Tarango-Arambula LA, Sanchez FC. Wildlife conservation and management in Mexico. Wildl Soc Bull. 2006;34(2):270-82.
15. Wilson WC, Stallknecht DE, Mecham JO. Field-deployable real-time polymerase chain reaction detection of bluetongue and epizootic haemorrhagic disease viral ribonucleic acid. Vet Ital. 2015;40(4):587-93.